

## Case Report

# Immediate endovascular stent-graft repair of an acute traumatic rupture of the thoracic aorta

## Case report and subject review

IAN C. DUNCAN, F.F.RAD.(D.) (S.A.)  
 NEIL C. WRIGHT, F.C.S. (S.A.)  
 LESLIE M. FINGLESON, F.C.S. (S.A.)  
 JAN I. C. COETZEE, F.C.S. (S.A.)

Sunninghill Hospital, Sandton, Gauteng

### Summary

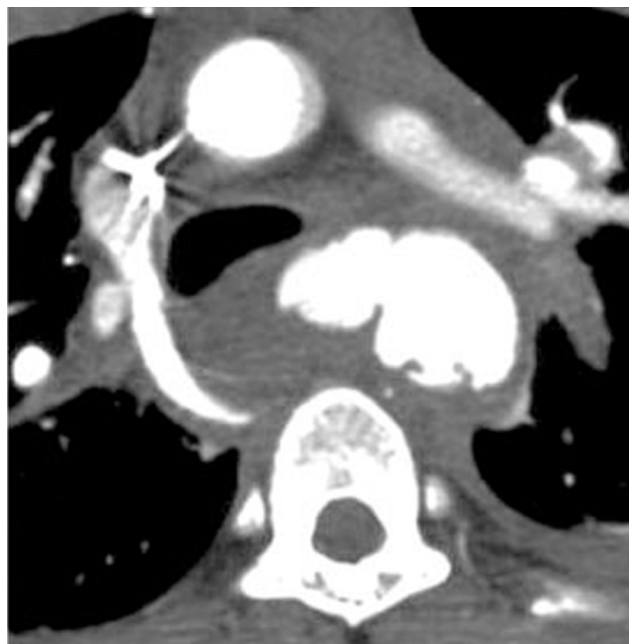
We describe a case of emergency endovascular stent-graft placement for acute traumatic rupture of the thoracic aorta in a patient with an associated unstable type II odontoid fracture. The stent-graft placement procedure was performed within 4 hours of admission under sedation and local anaesthesia while the neck remained externally splinted. After exclusion of the rupture the patient could then undergo treatment of the associated cervical fracture and other injuries.

Acute rupture of the thoracic aorta after blunt injury carries a high initial mortality: up to 90% of patients die at the scene of the accident or before they reach the hospital.<sup>1-4</sup> Traditional protocols have advocated emergency surgery for survivors reaching hospital, but this is accompanied by high operative mortality rates. The advent of endovascular techniques makes repair of a ruptured thoracic aorta by stent-graft implantation a viable alternative to surgery.

### Case report

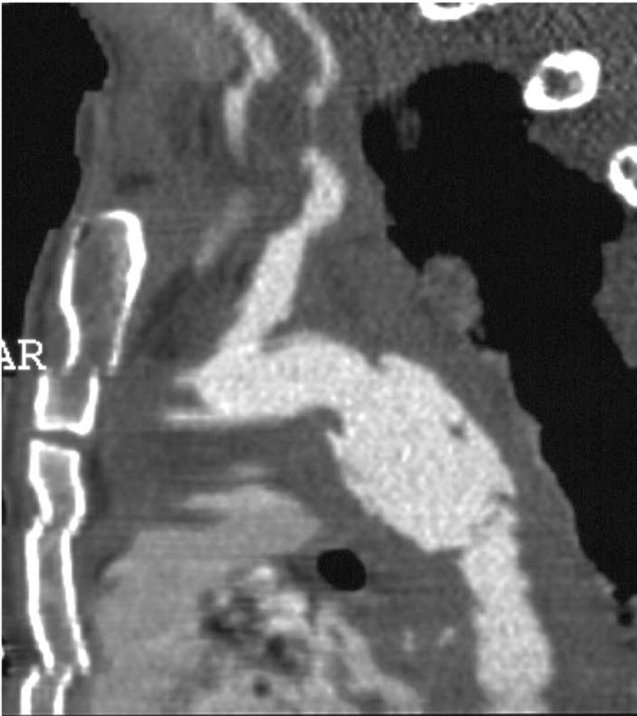
A 26-year-old victim of a motor vehicle accident was admitted to Sunninghill Hospital with blunt injuries to the face and anterior chest. He was fully conscious with no neurological deficits and he was haemodynamically stable. All limb pulses were present and equal. A supine chest radiograph showed a widened mediastinum and deviation of the trachea to the right. A lateral cervical radiograph showed a posteriorly displaced fracture of the odontoid process of C2.

On contrast-enhanced multislice computed tomography (CT) scan of the chest there was a focal transmural dissection of the proximal descending thoracic aorta 1.5 - 2 cm distal to the origin of the left subclavian artery, with a large associated mediastinal haematoma (Fig. 1A). Multiplanar reformatted images showed the longitudinal extent of involvement of the aorta, allowing accurate measurements of the normal adjacent aorta and length of the involved segment to be made (Fig. 1B).

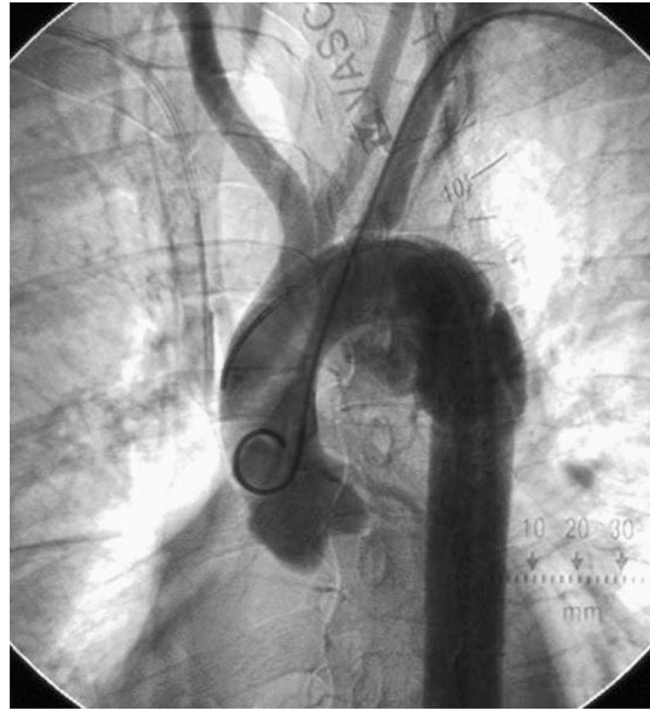

**Fig. 1A.** Axial contrast-enhanced helical CT scan through the aorta and mediastinum at the level of the aortic rupture showing a pseudo-aneurysm and mediastinal haematoma.

It was considered that a standard lateral thoracic surgical approach for emergency repair of the thoracic aorta involving lateral decubitus positioning on the theatre table would be dangerous in view of the cervical fracture. It was therefore decided to attempt immediate endovascular repair of the ruptured aorta. A suitable Talent stent-graft (Talent Medtronic, Santa Rosa, Calif., USA) was obtained, measuring 24 mm × 8 cm in size, but mounted on a short delivery device intended for abdominal deployment. The stent-graft was manually removed from its short delivery device and then custom-mounted onto a more suitable long thoracic delivery device in the interventional suite. The procedure



**Fig. 1B.** Oblique multiplanar reformatted image obtained from the axial raw scan data showing the longitudinal extent of the aortic wall damage.



**Fig. 2.** Digital unsubtracted thoracic aortogram, left anterior oblique projection, showing the position and extent of the rupture.

was performed under sedation and local anaesthesia. A 5F pigtail catheter was placed retrogradely via a low brachial access through the left subclavian artery into the ascending aorta. This served to allow continuous angiographic assessment of every step as well as marking the position of the left subclavian arterial origin during fluoroscopy.

Via left femoral arteriotomy a 5F Headhunter catheter and 0.035 inch angle-tipped hydrophilic guidewire were manipulated across the damaged aortic segment. A flush aortogram confirmed the position of the rupture (Fig. 2). A 0.035 inch 260 cm J-tipped Amplatz super-stiff guidewire was then placed with its tip doubled back in the ascending aorta above the aortic valve. Over this the stent-graft delivery device was manipulated into position just distal to the origin of the left subclavian artery covering the aortic defect. Heparin 5 000 U was given intravenously at this stage. Once the position had been confirmed angiographically, the stent-graft was deployed.

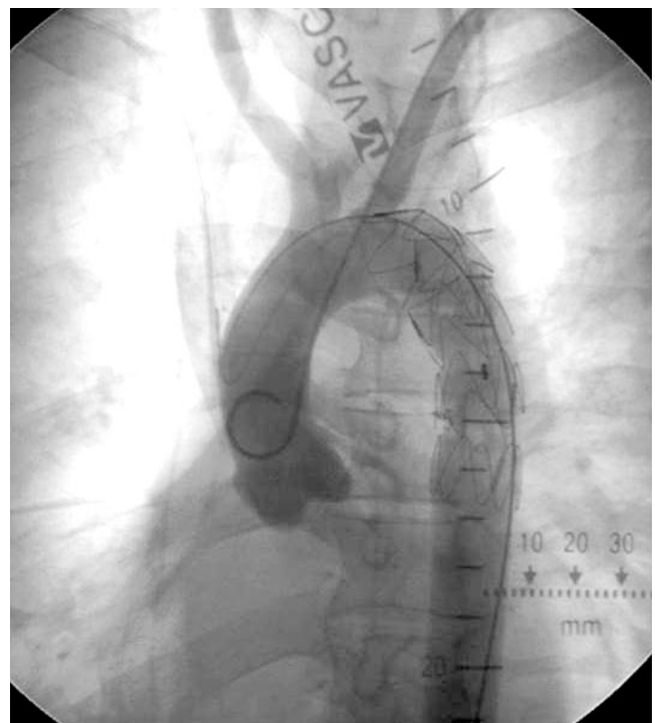
No induced hypotension was used during deployment as the systolic blood pressure was already low. No distal migration of the stent-graft was observed fluoroscopically during or after deployment.

Control arteriography confirmed coverage of the entire damaged aortic segment with good flow through the left subclavian artery. A small endoleak was noted initially with slow faint opacification of the medial false aneurysm. We were unable to establish whether this was due to leakage around the stent-graft or through the graft material itself. A balloon was inflated in the proximal and distal landing zones of the stent-graft to mould and seal its inlet and outlet. A second control arteriogram done several minutes later showed no further leakage through or around the stent-graft (Fig. 3).

The patient remained in hospital for 19 days during which operative fixation of the odontoid and facial fractures was performed. He remains clinically well 9 months after the initial trauma.

## Discussion

Aortic injury represents the second most common cause of death after blunt trauma.<sup>1</sup> In 1958 Parmley *et al.*<sup>2</sup> reported the autopsy findings of 296 patients who died after non-penetrating traumatic aortic rupture. They calculated that 85%



**Fig. 3.** Digital unsubtracted thoracic aortogram, same projection, after stent-graft placement. No endoleak is seen at this stage.

of victims died immediately as a result of the aortic rupture, and that of the remainder 30% died within 6 hours and 49% within 24 hours, with 90% having died by 4 months. More recent studies confirm these high initial mortality rates of 77 - 90%.<sup>1,3</sup> Many such injuries are related to motor vehicle accidents. Most occur in the isthmus region, where the mobile section of the thoracic aorta is tethered above by the fixed arch and by the insertion of the ligamentum arteriosus below.<sup>4</sup>

Largely on the basis of the Parmley report, standard teaching was that these injuries required emergency surgical repair. However, this has an extremely high peri-operative mortality rate of up to 45%,<sup>5-9</sup> and a paraplegia rate of 5 - 43%.<sup>3,7-10</sup>

Methods of repair include placement of an interposition graft or primary repair. Over one-third of blunt aortic injuries are accompanied by head injuries, pulmonary injuries and blunt abdominal injuries<sup>1</sup> that add to the morbidity and mortality. Worsening of these injuries can occur secondary to the thoracic repair. For instance, aortic cross-clamping may cause increased intracranial pressure and systemic heparinisation during bypass may aggravate haemorrhagic injuries.<sup>9</sup>

Two recently described innovative treatment strategies that have had considerable impact are the deliberate delay of surgical repair and endovascular repair. In patients who survive long enough to reach hospital, the integrity of the damaged aorta is preserved partly by the adventitia and partly by the peri-adventitial mediastinal structures and tissues. Pate *et al.*<sup>11</sup> showed that the risk of free rupture after admission to hospital is lower than the risk of emergency repair, especially in patients with serious associated injuries. No patient whose systolic arterial pressure was > 140 mmHg developed free rupture. A number of other studies have reported a reduction in mortality rates with initial medical therapy (blood pressure control and  $\beta$ -blockers), followed by delayed surgical repair after stabilisation of associated injuries.<sup>11-15</sup>

The second new strategy involves endovascular treatment. In 1997 Semba *et al.*<sup>16</sup> described the placement of stent-grafts in 11 patients with acute descending aortic rupture, 8 of which were due to ruptured aneurysms and 3 to trauma (2 penetrating and 1 blunt). Further case reports describing successful immediate endovascular repair (< 12 hours) for traumatic rupture were published by Dorweiler *et al.*,<sup>17</sup> Lobato *et al.*<sup>18</sup> and Bruninx *et al.*<sup>19</sup>

A number of reports describe the delayed treatment of traumatic rupture of the thoracic aorta by stent-grafting. Rosseau *et al.*<sup>20</sup> described 9 patients who underwent stent-grafting of the aortic isthmus in 5 subacute and 4 chronic traumatic aortic ruptures following motor vehicle accidents. The delay in treatment in the subacute group was between 1 and 8 months. Chronic rupture was seen in 4 patients, between 10 and 32 years after the initial accident. The indications for treatment were either aortic expansion or aortic diameter > 60 mm. No deaths, neurological complications or post-procedural infections were noted. Fattori *et al.*<sup>21</sup> reported on 19 patients with traumatic aortic injury; 11 cases were acute and 8 chronic (> 36 hours after admission). Of the 11 acute cases, 2 underwent immediate endovascular treatment and 9 were scheduled for delayed treatment because of the severity of associated injuries. None of these showed imaging features of impending free rupture. All were given antihypertensive therapy and controlled fluid replacement so as to maintain systolic blood pressure below 100 mmHg and a heart rate of less than 60/min. They remained in the intensive care unit for between 15 and 45 days before stent-graft placement was performed. There were no reported deaths, paraplegia or other major complications. All patients were reported well at follow-up between 1 and 56 months later.

Although to date the numbers of reported acute ruptures treated by endovascular means are small compared with larger surgical series, there is a trend suggesting a significantly lesser risk of mortality, neurological deficits or other major morbidity in patients treated in the acute phase with endovascular treatment than in those who undergo emergency surgery. A comparison between endovascular treatment and surgery in subacute and chronic ruptures is more difficult. The long-term outcome is unknown. Potential complications include endoleakage due to inadequate proximal or distal seal, stent migration, collateral flow through intercostal arteries or structural defects of the stent-graft itself. To date no local septic complications, neurological deficits or free ruptures have been reported.

There are a number of limitations to stent-graft use in these situations, mainly related to the anatomical characteristics of the aorta and the site of the rupture. The distance between the tear and the subclavian artery should be at least 5 mm to allow adequate proximal anchorage. Tactics to compensate for a short 'neck' include deliberate placement of the proximal covered part of the stent-graft across the ostium of the left subclavian artery, the creation of a small window in the covering of the stent-graft during manufacture, and the creation of a hole in the polyester covering after implantation.<sup>20</sup> If the left subclavian arterial ostium is covered, a carotid to subclavian bypass graft or transposition may be considered depending on the degree of flow reduction within the subclavian artery. Other anatomical problems include mural thrombus, calcifications or haemorrhage within the aortic wall at the neck site.

Temporary hypotension is generally induced during the deployment of the stent-graft to prevent distal migration (the 'windsock' effect) before full opening. This may not be appropriate in critically ill patients. Covered stents can only be placed in aortas with a diameter of < 40 mm.

Finally, the access anatomy is also critical as the delivery systems of current devices are large (18F - 24F), which can be problematic in young patients with healthy narrow femoral and iliac arteries prone to spasm, or in atherosclerotic and tortuous vessels in the elderly. In such cases iliac or even aortic access may be required.

One logistical problem that we encountered in this case is that often suitable-sized stent-graft devices are not immediately available for emergency implantation. We were fortunate in being able to find a stent-graft of suitable size at short notice, albeit on the incorrect length delivery device. However, we were able to transplant the stent-graft onto a second, longer delivery device and so successfully complete the procedure. There are significant cost implications involved in having a suitable range of devices available for thoracic or abdominal aortic emergencies, so this is not always feasible in many centres.

Clear advantages to endovascular treatment of acute aortic ruptures include the lack of necessity for cardiopulmonary bypass and systemic heparinisation. The reported neurological complication rates are lower than with surgical repair. There are to date no reported cases of paraplegia following emergency or elective stent-graft repair for traumatic thoracic aortic rupture. Mitchell *et al.* reported a paraplegia rate of 3.6% in 82 patients with descending thoracic aortic aneurysms treated by stent-graft placement at Stanford.<sup>22</sup>

In conclusion, endovascular stent-graft repair of traumatic descending thoracic aortic rupture is a feasible less invasive alternative technique to surgical repair. The timing of the endovascular repair remains debatable and the decision about this in each case should be made depending upon the condition of the patient and all associated co-morbidities.

## REFERENCES

- Smith RS, Chang FC. Traumatic rupture of the aorta: Still a lethal injury *Am J Surg* 1986; **152**: 660-663.
- Parmley LF, Mattingly TW, Manion WC, Jahnke EJ. Non-penetrating traumatic injury of the aorta. *Circulation* 1958; **17**: 1086-1101.
- Fabian TC, Richardson JD, Croce MA, Smith JS jun, Rodman G jun, Kearney PA. Prospective study of blunt aortic injury: Multicentre trial of the American Association for the Surgery of Trauma. *J Trauma* 1997; **42**: 374-380.
- Cohen AM, Grass JR. Traumatic aortic injuries: current concepts *Semin Ultrasound CT MR* 1993; **14**: 71-84.
- Cowley RA, Turney SZ, Hankins JR, Rodriguez A, Attar S, Shanker BS. Rupture of the thoracic aorta caused by blunt trauma: A fifteen-year experience. *J Thorac Cardiovasc Surg* 1990; **100**: 652-660.
- Sturm JT, Billiar TR, Dorsey JS, Luxemburg MG, Perry JP. Risk factors for survival following surgical treatment of traumatic aortic rupture. *Ann Thorac Surg* 1985; **39**: 418-421.
- Schmidt CA, Wood MN, Razzouk AJ, Killeen JD, Gan KA. Primary repair of traumatic aortic rupture: A preferred approach. *J Trauma* 1992; **32**: 588-592.
- Nocolosi AC, Almassi GH, Bousamra M, Haasler GB, Olinger GN. Mortality and neurologic morbidity after repair of traumatic aortic disruption. *Ann Thorac Surg* 1996; **61**: 875-878.
- Von Opell VO, Dunne TT, De Groot MK, Zilla P. Traumatic aortic rupture: Twenty-year meta-analysis of mortality and risk of paraplegia. *Ann Thorac Surg* 1994; **58**: 585-593.
- Hunt JP, Baker CC, Lentz CW, et al. Thoracic aortic injuries: Management and outcome of 144 patients. *J Trauma* 1996; **40**: 547-556.
- Pate JW, Fabian TC, Walker W. Traumatic rupture of the aortic isthmus: An emergency? *World J Surg* 1995; **19**: 119-126.
- Fabian TC, Davis KA, Gavant MI, et al. Prospective study of blunt aortic injury: Helical CT is diagnostic and antihypertensive therapy reduces rupture. *Ann Surg* 1998; **227**: 666-677.
- Maggisano R, Nathers A, Alexandrova NA, Cina C, Boulanger B, McKenzie R, Harrison W. Traumatic rupture of the thoracic aorta: Should one always operate immediately? *Ann Vasc Surg* 1995; **9**: 44-52.
- Galli R, Pacini D, Di Bartolomeo R, et al. Surgical indication and timing of repair of traumatic aortic ruptures of the thoracic aorta. *Ann Thorac Surg* 1998; **66**: 611-612.
- Wahl WL, Michaels AJ, Wang SC, Dries DJ, Taheri PA. Blunt thoracic aortic injury: Delayed or early repair? *J Trauma* 1999; **47**: 254-260.
- Semba CP, Kato N, Kee ST, et al. Acute rupture of the descending thoracic aorta: Repair with use of endovascular stent-grafts. *J Vasc Interv Radiol* 1997; **8**: 337-342.
- Dorweiler B, Dueber C, Neufang A, Schmeidt W, Pitton MB, Oelert H. Endovascular treatment of acute bleeding complications in traumatic aortic rupture and aortobronchial fistula. *Eur J Cardiothor Surg* 2001; **19**: 739-745.
- Lobato AC, Quick RC, Phillips B, et al. Immediate endovascular repair for descending thoracic aortic transection secondary to blunt trauma. *J Endovasc Ther* 2000; **7**: 16-20.
- Bruninx G, Wery P, Dubois E, et al. Emergency endovascular treatment of an acute traumatic rupture of the thoracic aorta complicated by a distal low-flow syndrome. *Cardiovasc Intervent Radiol* 1999; **22**: 515-518.
- Rosseau H, Soula P, Perreault P, et al. Delayed treatment of traumatic rupture of the thoracic aorta with endoluminal covered stent. *Circulation* 1999; **99**: 498-502.
- Fattori R, Nappoli G, Lovato L, et al. Indications for, timing of, and results of catheter-based treatment of traumatic injury to the aorta. *Am J Roentgenol* 2002; **179**: 603-609.
- Mitchell RS, Miller DC, Dake MD. Stent-graft repair of thoracic aortic aneurysms. *Semin Vasc Surg* 1997; **10**: 257-271.