

## Meningococcal septicaemia complications involving skin and underlying deeper tissues – management considerations and outcome

A. NUMANOGLU, F.C.S. (SURG.) (S.A.)

S. W. BICKLER, M.D., D.T.M.&H., F.A.C.S., F.A.A.P.

H. RODE, M.B. CH.B., M.MED. (SURG.), F.R.C.S. (EDIN.), F.C.S. (SURG.) (S.A.)

Department of Paediatric Surgery, Red Cross War Memorial Children's Hospital and University of Cape Town

A. T. BOSENBERG, M.B. CH.B., F.C.A. (S.A.)

Department of Anaesthesia, Red Cross War Memorial Children's Hospital and University of Cape Town

### Summary

**Objective.** To describe surgical experience with purpura fulminans related to meningococcaemia in a single institution, and to suggest a management protocol.

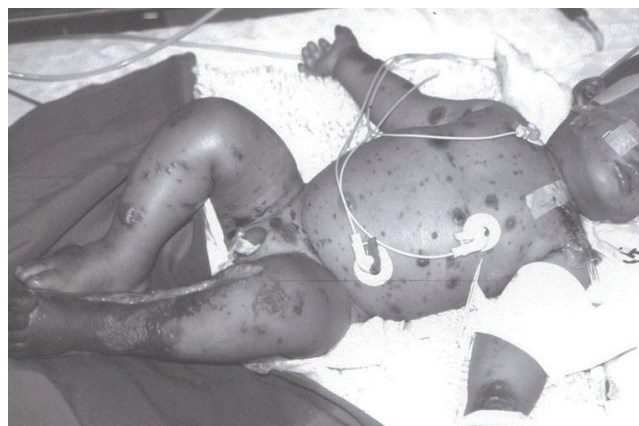**Methods.** A retrospective review was done of patients admitted to the intensive care unit at Red Cross War Memorial Children's Hospital in Cape Town with the clinical diagnosis of purpura fulminans.

**Results.** During a 28-year period (1977 - 2005) 112 children (average age 3.4 years) were treated for meningococcaemia with purpura fulminans. Overall mortality was 10.7%. Local treatment consisted of measures to improve circulation, infection control and healing of necrotic tissue. Demarcation of necrotic areas was evident at 5.5 days and the average area of skin necrosis was 14% total body surface area (range 2 - 85%). The lower limbs were predominantly affected. Purpura fulminans resolved in 35 children (31.2%) without skin necrosis. Skin grafting was required in 77 children (68.8%). Factors associated with a poor outcome for peripheral extremity salvage were progressive irreversible skin changes, early disappearance of distal pulses, tense cold swollen extremities and intense pain on passive movement of the affected extremity. Amputations were performed proximal to the area of necrosis, on average 27 days after injury.

**Conclusions.** Meningococcaemia is a disease with potentially devastating consequences. Early surgical consultation is essential. Skin- and soft-tissue-releasing incisions should be considered early to reduce the incidence of extremity necrosis. Small necrotic areas usually separate spontaneously with secondary healing or can be excised and sutured. Larger necrotic areas should be excised only after demarcation has been established, and can be covered with delayed skin grafting. Amputation should be conservative but may require revision.

Purpura fulminans is a rare catastrophic childhood illness occurring after an initial apparently benign infection, with rapid progression and development of a purpuric skin rash (Fig. 1), disseminated intravascular coagulation and frequently multiple organ failure. It can follow viral, rickettsial and bacterial infections, but typically is seen following *Neisseria meningitidis* septicaemia.<sup>1,2</sup> Children with meningococcaemia are at greatest risk of developing purpura fulminans. Surgical complications occur in up to 72% of cases, with a case fatality rate of 8 - 50%.<sup>1-4</sup>

Medical management includes systemic support, antibiotics, correction of plasma deficiencies, and when required, anticoagulant and thrombolytic therapy.<sup>5,6</sup> Surgical treatment depends on the nature and extent of tissue damage and may include decompression during the acute phase, and subsequently debridement of necrotic tissue, skin grafts, local microvascular flaps, and amputations. This study describes our experience with the management of children with purpura fulminans seen since 1977, with the goal of developing a management protocol that could perhaps limit the extent of tissue injury.



**Fig. 1.** Typical rash of meningococcal septicaemia with small to large or confluent purpuric lesions.

## Material and methods

A retrospective record review was done of patients admitted to the intensive care unit (ICU) at Red Cross Children's Hospital with a clinical diagnosis of purpura fulminans over a 28-year period (1977 - 2005). Purpura fulminans was defined as clinical evidence of extensive purpura, intravascular thrombosis and the presence of septic shock. All patients received standard ICU medical care, including factors to neutralise the effects of the endotoxin, heparin, tissue plasminogen activator (TPA), streptokinase and regional anaesthesia. Early releasing incisions or fasciotomies were done if limb viability was threatened. Timing and extent of surgical interventions were documented. Wound care was determined by local pathology and in principle was dealt with in a similar manner to full-thickness burns. Small necrotic areas were left to heal or were covered with non-adhesive dressings. Larger areas were covered with an antiseptic solution and extensive wounds were regarded as full-thickness necrosis requiring regular hydrotherapy, topical antiseptics, occlusive dressings, bacteriological surveillance and debridement when fully demarcated. Debridement and primary or delayed skin grafting were done only in stable patients with well-demarcated necrotic tissue. Levels of amputation were likewise defined using standard principles. A Hartman's colostomy was done in patients with perineal and upper-thigh wounds to prevent contamination of the wounds. All amputations were sent for histological examination.

Ethical approval for case review was obtained.

## Results

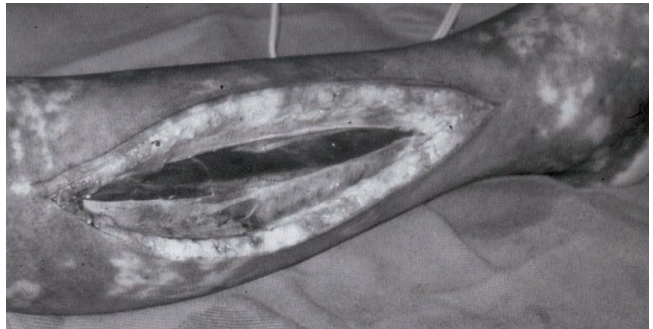
One hundred and twenty-two children with an admission or discharge diagnosis of purpura fulminans were identified. There were 74 females and 48 males, with a mean age of 3.4 years (range 3 months - 12 years). Eight of the children were less than 1 year of age. Ten children were excluded from the study, 2 with mild meningococcal disease not progressing to skin necrosis and 8 with non-diplococcus Gram-negative septicaemia and purpura fulminans. In the latter group, the causative organisms on blood culture were *Enterococcus*, *Pseudomonas*, *Haemophilus influenzae*, *Streptococcus* and *Staphylococcus* spp. All patients presented with the classic picture of Gram-negative septicaemia, viz. shock, intravascular coagulation and purpuric skin lesions. Seventeen children had negative blood cultures, 10 of whom had received antibiotics before admission. This group was included in the study because of the classic presentation. Meningococcal isolates were not typed but showed 100% sensitivity to penicillin, cefotaxime and chloramphenicol.

Skin lesions were present in all on admission, and once demarcated involved on average a total body surface area (TBSA) of 14% (range 2 - 85%). Skin necrosis (dark black areas) was observed within 24 hours of admission and was most prominent in areas of distal circulation. Sites of the major skin lesions were the lower limbs ( $N = 51$ ), arms ( $N = 32$ ), trunk ( $N = 20$ ), face and head ( $N = 12$ ), upper thighs ( $N = 8$ ) and gluteal area ( $N = 8$ ). Multiple areas were usually involved and demarcation of necrotic tissue was clinically completed at 5.5 days (range 3 - 19 days).

Purpura fulminans resolved without skin necrosis, or with spontaneous separation of the eschar followed by secondary healing of the wound in 35 children (31.2%). Skin grafting was required in 77 children (68.8%), primarily to the legs,

arms, trunk or face. Five primary skin grafts were performed, of which 4 were lost. This was because of the infected necrotic nature of the wounds which proved an unsuitable base for primary skin grafting. Quantitative tissue cultures of necrotic tissue always yielded a heavy growth of Gram-positive and negative organisms, especially *S. aureus*, beta-haemolytic streptococcus, *Pseudomonas*, *Proteus*, *Enterobacter*, *Klebsiella* and *Escherichia coli*. No fungal elements were identified. Seventy-two patients had wounds that were initially unsuitable for grafting due to infected, sloughy granulation tissue. Delayed skin grafting yielded excellent results. Vacuum-assisted closure was used in 6 children towards the end of the study to enhance the formation of healthy granulation tissue. During 2005 we started using continuous epidural infusions to provide analgesia, and sympathetic blockage to improve peripheral circulation.

There was an average of 3 surgical procedures per patient. The procedures included tissue debridement ( $N = 97$ ) fasciotomy ( $N = 5$ ) (Fig. 2), skin graft ( $N = 77$ ), amputation ( $N = 29$ ), colostomy ( $N = 10$ ), and musculocutaneous flap ( $N = 1$ ). Allografts were used in 4 children with extensive skin necrosis and unsuitable donor sites as temporary biological dressings. The colostomies were a temporary Hartman's-type colostomy to prevent ongoing faecal soiling of extensive gluteal and upper-thigh wounds. No colostomy complications were encountered.



**Fig. 2. Soft-tissue release including fasciotomy for peripheral limb ischaemia. The widely separated skin edges are indicative of the pressures in the subcutaneous and fascial compartments released by soft-tissue incisions.**

Amputations were performed proximal to the areas of necrosis after completion of demarcation, on average 27 days (range 19 - 50 days) post admission. Necrotic fingers were amputated at the mid-phalangeal joint level in 6 children (bilaterally in 3) and at metacarpal level in both hands of 1 child with bilateral feet amputations. Earlobes were involved in 2 cases, with excision of necrotic tissue and primary closure in 1 and subsequent reconstruction in another. The tip of the nose was amputated in 1 child. The toes were amputated at the metatarsophalangeal joints in 6 children and at the interphalangeal joint in 1 child. Five children required transmetatarsal foot amputations. Bilateral below-knee amputations were performed in 2 children, below-the-knee amputation in 1, a through-knee amputation in 1, and an emergency above-knee amputation as part of a life-saving procedure for peripheral gangrene with exposed bone, in another. In addition, 1 child had extensive areas of necrosis involving 85% of her TBSA, which included both legs up to the knees. Bilateral amputations were contemplated as both anterior and posterior muscle compartments were involved, but a technetium 99m limb perfusion scan showed evidence

of distal perfusion. After extensive debridement of necrotic tissue, sufficient functional muscle tissue was left to justify limb preservation. Subsequently, she regained limited plantar and dorsiflexion function of her feet and achieved reasonable locomotive activity. One adipose fascial dermal flap was used to cover exposed bone and deep structures of the plantar surface of the right foot. Major soft-tissue and muscle necrosis of the lower limbs developed in 4 children, exposing joint cavities leading to septic arthritis in 2, and the loss of most anterior and posterior compartment lower leg muscles in the other. None of these children required lower-leg amputations but all had limitations in locomotive function.

The majority of children received morphine by continuous infusion during the acute phase of the disease. Recently, continuous epidural infusions have been used, not only to provide analgesia but also for sympathetic blockade to improve peripheral circulation with limb-saving effects.

Histological evaluation of amputated specimens showed widespread coagulative necrosis and inflammation of skin, subcutaneous tissue and even muscle and bone in some cases. Twelve children (10.7%) died either during evolution of the disease from intractable shock, or as a result of irreversible septicaemia 36 - 120 hours after admission. Postmortems showed evidence of the Waterhouse-Friderichsen syndrome in 3 children.

## Discussion

To prevent the devastating consequences of meningococcaemia, the diagnosis should be made promptly, and immediate appropriate treatment should be instituted (Fig. 3).<sup>3,5</sup> *N. meningitidis* is very sensitive to penicillin, although more resistant strains are increasing. Of 183 strains, isolated from either cerebrospinal fluid or blood cultures during a recent survey in our laboratories, 100% of *N. meningitidis* were sensitive to cefotaxime, chloramphenicol and rifampicin, 98% were sensitive to penicillin and 37% to co-trimoxazole. Rifampicin is given as prophylaxis to all household contacts to eradicate bacteria from the nasopharynx.

Therapeutic options have been developed to ameliorate the pathogenesis and pathology of the purpura fulminans. From a practical point of view, apart from protein-C concentrates, and recombinant bacteriocidal/permeability-increasing protein (rBPI21) not used in our series, the following non-surgical interventions were utilised, to counteract the effects of the endotoxin.<sup>7</sup>

The use of heparin has been advocated for many years and a recent retrospective study found that heparin used within the first 72 hours reduced digit and extremity necrosis and the number of skin-graft procedures and amputations.<sup>8</sup> We used heparin early on in 7 children, but unfortunately 5 of them progressed to peripheral necrosis. In our experience therefore it had little benefit. rBPI21 should be administered at the time of initial diagnosis along with the appropriate antibiotics.<sup>7</sup> Tissue plasminogen activator (TPA) and streptokinase were used in 3 children in an attempt to improve small-vessel circulation.<sup>7</sup> Amputations were required in 2 but immediate and sustained improvement in perfusion of purpuric areas was observed in 1.

The use of regional anaesthesia, particularly central blockade (caudal, epidural) is controversial since both septicaemia and a coagulopathy with a low platelet count are considered contraindications. The risk of epidural haematoma or

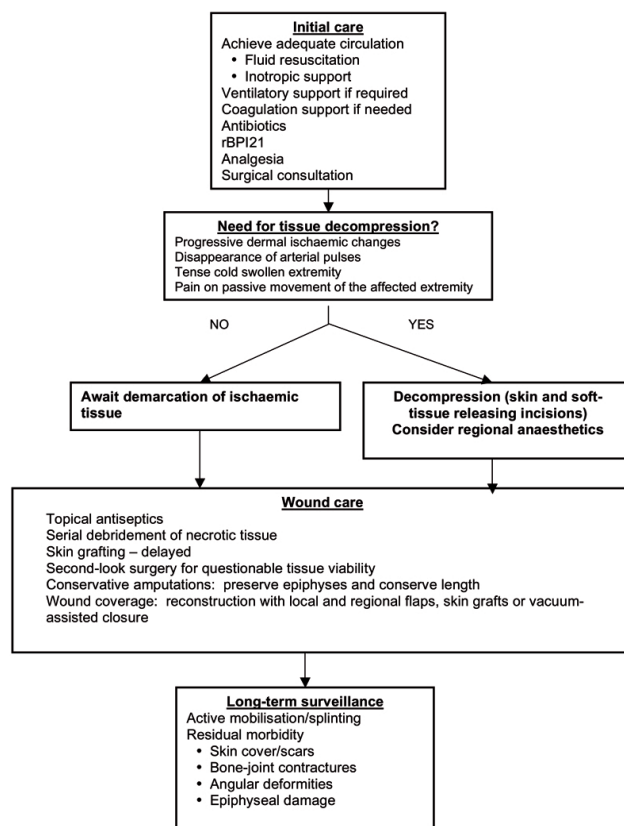


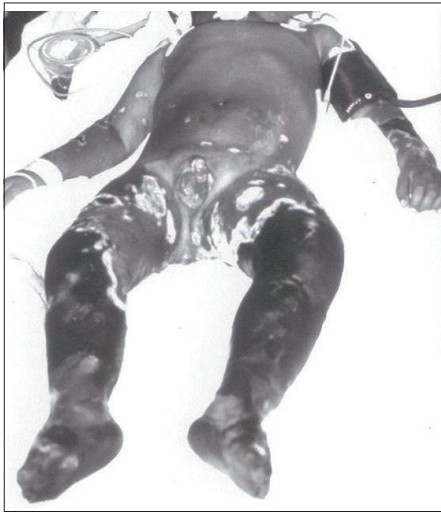Fig. 3. Treatment algorithm for purpura fulminans (adapted from Adams and Hobar<sup>3</sup>).

abscess formation is unknown in this patient population since only a few case reports have been published. The long-term benefit of limb salvage may outweigh the potential complications. Immediate benefits include prolonged analgesia, and haemodynamic stability which is usually not seen when systemic vasodilators or opiate analgesics are used in compromised patients. Furthermore, regional anaesthesia is not associated with respiratory depression.<sup>9,10</sup> Purpura fulminans was present in all 4 limbs of 1 patient. A continuous caudal block was placed to provide analgesia and to vasodilate the lower limbs. Bilateral axillary blocks were placed to achieve the same effect in the upper limbs. These were repeated on 2 occasions and the child suffered no limb loss.

In our experience, all children with progressive dermal ischaemic change, disappearance of arterial pulses and severe limb pain on passive extension, developed major digital or limb losses. Linear skin and subcutaneous decompression incisions, with or without fasciotomy done before irreversible ischaemic changes occur, may improve the chances of limb preservation, similar to escharotomies done for circumferential limb burns<sup>3-12</sup> (Fig. 2). A child with threatening peripheral ischaemia, and compartmental pressure measured at 68 cm H<sub>2</sub>O, was reduced to 25 cm H<sub>2</sub>O after 2 fasciotomy incisions with immediate and dramatic improvement in distal perfusion. Bleeding was easily controlled with bipolar cauterisation. Our previous reluctance to decompress ischaemic extremities with skin and subcutaneous releasing incisions was based on the presence of disseminated intravascular coagulopathy (DIC), bleeding and an evolving disease with an uncertain end point. However, in 1 small pilot series<sup>13</sup> early fasciotomies were instrumental in salvag-

ing severely compromised distal extremities. Continuous subcutaneous and compartment pressure monitoring and early soft-tissue releasing incisions are proposed to reduce the consequences of peripheral ischaemia. Concomitant sympathectomy to improve peripheral circulation has not been recommended, although temporary sympathectomy using regional analgesia may be of value.

Management of skin necrosis presents a difficult problem. It is important to allow the necrotic area to demarcate fully, which may take several weeks (Fig. 4). The lesion is usually a thick necrotic eschar, which provides favourable conditions for bacterial growth with rapid bacterial multiplication and invasive sepsis. Histological analysis and quantitative cultures revealed a polymicrobial infection with both Gram-positive and negative organisms. Small areas can be left to heal through a process of spontaneous separation, wound contraction and healing by secondary intention. This occurred in one-third of our children. Alternatively, the areas can be excised with primary closure if they are located in cosmetically and functionally important areas. If left to heal spontaneously, unsightly scars may develop.



**Fig. 4. Peripheral limb ischaemia with a clear demarcation line, with absent perfusion in the lower limbs. Emergency soft-tissue decompression was not done. Both lower limbs were amputated.**

The surgical management of larger areas is labour-intensive and children require a number of procedures to complete the healing process. Large necrotic areas require either single or serial debridement of necrotic tissue including non-viable skin, subcutaneous skin and even muscle. Necrotic tissue should only be excised in stable patients. Resection of questionable tissue should be deferred until clear demarcation is evident in order to minimise tissue loss. Histological assessment of tissue viability may be helpful, as clinical assessment cannot always determine the extent of subcutaneous muscle and bone necrosis with accuracy. Limb perfusion scans, magnetic resonance imaging (MRI) and magnetic resonance angiograms (MRAs) may be valuable adjuvants in delineating the level of arterial occlusion, soft-tissue and bone necrosis.<sup>14,17</sup> In 1 of our cases a technetium scan showing distal limb perfusion aided the decision to conserve the lower limb.

Although primary skin grafting has been advocated, it is seldom successful.<sup>3</sup> Delayed split skin grafting on a healthy bed of granulation tissue is preferred. Vacuum-assisted closure can promote a healthy bed of granulation tissue. Allografts can be used as temporary biological dressings to cover extensively excised wounds where donor sites are deficient or where the development of a vascularised bed for skin grafting is awaited. The use of cultured epithelial autografts has been reported, and although the 'take' rate is only in the order of 50%, their application can stimulate wound healing especially in children with massive skin loss.<sup>15</sup> We have not used local, random or pedicle fasciocutaneous or subcutaneous flaps to cover large defects or amputation stumps initially as the underlying vasculitis and wound infection precludes their use. The need for flaps to cover bone and deep muscular structures was required in only 1 of our children (0.9%). Skin and muscle loss can also expose joints, resulting in septic arthritis. Two of our children had knee joints exposed which required treatment with antibiotics, local debridement and skin grafts. Functional ability returned in these joints.

Of major concern are the progressive ischaemic changes to peripheral structures which may culminate in digital or extremity loss. In reported series, the amputation rate varies from 23% to 71%, with up to 38% of surviving children having amputations of 2 or more limbs. High-level quadruple limb amputations may be required in up to 23%.<sup>4,14</sup> The need for amputations must be evaluated with great circumspection. The basic principle is to preserve useful function as much as possible.<sup>16</sup> The most appropriate level of amputation is determined by functional and reconstructive considerations especially in growing children as residual limb lengthening may provide useful function at a later date.<sup>3</sup> This might require multiple skin grafts, the use of allografts or transposition flap coverage for wound closure. If the epiphysis has to be sacrificed, as much diaphyseal length as possible should be left. Histological evaluation of the skeletal element amputated showed the extent of tissue ischaemia, confirming that the field of pathology is not only confined to the skin and subcutaneous tissues; in addition focal vascular inflammation, acute periostitis and acute osteomyelitis may indicate a direct suppurative effect of the meningococcus.

In our experience, amputations should always be covered initially by local anterior and posterior muscular flaps, with either primary or secondary closure obtained using skin grafts. Most amputations involve the lower extremities and quadruple amputations are rare, with only 1 child in our series requiring both hand and feet amputations. Amputation levels frequently required revision, and stump problems such as unsatisfactory skin cover, epiphyseal damage with leg length discrepancy, angular deformities and poorly fitting prostheses may become evident during the rehabilitation phase. Long-term follow-up is essential, as scar revision and surgical repair of deformities such as the ones due to arrest of growth plate are frequently required.<sup>16,17</sup> These changes can occur early, or up to 10 years later.

In conclusion, purpura fulminans is a disease with devastating consequences. We advocate early surgical consultation. Skin and soft-tissue releasing incisions should be considered early on to reduce the incidence of extremity necrosis. Regional anaesthesia may be beneficial in this regard. Small necrotic areas usually separate spontaneously with secondary healing or can be excised and sutured. Larger necrotic areas

should be excised once demarcation has been established and skin grafting delayed. A-mputations should be conservative and may require subsequent revision. Growth disturbances in long bones are not uncommon and scar revision and surgical repair of deformities may become necessary, making ongoing surveillance essential.

## REFERENCES

- Olesch CA, Knight GJ. Invasive meningococcal infections in Western Australia. *J Paediatr Child Health* 1999; 35: 42-48.
- Warner PM, Kagan RJ, Yakuboff KP, et al. Current management of purpura fulminans: a multicenter study. *J Burn Care Rehabil* 2003; 24: 119-126.
- Adams WP, Hobar PC. Surgical treatment of meningococcal induced purpura fulminans. In: Herring JA, Birch JG, eds. *The Child with a Limb Deficiency*. Rosemont, Ill.: Academy of Orthopedic Surgeons, 1998: 447-454.
- Powars D, Larsen R, Johnson J, et al. Epidemic meningococemia and purpura fulminans with induced protein C deficiency. *Clin Infect Dis* 1993; 17: 254-260.
- Kennedy NJ, Duncan AW. Acute meningococcaemia: recent advances in management (with particular reference to children). *Anaesth Intensive Care* 1996; 24: 197-216.
- Wall RA. Meningococcal disease – some issues in treatment. *J Infect* 2001; 42: 87-99.
- Levin M, Quint PA, Goldstein B, et al. Recombinant bactericidal/permeability increasing protein (rBPI22) as adjunctive treatment for children with severe meningococcal sepsis: a randomised trial. *Lancet* 2000; 356: 961-967.
- Kuppermann N, Inkelis SH, Saladino R. The role of heparin in the prevention of extremity and digit necrosis in meningococcal purpura fulminans. *Pediatr Infect Dis J* 1994; 13: 867-873.
- Anderson CT, Berde CB, Sethna NF, et al. Meningococcal purpura fulminans: treatment of vascular insufficiency in a 2-yr-old child with lumbar epidural sympathetic blockade. *Anesthesiology* 1989; 71: 463-464.
- Tobias JD, Haun SE, Helfaer M, et al. Use of continuous caudal block to relieve lower extremity ischemia caused by vasculitis in a child with meningococemia. *J Pediatr* 1989; 115: 1019-1021.
- Fitton AR, Dickson WA, Shortland S, et al. Peripheral gangrene associated with fulminating meningococcal septicaemia. *J Hand Surg [Br]* 1997; 22: 408-410.
- Herrera R, Hobar PC, Ginsburg CM. Surgical interventions for the complications of meningococcal-induced purpura fulminans. *Pediatr Infect Dis J* 1994; 13: 734-737.
- Sacks L, Wolf A, Jenkins I, et al. Very early fasciotomies in children with meningococcal septicaemia, purpura fulminans and compartment syndrome, improves limb salvage and quality of life. Presented at the European Association of Plastic Surgeons, 11th Annual Meeting, Berlin, 1-3 June 2000.
- Harley OJ, Ahmed OA, Ng RL. Imaging to guide amputation of necrotic limbs in paediatric patients with meningococcal septicaemia. *Br J Plast Surg* 2004; 57: 174-175.
- Harris NJ, Gosh M. Skin and extremity loss in meningococcal septicaemia treated in a burn unit. *Burns* 1994; 20: 471-472.
- Wheeler JS, Anderson BJ, De Chalain TM. Surgical interventions in children with meningococcal purpura fulminans - a review of 117 procedures in 21 children. *J Pediatr Surg* 2003; 38: 597-603.
- Belthur MV, Bradish CF, Gibbons PJ, et al. Late orthopedic sequelae following meningococcal septicaemia. *J Bone Joint Surg Br* 2005; 87: 236-240.

## WITS 21ST BIENNIAL SYMPOSIUM

SANDTON CONVENTION  
CENTRE,

14 - 16 JUNE 2008

**THEME "PERIOPERATIVE CARE  
AND  
HIGH RISK SURGERY"**

MAIN OVERSEAS SPEAKERS:  
JOHN MARSHALL – TORONTO  
GEORGE VELMAHOS – HARVARD

AMANDA PYNE-JAMES  
RSVP EVENTS MANAGEMENT CC  
TELEPHONE: 011 463 4064  
TELEFAX: 011 463 1041  
MOBILE: 083 252 9801

## VASCULAR SOCIETY OF SOUTHERN AFRICA



VASSA

2008 CONGRESS

Organised by the University of the Free State

**CHAMPAGNE SPORTS RESORT  
DRAKENSBERG, KWAZULU NATAL**

Thursday 9 - Sunday 12 October 2008

### SCIENTIFIC PROGRAMME:

Renal replacement therapy access workshop, a full day endovascular session under the auspices of SAEWG, parallel sessions for vascular surgery and interventional radiology

### CONFIRMED INTERNATIONAL SPEAKERS:

Roy Greenberg – Cleveland, Ohio  
Tony Nicholson – Leeds, UK  
Sumaira MacDonald – England

### SOCIAL EVENTS:

Welcome Evening  
Braai at the pool overlooking the mountains  
Gala Dinner

Congress Secretariat:  
RSVP Events Management

Telephone: 011 463 4063 Email: [rsvp@yebco.co.za](mailto:rsvp@yebco.co.za)