

Long-term follow-up of a patient with hypercholesterolaemia treated by liver transplantation

V. O. L. KARUSSEIT, M.B. CH.B., M.F.G.P. (S.A.), M.MED. (SURG.), F.C.S. (S.A.)

C. J. MIENY, M.B. CH.B., CH.M., F.C.S. (S.A.), F.R.C.S. (ENG.), F.R.C.S. (EDIN.)

Department of Surgery, University of Pretoria and Pretoria Academic Hospital

Familial hypercholesterolaemia is a life-threatening inborn error of metabolism characterised by extremely high serum cholesterol levels. The disease manifests clinically as advanced atherosclerosis, cardiovascular disease and premature death. In 1973 Goldstein and Brown¹ described the abnormality causing the hypercholesterolaemia. They described mutations in a gene coding for the receptor responsible for transporting low-density lipoprotein (LDL) into cells. However, no specific treatment has been described and optimal treatment remains elusive. Management includes diet, cholesterol-lowering drugs and apheresis.² Surgical options that have been applied and abandoned are ileal bypass and porto-systemic shunting.^{3,4} Since the 1980s liver transplantation has been successfully applied to this condition. We describe the long-term follow-up of a patient treated successfully with liver transplantation.

Case report

A 13-year-old girl was referred by the endocrine and metabolic clinic to our transplantation unit for consideration for liver transplantation. She was known to suffer from homozygous familial hypercholesterolaemia (HFH). Genetic studies had revealed hetero-allelic mutations in exons 4 and 9 of the gene coding for the LDL receptor. For several years she had been followed up for atherosclerosis and multiple xanthelasmas. Several of the latter had been excised, specifically over the knees and elbows. Systolic bruits were audible over both carotid arteries and in the epigastrium, but these were asymptomatic. She had recently developed angina-like chest pain. Angiographical examination revealed stenoses of the carotid arteries and the coeliac trunk, but the coronary arteries were normal. Nevertheless the physicians treating her considered it prudent to refer her for liver transplantation. Conservative treatment with diet and lipid-lowering agents had been singularly ineffective. The serum cholesterol level had been consistently in the region of 20 mmol/l. Apheresis had not been considered appropriate by the doctors treating the patient.

Apart from the abovementioned abnormalities the patient was in good health and she was accepted onto the transplant programme. A cadaver liver was transplanted in 1991. One acute rejection episode was treated successfully with boluses of steroids and there were no other complications. She was maintained on ciclosporin, azathioprine and prednisone immunosuppression.

Serum lipid levels decreased dramatically after transplantation (Fig. 1). The total serum cholesterol level stabilised at about 7 mmol/l and the patient was started on simvastatin. This has maintained the cholesterol level at between 4 and 5 mmol/l ever since.

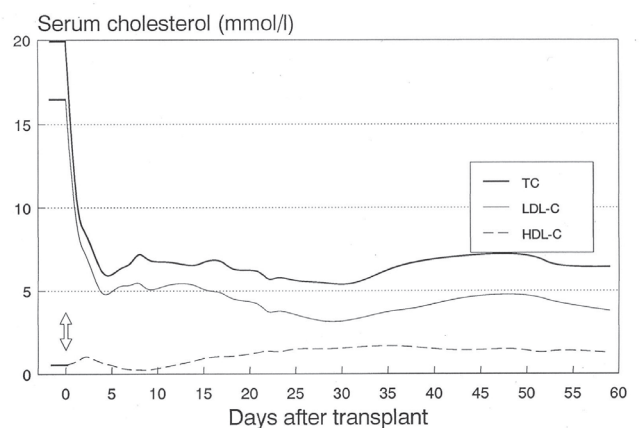


Fig. 1. Change in serum total cholesterol (TC), serum low-density lipoprotein cholesterol (LDL-C) and high-density lipoprotein cholesterol (HDL-C) in the first 2 months after transplantation.

The patient subsequently married a man with a family history of arterial disease. Advice to first have the husband's lipid profile determined and to undergo genetic counselling was not followed, and a child has subsequently been born of the marriage. The child is now 5 years old. It is clinically normal but a lipid profile has not been performed.

The patient is clinically well. The bruits over the carotid arteries are still present but asymptomatic. Liver functions are completely normal.

Discussion

HFH is a universally fatal condition if not treated successfully. Patients with severe receptor deficiency die within the first decade of life, or in the second decade in less severe cases.⁵ Death results from the complications of atherosclerosis. Our patient clearly manifested arterial disease, but complications were not yet evident. It was felt that it would be prudent to attempt to normalise the serum cholesterol levels before any serious sequelae developed. This recommendation was made by Starzl *et al.*⁶ after the first successful combined heart and

liver transplantation in a child with severe coronary artery disease.

The liver contains 50 - 75% of the body's LDL receptors. Liver transplantation provides these receptors and therefore greatly ameliorates the disease.⁷ As in our case, patients require statins to completely normalise serum cholesterol levels. The cases reported in the literature have been cadaveric liver transplantations, but a living related transplant has recently been reported.⁷ Domino transplantation has also been reported.⁸

Apheresis profoundly lowers serum cholesterol levels in hypercholesterolaemia. Recent reviews^{6,9} have recommended apheresis as the treatment of choice for HFH and have stated that apheresis has superseded surgical approaches such as liver transplantation. However, liver transplantation has been successfully applied in many cases and has also been proposed as the treatment of choice.⁷ Both forms of treatment have their advantages and disadvantages. Apheresis is a difficult and hazardous treatment modality and is socially disruptive because of the need for regular long treatment sessions. It also requires permanent vascular access. On the other hand, liver transplantation is a major surgical undertaking with definite mortality and morbidity and exposes the patient to the hazards of lifelong immunosuppression.

The decision regarding treatment modality for HFH should be a consultative one involving the metabolic specialist, the transplant unit, the patient and the family. The precise genetic defect and the state of the patient's cardiovascular system need to be considered. The patient and family then need to make a fully informed decision. Obviously no randomised comparison between treatment modalities has been performed because of the rarity of the condition. It is difficult to glean long-term survival data for the various treatments of HFH from the literature as reports consist of early reports, individual cases and small series.¹⁰⁻¹²

We present a 15-year follow-up of a case of highly successful liver transplantation for HFH. The initial transplant was

uncomplicated and the subsequent course successful in curing the disease. Part of the success of this case is due to the timing of transplantation which was performed before serious sequelae of atherosclerosis had developed.

Despite apheresis being widely and successfully applied in the treatment of familial hypercholesterolaemia, it is our opinion that liver transplantation remains a therapeutic option that should be considered in the management of this devastating disease.

REFERENCES

1. Goldstein JL, Brown MS. Familial hypercholesterolemia: identification of a defect in the regulation of 3-hydroxy-3-methylglutaryl coenzyme A reductase activity associated with overproduction of cholesterol. *Proc Natl Acad Sci USA* 1973; 70: 2804-2808.
2. Kane JP, Malloy MJ. Treatment of hypercholesterolemia (Review). *Med Clin North Am* 1982; 66: 537-550.
3. Ohri SK, Keane PF, Swift I, Sackier JM, Williamson RC, Thompson GR. Reappraisal of partial ileal bypass for the treatment of familial hypercholesterolemia. *Am J Gastroenterol* 1989; 84: 740-743.
4. Forman MB, Baker SG, Miemy CJ, et al. Treatments of homozygous familial hypercholesterolaemia with portocaval shunt. *Atherosclerosis* 1982; 41: 349-361.
5. Naoumova RP, Thompson GR, Sontar AK. Current management of severe homozygous hypercholesterolaemias. *Curr Opin Lipidol* 2004; 15: 413-422.
6. Starzl TE, Bilheimer DW, Bahnson HT, et al. Heart-liver transplantation in a patient with familial hypercholesterolaemia. *Lancet* 1984; 1: 1382-1383.
7. Khalifeh M, Faraj W, Heaton M, Rela M, Sharara AI. Successful living related liver transplantation for familial hypercholesterolemia in the Middle East. *Transpl Int* 2005; 17: 735-739.
8. Popescu I, Simonescu M, Tulbure D, et al. Homozygous familial hypercholesterolemia: specific indication for domino liver transplantation. *Transplantation* 2003; 76: 1345-1350.
9. Lees RS, Cashin-Hemphill L, Lees AM. Non-pharmacological lowering of low-density lipoprotein by apheresis and surgical techniques (Review). *Curr Opin Lipidol* 1999; 10: 575-579.
10. Shrotri M, Fernando BS, Sidhindran S, et al. Long-term outcome of liver transplantation for familial hypercholesterolemia. *Transplant Proc* 2003; 35: 381-382.
11. Castilla-Cobezas JA, Lopez-Gillero P, Jimenez J, et al. Role of orthotopic liver transplantation in the treatment of homozygous familial hypercholesterolemia. *Rev Esp Enferm Dig* 2000; 92: 601-608.
12. Revel SP, Noble-Jamieson G, Johnston P, Rasmussen A, Jamieson N, Barnes ND. Liver transplantation for homozygous familial hypercholesterolaemia. *Arch Dis Child* 1995; 73: 456-458.

Insall & Scott's Surgery of the Knee e-dition, 4th edition

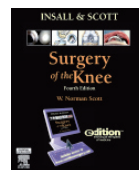
Text with Continually Updated Online
Reference, 2-Volume Set

To Order Contact: brents@hmpg.co.za /
086 695 0461

By **W. Norman Scott**

ISBN 0443069611 · Book/Electronic Media

Churchill Livingstone · Published January 2006



Built on a solid foundation of basic anatomy, pathology, and diagnostic techniques, this best-selling reference offers comprehensive coverage of value to anyone involved in the diagnosis and treatment of knee disorders.

Now thoroughly updated and available as a continuously updated multimedia e-dition, this definitive work in knee surgery is even better than ever! By pairing the tradition of print with the advances of technology (a state-of-the-art website featuring the entire book online with continuous updates) you will stay on the cutting edge with regular updates that provide access to the most current and most critical literature reviews in the field, meeting summaries of major developments in sports knee and adult reconstruction, periodic technique updates presented in streaming video, and more.