

# Pancreatic pseudocysts

C. APOSTOLOU, M.B. CH.B., CERT. GASTROENTEROLOGY (S.A.), F.C.S. (S.A.)

J. E. J. KRIGE, M.B. CH.B., F.A.C.S., F.R.C.S. (EDIN.), F.C.S. (S.A.)

P. C. BORNMAN, M.B. CH.B., M.MED., F.R.C.S. (EDIN.), F.R.C.S. (GLASG.), F.C.S. (S.A.)

Department of Surgery, University of Cape Town, and Surgical Gastroenterology Unit, Groote Schuur Hospital, Cape Town

## Summary

Improvements in imaging studies and a better understanding of the natural history of pancreatic fluid collections (PFCs) have allowed the different types to be clarified. Stratification of PFCs into subgroups should help in selecting from the increasing current available treatment options, which include percutaneous, endoscopic and surgical drainage. Percutaneous catheter drainage is safe and effective and should be the treatment of choice in poor-risk patients, and for infected pseudocysts related to acute pancreatitis. Endoscopic drainage should be the first management option in suitable pseudocysts related to chronic pancreatitis, if the necessary expertise is available. The high success rate and current low morbidity of elective open surgery mean that it is still the standard of management in this disease.

Laparoscopic approaches are gaining favour, predominantly in drainage of collections in the lesser sac, and long-term data are awaited. The precise application of this modality will need to be critically compared with the low morbidity of mini-laparotomy, which is the current standard after non-operative treatment fails in these patients.

It is essential to clearly stratify the different types of pancreatic pseudocysts, in particular with relation to acute or chronic pancreatitis, and perform a valid comparison of the different treatment modalities within groups. In this capacity a precise and transparent classification may provide valuable answers, in particular relating to optimal management according to pseudocyst type.

Pancreatic fluid collections (PFCs) comprise a variable and heterogeneous group of pancreatic-derived exudates, commonly complicating pancreatitis. Attempts have been made to clarify the different types of fluid collections, in particular with reference to the associated type of pancreatitis.<sup>1-5</sup> Associated pancreatic ductal abnormalities in chronic pancreatitis may also contribute to the development of these collections and determine the outcome of treatment. Over the last decade, advances in pancreatic endotherapy have resulted in an increased utilisation of non-operative techniques in the management of the different types of PFCs. The perceived lower morbidity associated with non-operative interventions has challenged the role of open surgery in the treatment of this common complication of pancreatitis.

The variable morphology of PFCs has bedevilled attempts

at formulating a classification that can be used to dictate treatment strategy and the validation thereof. A practical classification will allow appropriate stratification of these variable groups of PFCs, and facilitate critical audit and comparison of the different treatment modalities.

## Aetiology

Pseudocyst formation is directly related to pancreatitis. Alcohol-related pancreatitis is the major cause in most series, accounting for 59 - 78% of pseudocysts.<sup>4</sup> Variations in alcohol consumption of different population groups along with varying proportions of acute and chronic pancreatitis affect the prevalence of pseudocysts secondary to alcohol (Table I). Alcohol abuse is the principal cause of pseudocysts related to chronic pancreatitis, whereas pseudocysts may complicate the clinical picture of any cause of acute pancreatitis, including pancreatic cancer and endoscopic retrograde cholangiopancreatography (ERCP). Pseudocysts may develop after surgery to neighbouring organs through inadvertent pancreatic injury.

Pancreatic trauma is a major cause of pseudocysts in certain series<sup>5</sup> and in the paediatric population. Pseudocysts in children<sup>11,12</sup> are well-recognised complications of acute pancreatitis and pancreatic trauma. The classic bicycle handlebar injury causes compression of the pancreas onto the vertebral column with secondary pancreatic duct disruption, which may be complicated by pseudocyst formation.

## Incidence

The documented incidence of pseudocysts following acute pancreatitis has increased with the availability of ultrasound and computed tomography (CT). Adherence to current definitions<sup>1</sup> is important for valid interpretation and comparison, as the majority of pancreatic fluid collections in acute pancreatitis will regress spontaneously<sup>2,13</sup> and do not progress to pseudocyst formation. The incidence of pseudocyst formation following acute pancreatitis ranges from 55% to 12% in different series.<sup>14-17</sup> One interpretation for the wide range is that in patients with acute-on-chronic pancreatitis, the morphological changes of chronic pancreatitis may be missed,<sup>3</sup> particularly in uncomplicated cases where minimal testing is done, while in chronic pancreatitis, pseudocysts may be incorrectly labelled as a complication of acute pancreatitis. The incidence of pseudocysts in chronic pancreatitis may be higher, with some series reporting 20 - 40% occurrence.<sup>3,18,19</sup> The risk in the individual patient may be increased over their lifetime owing to the unremitting nature of chronic pancreatitis.

TABLE I. CONTRIBUTING CAUSES OF PANCREATIC PSEUDOCYSTS

Author (year) (No. of patients)	Country	Pseudocyst type	Alcohol	Biliary	Trauma	Other	Idiopathic
D'Egidio & Schein <sup>5</sup> (1991) (N = 83)	South Africa	Acute & chronic	70%	-	22%	-	8%
Walt <i>et al.</i> <sup>6</sup> (1990) (N = 357)	USA	Acute & chronic	70%	8%	6.3%	-	16%
O'Malley <i>et al.</i> <sup>7</sup> (1985) (N = 69)	USA	Acute & chronic	78%	7%	3%	6%	6%
Kolars <i>et al.</i> <sup>8</sup> (1989) (N = 51)	USA	Acute & chronic	73%	6%	3%	4%	14%
Bouliere & Sarles <sup>9</sup> (1989) (N = 357)	France	Acute & chronic	70%	13%	3%	6%	8%
Usatoff <i>et al.</i> <sup>10</sup> (2002) (N = 112)	UK	Chronic	71%	4%	-	5%	20%

## Pathogenesis

Two distinct groups of pseudocysts are evident when considering pathogenesis: pseudocysts related to acute pancreatitis and those related to chronic pancreatitis (intra- and extra-pancreatic collections).

### Pseudocysts following acute pancreatitis (post-necrotic)

Post-necrotic collections follow an attack of necrotising pancreatitis, with peripancreatic necrosis in the lesser sac which may extend into the retroperitoneum and bowel mesentery.<sup>20</sup> The evoked inflammatory response causes the formation of a distinct cyst wall composed of well-vascularised granulation tissue, which organises with more connective tissue and fibrosis. The pseudocyst cavity may contain enzymatic fluid and necrotic debris.<sup>21</sup>

Pseudocyst communication with the pancreatic duct in these post-acute collections is variable. Amylase levels in aspirated samples of pseudocyst fluid often far exceed serum levels and prolonged periods of drainage or pancreatic fistula formation may be expected following percutaneous intervention.<sup>4</sup> Communication may or may not persist because the progressive inflammatory reaction that parallels cyst formation may occlude the fistula.<sup>21</sup> Different rates of pseudocyst-duct communication are reported in the literature, ranging from very low (< 5%)<sup>5,22</sup> up to 60%.<sup>23</sup>

### Pseudocysts related to chronic pancreatitis

#### Extrapancreatic

These pseudocysts may develop as a consequence of an acute flare-up or exacerbation of underlying chronic pancreatitis, with or without an associated focal area of pancreatic necrosis. These collections are often confined to the peripancreatic space, but may rupture into the lesser sac and then into the peritoneal cavity resulting in pancreatic ascites.<sup>1,20</sup>

#### Intrapancreatic

In this group a second mechanism has been proposed: when a branch of the pancreatic duct is obstructed by fibrous scarring, protein plug, or stone, the ongoing pancreatic secretion upstream of the obstruction leads to a sacular dilation of the duct, filled with pancreatic juice. Such a cyst is truly a retention cyst.<sup>5,13</sup> Microcysts formed can eventually coalesce and lose their epithelial lining as they enlarge. In chronic

pancreatitis, pseudocysts may be seen in those patients with minimal fibrosis as well as in those with advanced fibrosis and calculi.<sup>24</sup> These cysts are commonly located in the head of the gland. Studies<sup>10,25</sup> have demonstrated a high cyst duct communication (up to 60%) in this group of patients, particularly in the setting of a dilated (> 7 mm) main pancreatic duct.<sup>26</sup>

### Traumatic pseudocysts

Pseudocysts following pancreatic trauma are usually the result of injury to the pancreatic duct or its major branches, applicable to both penetrating and blunt pancreatic trauma. The majority of pseudocysts in children are traumatic,<sup>27</sup> whereas in most adult series<sup>6-9</sup> the incidence ranges from 3% to 6%. In countries with a higher trauma prevalence, such as South Africa, the rate increases to 10 - 22%.<sup>5,28</sup>

### Clinical features and diagnosis

Patients with pseudocysts related to acute pancreatitis usually present with persistent pain, with or without upper gastrointestinal symptoms (i.e. anorexia, nausea and vomiting). Some patients may only present later, after the acute attack of pancreatitis has subsided, mimicking a recurrent attack of pancreatitis. A smooth mass may be palpated in the epigastrium or the left upper quadrant, depending on pseudocyst size and patient body habitus. Features of gastric outlet and/or biliary obstruction may be present. Compression of the mediastinum has been reported when pancreatic fluid extends into the mediastinum.<sup>29</sup> Patients with complicated cysts manifest features of sepsis, with a pyrexia and an elevated white cell count, or hypovolaemic shock in rare cases with significant bleeding into the pseudocyst.

In chronic pancreatitis the presentation may be insidious, especially when the patient has persistent opioid-dependent pain. Features include persistent pain after an acute exacerbation, gastrointestinal symptoms and jaundice.<sup>30</sup> A persistently elevated serum amylase may occur in up to three-quarters of patients,<sup>4</sup> but may be normal with impaired exocrine function in chronic pancreatitis. Ultrasound and CT scanning are commonly used to detect these collections.

In view of potentially significant complications, ERCP is not routinely used as a diagnostic procedure,<sup>31</sup> except as part of the work-up to exclude a cystic neoplasm of the pancreas.<sup>32-34</sup> In future ERCP and/or MRCP may influence surgical management via demonstrating the underlying pancreatic duct abnormality.<sup>35,36</sup>

## Natural history

Increased availability and application of accurate imaging by CT should improve our understanding of the natural history of PFCs. While there is general consensus that there is a difference in the resolution rate between PFCs following acute pancreatitis and those complicating chronic pancreatitis,<sup>3</sup> data are variable mainly because terminology and classifications differ in published series.<sup>37</sup>

Reported spontaneous resolution in PFCs related to acute pancreatitis varies from 20% to 65% of patients.<sup>38-40</sup> Series that have not adhered to the Atlanta criteria have reported higher resolution rates, which may reflect the inclusion of predominantly post-acute fluid collections. There is no convincing evidence to indicate that resolution rates differ between pseudocysts related to the two major causes of acute pancreatitis (alcohol v. biliary).<sup>4,41,42</sup>

Earlier studies<sup>38,43</sup> reported a low possibility of spontaneous resolution in pseudocysts that persist beyond 6 weeks after an attack of acute pancreatitis. This finding has been challenged in more recent studies,<sup>40-42</sup> which have demonstrated pseudocyst resolution well beyond this timeline. Most studies<sup>38,39,44,45</sup> on the natural history of pseudocysts in chronic pancreatitis show a resolution rate of less than 10%. The diameter of 6 cm had previously been regarded as the upper limit beyond which resolution would not occur<sup>42,46</sup> but this has subsequently been shown not to be the case.<sup>47</sup> The great majority of pseudocysts less than 4 cm in diameter will resolve spontaneously.<sup>44,46</sup>

## Complications

In the 1979 study by Bradley *et al.*,<sup>48</sup> direct correlation of complications to the age of the PFC presence (with morbidity rates of 76% after 13 weeks) and 12% related mortality was observed. This prompted the recommendation that 'delay is at best fruitless and at worst hazardous'. Subsequent studies<sup>40-42</sup> of expectant pseudocyst management have demonstrated much lower complication rates, between 3% and 23%, and mortality below 1%. The obvious disparity can partly be attributed to the fact that the patients in the later studies selected for conservative management were asymptomatic, whereas the cohort in Bradley's series included patients with symptomatic PFCs, the majority of which were a consequence of acute pancreatitis.

## Classification

Terminology plays an integral part in the understanding and management of pancreatic pseudocysts and PFCs. Although the Atlanta symposium consensus<sup>1</sup> has provided clear descriptions of the various PFCs and their natural history, its application in assessment of treatment strategy and outcome has not as yet been clearly determined.

A *pseudocyst* is defined as a collection of pancreatic juice enclosed by a wall of fibrous or granulation tissue, which arises as a consequence of acute pancreatitis, pancreatic trauma, or chronic pancreatitis. Formation usually requires 4 or more weeks from the occurrence of acute pancreatitis,<sup>2</sup> or the lack of an antecedent acute episode when arising in the setting of chronic pancreatitis. An *acute fluid collection* is distinguished by occurring early in the course of acute pancreatitis, located adjacent to the pancreas, without having a wall of granulation or fibrous tissue. The term *pancreatic abscess* describes a circumscribed intra-abdominal collection of pus in proximity to the pancreas, containing little or no pancreatic necrosis, which arises as a consequence of acute pancreatitis or pancreatic trauma. Bacteria may be present in a pseudocyst, often representing contamination and thus of

little clinical significance.<sup>1</sup> When pus is present, the lesion is correctly termed a pancreatic abscess.

The current pseudocyst classifications are based on the preceding or concurrent type of pancreatitis,<sup>1</sup> and the terms acute and chronic in this regard do not describe the known duration of the pseudocyst, but the underlying pancreatitis. Multiple classification systems have been proposed, based on pathogenesis,<sup>6</sup> morphology, anatomical features or a combination thereof.<sup>5,20,49,50</sup>

An early proposed classification<sup>49,50</sup> of pancreatic pseudocysts depended on the association with acute or chronic pancreatitis. Acute pancreatitis pseudocysts were called necrotic cysts, as they resulted from pancreatic necrosis and extravasation of pancreatic secretions. The term retention cyst was used in the setting of intra-pancreatic pseudocysts in chronic pancreatitis, as these were pathologically found to be true cysts caused by dilatation. Subsequent rupture into the peripancreatic tissues gives rise to extrapancreatic pseudocysts in chronic pancreatitis and not the sequelae of pancreatic necrosis.

Subsequent classifications by D'Egido and Schein<sup>5</sup> and Bornman *et al.*<sup>20</sup> identified three distinct types of pseudocysts: (i) 'post necrotic' or acute cysts that occur following acute pancreatitis, with normal pancreatic duct anatomy and without pancreatic duct communication; (ii) pseudocysts that follow an episode of acute-on-chronic pancreatitis (also post-necrotic), where the pancreatic duct is diseased but not strictured, and there is a significant incidence of duct-pseudocyst communication; and (iii) intrapancreatic 'retention'-type pseudocysts, which occur with chronic pancreatitis and are uniformly associated with duct stricture and pseudocyst-duct communication. In these classifications, distinction between acute-on-chronic and chronic-type pseudocysts can be subtle, usually requiring pancreatic duct delineation. Ultimately surgery may be required to show the presence of necrotic debris, indicating a recent flare-up of acute-on-chronic pancreatitis that may have been missed clinically. Examples of the different pseudocyst types are demonstrated in Fig. 1.

A classification system based solely on pancreatic duct anatomy has been proposed by Nealon and Walser,<sup>51</sup> on the postulate that the main pancreatic duct determines the type and course of the pseudocysts. It has been suggested that the definition of categories seen in ductal abnormalities may direct the choice of treatment modality. However, since duct morphology and duct communication are difficult to demonstrate by imaging modalities, the value of incorporating this in formulating a classification is limited.

## Treatment

### Timing of intervention

Considering the vast literature on the natural history and complications of pseudocysts, it is reasonable to adopt an initial conservative approach in asymptomatic patients, on the basis that an appreciable proportion of pseudocysts will resolve spontaneously,<sup>38-42</sup> particularly in the post-acute group. A diameter of 6 cm is no longer the threshold for intervention, with resolution documented in pseudocysts larger than this size.<sup>47</sup> Logic dictates that the larger the pseudocyst and the longer the duration, the less likely that spontaneous resolution will occur and that the risk for complications is increased. The same may be said in underlying chronic pancreatitis<sup>39</sup> and pseudocysts with a thicker wall or known communication with the pancreatic duct. Provided that close clinical and radiological follow-up is undertaken, action can be taken when the pseudocyst increases in size or becomes symptomatic, or complications are suspected.

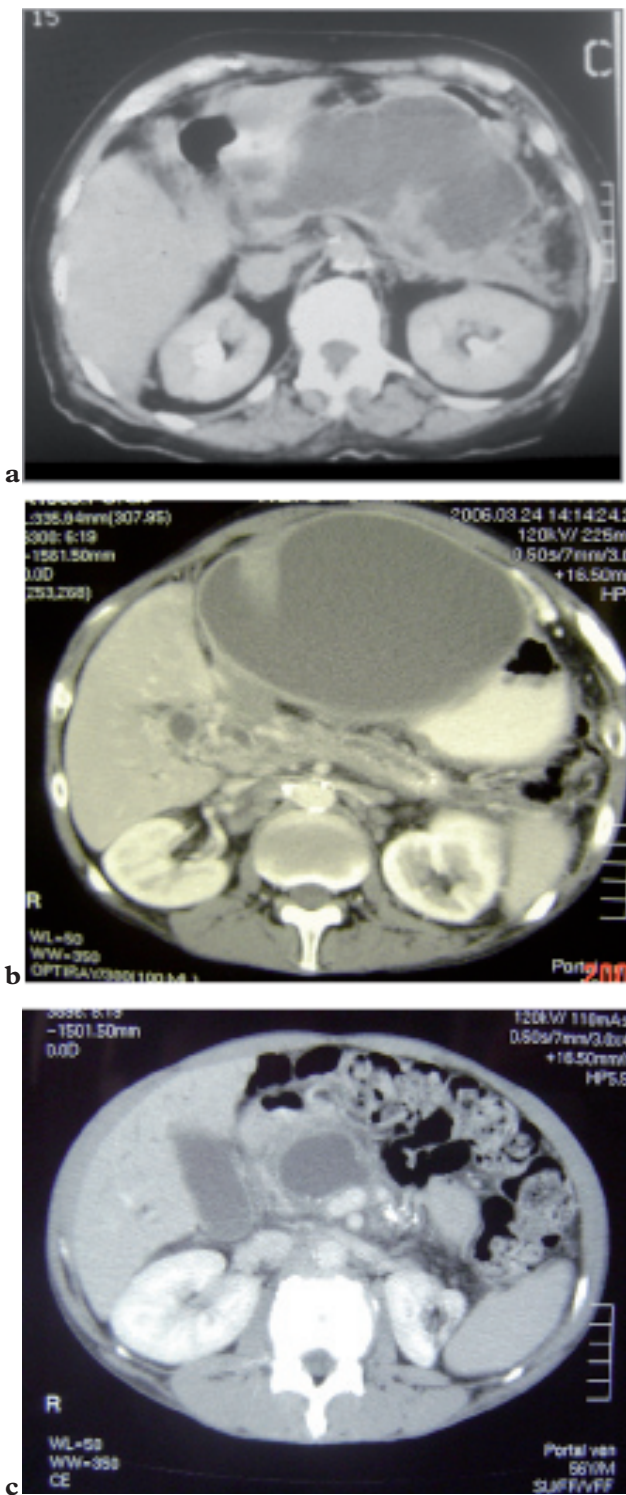


Fig. 1. Different pseudocyst classification types: (a) pseudocyst related to acute pancreatitis (post-necrotic); (b) extrapancreatic pseudocyst related to chronic pancreatitis; (c) intrapancreatic pseudocyst in chronic pancreatitis (retention).

### Percutaneous drainage and acute/post-necrotic pseudocysts

Percutaneous methods include aspiration and catheter drainage under radiological imaging. Aspiration is mostly useful for diagnosis but ineffective for therapy, as a high incidence of re-accumulation can be expected,<sup>52</sup> particularly in patients with pseudocyst duct communication. Gumaste and

Pitchumoni<sup>53</sup> reported a 63% rate of recurrence and 54% failure in an analysis of five studies. Despite this aspiration may play a selected role as primary management due to its low morbidity and ease of application. Aspiration may also contribute by sampling fluid for culture, amylase or tumour markers.

Percutaneous drainage is well established<sup>54</sup> in the management of infected pseudocysts,<sup>55,56</sup> as well as pancreatic abscesses and infected pancreatic necrosis.<sup>20</sup> Success rates reported range between 13% and 90%, and are dependent on the nature of the collection, catheter maintenance, replacement practice and duct communication. The results from major series are listed<sup>54</sup> in Table II, with a cumulative success rate of 70% (235 of 334), 20% complication rate and mortality rate under 1%. In a thorough synopsis by Neff,<sup>57</sup> potential complications elucidated were: bleeding (1 - 2%), visceral/pleural injury (1 - 2%), secondary infection (9%), and formation of pancreatico-cutaneous fistula or recurrence. Adjunctive octreotide administration may decrease duration of required drainage and even fistula formation.<sup>58</sup>

Unfortunately overlap between different PFCs does occur in reporting, which may bias the data. Percutaneous drainage should be the initial mode of treatment for poor-risk patients, for patients with infected pseudocysts, and when pseudocyst rupture is imminent (rapidly expanding collection with increasing symptoms). It is not the treatment of choice in established chronic pancreatitis with associated strictures and communication of the pancreatic duct, as it will invariably be complicated by pancreatico-cutaneous fistula.<sup>5,59</sup> Percutaneous pancreatic cyst gastrostomy has been reported with good success,<sup>20,53</sup> but has not enjoyed widespread support. Fig. 2 demonstrates a CT scan after percutaneous pseudocyst drainage.

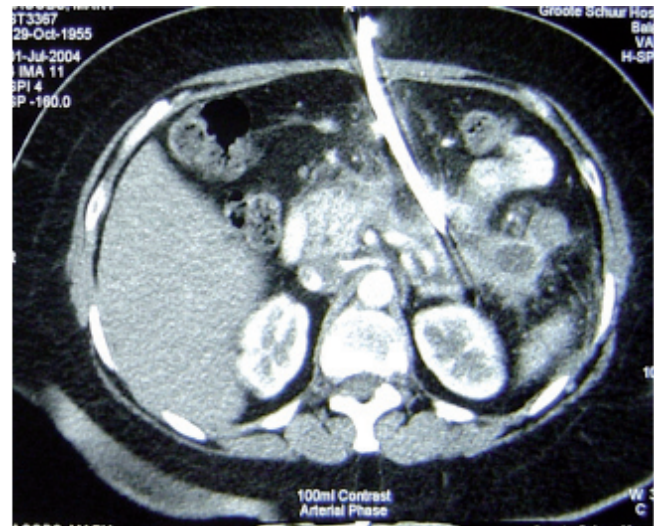


Fig. 2. Percutaneous pseudocyst drainage.

### Endoscopic therapy

The first endoscopic transgastric pseudocyst needle aspiration was reported in 1975 by Rogers *et al.*,<sup>65</sup> with the first successful transmural endoscopic drainage reported in 1985 by Kozarek *et al.*<sup>66</sup> Over the past decade a plethora of published series mirror the increased popularity and application of these methods to the management of pancreatic pseudocysts.

Endoscopic options may be transenteric through the stomach (endoscopic cystgastrostomy), duodenum (endoscopic cystduodenostomy) or pancreatic duct (transpapillary drainage). These different approaches have been evaluated

TABLE II. RESULTS OF PERCUTANEOUS DRAINAGE OF PANCREATIC PSEUDOCYSTS

Author (year) (No. of patients)	Failure	Failure	Mean drainage duration (d)	Mortality	Recurrence	Mean follow-up	Complications	Mean hospital stay (d)
D'Egidio <i>et al.</i> <sup>5</sup> (1991) (N = 23)	22 (96%)	NA	NA	0	1 (4)	NA	2 (9%)	NA
Van Sonnenberg <i>et al.</i> <sup>58</sup> (N = 101)	91 (90%)	6 (6%)	20	0	NA	NA	10 (10%)	NA
Anderson <i>et al.</i> <sup>60</sup> (1989) (N = 22)	13 (60%)	3 (14%)	NA	0	NA	NA	NA	30
Spivak <i>et al.</i> <sup>61</sup> (1998) (N = 27)	17 (63%)	9 (33%)	NA	1	6 (22%)	3 yrs	NA	NA
Adams <i>et al.</i> <sup>62</sup> (1992) (N = 52)	35 (67%)	17 (33%)	42	0	NA	NA	4 (8%) major 25 (56%) drain infection	NA
Grosso <i>et al.</i> <sup>63</sup> (1989) (N = 43)	29 (67%)	14 (33%)	NA	0	9/38 (24%)	2 - 26 mo.	2 (7%)	NA
Heider <i>et al.</i> <sup>64</sup> (1999) (N = 66)	28 (42%)	38 (58%)	38	0	NA	NA	NA	45

NA = data not available.

in several large series, which allow assessment of their role in the management of pancreatic pseudocysts.

**Transpapillary drainage**

This is possible in pseudocysts that communicate with the pancreatic duct, ideally with a proximal duct obstruction or disruption in close proximity to the papilla.<sup>22,67</sup> Technically demanding, this technique requires positioning of a coaxial guidewire system across the stricture and stent placement (5 or 7F) into the pseudocyst, or across the site of the disruption. No significant difference exists with regard to whether the tip is placed into the pseudocyst or beyond the duct defect.<sup>68,69</sup> In 1997 Beekingham *et al.*<sup>70</sup> provided a detailed summary of reported series of transpapillary drainage. In 117 patients successful drainage was achieved in 84%, with a 9% recurrence rate over a 2-year mean follow-up period. As can be expected drainage of pseudocysts situated in the tail of the pancreas was associated with more failures despite successful stent placement.<sup>71,72</sup> The commonest complication was acute pancreatitis (5%). Concern has been expressed regarding stent-induced stricturing, but Huibregste *et al.*<sup>73</sup> showed no clinical sequelae in patients 3 years after stenting.

**Transmural drainage**

Certain prerequisites are required before performing drainage in this manner. Only pseudocysts involving the head or body of the pancreas (which occur in 70%)<sup>30</sup> are suitable. Ideally the pseudocyst should be adherent to the gastrointestinal mucosa, there should be a visible bulge endoscopically, and the distance between bowel lumen and pseudocyst cavity as measured by CT or endoscopic ultrasound, should be less than 10 mm. Approximately half of chronic and 25% of acute pseudocysts are suitable for this approach. A needle knife is used to enter the pseudocyst cavity, followed by insertion of a guidewire/coaxial system. Most endoscopists place one or two temporary plastic stents to maintain communication. Enlarging the opening by excising a disc of tissue, while promoting drainage, may increase bleeding rates.

Cumulative series of endoscopic cystgastrostomy reported success rates of 82%, recurrence rates of 18%, and 16% rates of major complications (8% bleeding, 8% perforation). In the cystduodenostomy group, the success rate was 89%, with a lower recurrence rate of 6%. Major complications

were less frequent at 8% (4% bleeding, 4% perforation).<sup>70</sup> More recent series<sup>74,75</sup> have supported these findings of a high success rate with major complication rates between 5% and 6%. Endoscopic drainage of pseudocysts with necrotic contents increases procedure-related complications,<sup>76</sup> and is generally discouraged.<sup>28</sup> Despite initial promise that it would assist transmural drainage, endoscopic ultrasound has not decreased complications, including bleeding. This was demonstrated by Kahaleh *et al.*<sup>77</sup> in a prospective study comparing conventional with endoscopic ultrasound-guided drainage in 99 patients. Complications occurred in 19% of the endoscopic group and 18% of the conventional group.

Baron *et al.*<sup>78</sup> sought to determine outcome differences after endoscopic drainage of pancreatic necrosis, acute and chronic pseudocysts. The success in the chronic pseudocyst (CP) group was significantly better (92%) than that in the acute pseudocyst (AP) group (74%). Differences in complication rates (CP 17% v. AP 19%), and recurrence (CP 12% v. AP 9%) were not significant. Patients with chronic pseudocysts spent significantly less time in hospital (3 v. 9 days). In a recent study of 170 patients from Helsinki<sup>79</sup> the success rate was 86%, with a 10% complication rate; 13.9% required surgery for endoscopy failures.

Current available data suggest that endoscopic management provides an acceptable substitute to surgery. It is important to note that a significant level of expertise is required in order to perform these advanced procedures with high success and low morbidity.<sup>80</sup> A summary of some of the series<sup>70,20</sup> pertaining to endoscopic drainage is presented in Table III. Fig. 3 demonstrates an example of endoscopic cystgastrostomy on CT.

**Surgical intervention**

**Open surgery**

Surgery still plays an important role in the management of pancreatic pseudocysts. It is the treatment of choice for patients with recurrent pseudocysts, when less invasive methods fail, and for patients with a suspected neoplastic cyst. Open surgical procedures include internal drainage, external drainage and excision. External drainage is seldom performed and reserved for infected fluid collections, usually after failure of percutaneous methods and invariably in sick

TABLE III. SUMMARY OF ENDOSCOPIC PSEUDOCYST DRAINAGE<sup>70,20</sup>

Endoscopic modality	Patients	Initial success	Complications	Recurrence	Long-term success	Follow-up (mo.)
Transpapillary	117	98 (84%)	14 (12%)	10 (9%)	88 (75%)	15 - 37
Cystgastrostomy	50	41 (82%)	11 (22%)	9 (18%)	32 (64%)	9 - 48
Cystduodenostomy	71	63 (89%)	7 (10%)	4 (6%)	59 (83%)	9 - 48

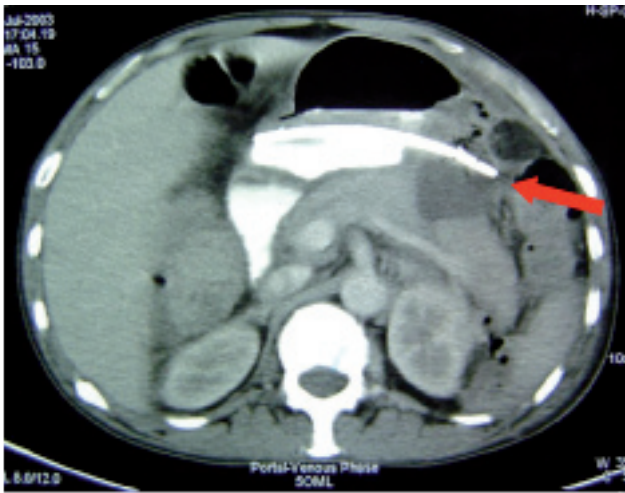


Fig. 3. Endoscopic cystgastrostomy (arrow indicates endoscopic stent).

patients. This accounts for high mortality, recurrence and fistula rates of over 10%.<sup>81</sup>

Internal drainage options include cystgastrostomy (Fig. 4), cystduodenostomy and cystjejunostomy. Anatomical position of the cyst determines the most appropriate procedure. Principles include aspiration of cyst fluid for localisation and amylase, enterotomy and stay suture placement into the cyst wall before opening. A portion of the cyst wall is removed for histological examination and the bowel pseudocyst communication is circumferentially sutured to maintain patency and haemostasis. Mortality in studies from the late 1990s<sup>81</sup> is 3% with an 8% recurrence rate.

Excision of pseudocysts in the tail or body by distal pancreatectomy (with or without splenectomy) is indicated for complicated pseudocysts, or when there is contiguous extension into the splenic hilum.

### Laparoscopic pseudocyst drainage

Enthusiasm for and perceived benefits of laparoscopic surgery have been extended to drainage of pancreatic pseudocysts. The principles of open surgery with the creation of a dependent cyst enterostomy can be achieved via this minimal access approach. Laparoscopic cystgastrostomy is the most commonly performed laparoscopic procedure for pseudocysts located in the lesser sac. Variations of the procedure include endogastric,<sup>82-89</sup> transgastric<sup>82,90-92</sup> and extragastric<sup>82,93,94</sup> approaches. Access to the posterior gastric wall is gained through the introduction of ports including the laparoscope (endogastric), an anterior gastrotomy (transgastric), or via the lesser sac (extragastric). An endoscopically assisted laparoscopic approach has also been described.<sup>95</sup> More distal pseudocysts have been drained through variable types of Roux-en-Y laparoscopic cystjejunostomy.<sup>88,96,97</sup>

Initial results indicate a success rate of 77 - 100%, with a complication rate of 8 - 17% and no mortality or recur-

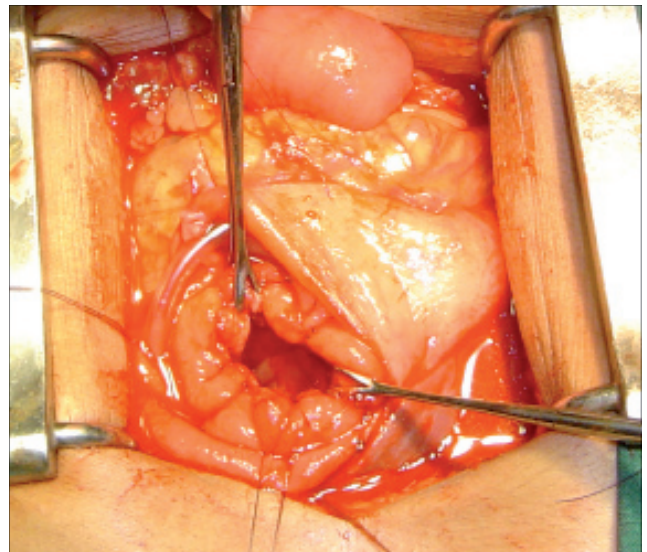


Fig. 4. Surgical pseudocyst gastrostomy.

rence.<sup>82,84,86,89,92</sup> Total reported numbers are small and larger series are required for meaningful comparison with other treatment modalities, open surgery in particular.

### Comparison of treatment options

There are currently no prospective randomised trials comparing the various approaches in the management of pancreatic pseudocysts. High complication and mortality rates were reported in historical surgical series,<sup>43,98,99</sup> which can bias current interpretation and comparison with other approaches. More recent complication rates<sup>13,51,100</sup> have been in the region of 5 - 15%, with little or no mortality. These results, combined with the very low rate of recurrence with surgery, mean that this option is still the standard by which other management approaches are measured.

Numerous retrospective studies have compared percutaneous to surgical drainage, predominantly concerning pseudocysts following acute pancreatitis. While earlier studies showed a higher mortality in the surgical group,<sup>60</sup> later comparisons<sup>62</sup> showed no difference. When all variables were taken into account, as reported by Lang *et al.*,<sup>101</sup> the results were similar. High secondary tract infection and prolonged pancreatic drainage (mean drainage of up to 42 days) via the catheter was reported in certain studies of percutaneous drainage.

Similar results in terms of success, morbidity and mortality have been reported in two retrospective studies<sup>102,103</sup> comparing endoscopic drainage with surgery. Nealon and Walser, however,<sup>104</sup> issue a caution regarding the potential complications of non-surgical methods and stress the role of surgery in managing these. They retrospectively reviewed 79 patients with complications following non-operative measures, 66 (84%) of whom required subsequent operation. Of

note is the low complication rate (6%) in the historical comparative surgical group of 100 patients in this experienced surgical unit. The higher efficacy of surgical management of pancreatic pseudocysts compared with non-invasive methods needs to be taken into consideration when comparing different management modalities.

REFERENCES

1. Bradley EL III. A clinically based classification system for acute pancreatitis. *Arch Surg* 2003; **128**: 586-590.
2. Bradley EL III, Gonzalez AC, Clemens JL jun. Acute pancreatic pseudocysts: incidence and implications. *Ann Surg* 1976; **184**: 734-737.
3. Andren-Sandberg A, Dervenis C. Pancreatic pseudocysts in the 21st century. Part 1: Classification, pathophysiology, anatomic considerations and treatment. *J Pancreas (Online)* 2004; **5**: 8-24.
4. Pitchumoni CS, Agarwal N. Pancreatic pseudocysts. When and how should drainage be performed? *Gastroenterol Clin North Am* 1999; **28**: 615-639.
5. D'Egido A, Schein M. Pancreatic pseudocysts: A proposed classification and its management implications. *Br J Surg* 1991; **78**: 981-984.
6. Walt AJ, Bouwman DL, Weaver DW, Sachs RJ. The impact of technology on the management of pancreatic pseudocyst. 5th annual Samuel Jason Mixter Lecture. *Arch Surg* 1990; **125**: 759-763.
7. O'Malley VP, Cannon JP, Postier RG. Pancreatic pseudocysts: cause, therapy, and results. *Am J Surg* 1985; **150**: 680-682.
8. Kolars JC, Allen MO, Ansel H, Silvis SE, Vennes JA. Pancreatic pseudocysts: clinical and endoscopic experience. *Am J Gastroenterol* 1989; **84**: 259-264.
9. Bourliere M, Sarles H. Pancreatic cysts and pseudocysts associated with acute and chronic pancreatitis. *Dig Dis Sci* 1989; **34**: 343-348.
10. Usatoff V, Brancatisano R, Williamson RC. Operative treatment of pseudocysts in patients with chronic pancreatitis. *Br J Surg* 2000; **87**: 1494-1499.
11. Yeo CJ, Sarr MG. Cystic and pseudocystic diseases of the pancreas. *Curr Probl Surg* 1994; **31**: 165-243.
12. Bosman-Vermeeren JM, Veereman-Wauters G, Broos P, Eggermont E. Somatostatin in the treatment of a pancreatic pseudocyst in a child. *J Pediatr Gastroenterol Nutr* 1996; **23**: 422-425.
13. Grace PA, Williamson RCN. Modern management of pancreatic pseudocyst. *Br J Surg* 1993; **80**: 573-581.
14. Imrie CW, Buist LJ, Shearer MG. Importance of cause in the outcome of pancreatic pseudocysts. *Am J Surg* 1988; **156** (3 Pt 1): 159-162.
15. London NJ, Neoptolemos JP, Lavelle J, Bailey I, James D. Serial computed tomography scanning in acute pancreatitis: a prospective study. *Gut* 1989; **30**: 397-403.
16. Imrie CW. Epidemiology, clinical presentation and behavior of acute pseudocysts. In: Bradley EL, ed. *Acute Pancreatitis Diagnosis and Therapy*. New York: Raven Press, 1994: 175-179.
17. Kourtesis G, Wilson SE, Williams RA. The clinical significance of fluid collections in acute pancreatitis. *Am Surg* 1990; **56**: 796-799.
18. Barthet M, Bugallo M, Moreira LS, Bastid C, Sastre B, Sahel J. Management of cysts and pseudocysts complicating chronic pancreatitis. A retrospective study of 143 patients. *Gastroenterol Clin Biol* 1993; **17**: 270-276.
19. Ammann RW, Akovbiantz A, Largiader F, Schueler G. Course and outcome of chronic pancreatitis. Longitudinal study of a mixed medical-surgical series of 245 patients. *Gastroenterology* 1984; **86** (5 Pt 1): 820-828.
20. Bornman PC, Beckingham IJ, Krige JEJ. In: Schein M, Wise L, eds. *Crucial Controversies in Surgery*. Vol. 3. Philadelphia: Lippincott Williams & Wilkins, 1999: 170-186.
21. Richter HM. Natural history of pancreatic pseudocysts. In: Howard J, Idezuki Y, Inse I, Prinz R, eds. *Surgical Diseases of the Pancreas*. Baltimore, Md: Williams & Wilkins, 1998: 417-421.
22. Neoptolemos JP, London NJ, Carr-Locke DL. Assessment of main pancreatic duct integrity by endoscopic retrograde pancreatography in patients with acute pancreatitis. *Br J Surg* 1993; **80**: 94-99.
23. Nealon WH, Townsend CM jun, Thompson JC. Preoperative endoscopic retrograde cholangiopancreatography (ERCP) in patients with pancreatic pseudocyst associated with resolving acute and chronic pancreatitis. *Ann Surg* 1989; **209**: 532-540.
24. Kloppel G, Maillet B. Pseudocysts in chronic pancreatitis: A morphological analysis of 57 resection specimens and 9 autopsy pancreas. *Pancreas* 1991; **6**: 266-274.
25. Kolars JC, Allen MO, Ansel H, Silvis SE, Vennes JA. Pancreatic pseudocysts: clinical and endoscopic experience. *Am J Gastroenterol* 1989; **84**: 259-264.
26. Nealon WH, Walser E. Duct drainage alone is sufficient in the operative management of pancreatic pseudocyst in patients with chronic pancreatitis. *Ann Surg* 2003; **237**: 614-622.
27. Vane DW, Grosfeld JL, West KW, Rescorla FJ. Pancreatic disorders in infancy and childhood: experience with 92 cases. *J Pediatr Surg* 1989; **24**: 771-776.
28. Beckingham IJ, Krige JEJ, Bornman PC, Terblanche J. Long term outcome of endoscopic drainage of pancreatic pseudocysts. *Am J Gastroenterol* 1999; **94**: 71-74.
29. Colarian JH, Sekkarie M, Rao R. Pancreatic pseudocyst mimicking idiopathic achalasia. *Am J Gastroenterol* 1998; **93**: 103-105.
30. Weaver DW, Bouwman DC, VandenBerg PM, et al. Biliary tract obstruction caused by pancreatic pseudocysts: Treatment and outcome. *Dis Surg* 1987; **4**: 133-141.

31. Christensen M, Matzen P, Schulze S, Rosenberg J. Complications of ERCP: a prospective study. *Gastrointest Endosc* 2004; **60**: 721-731.
32. Scheiman JM. Cystic lesion of the pancreas. *Gastroenterology* 2005; **128**: 463-469.
33. Warshaw A, Rutledge P. Cystic tumors mistaken for pancreatic pseudocysts. *Ann Surg* 1987; **205**: 393-398.
34. Brugge WR, Lauwers GY, Sahani D, Fernandez-del Castillo C, Warshaw AL. Cystic neoplasms of the pancreas. *N Engl J Med* 2004; **351**: 1218-1226.
35. Nealon WH, Townsend CM, Thompson JC. Preoperative endoscopic retrograde cholangiopancreatography (ERCP) in patients with pancreatic pseudocyst associated with resolving acute and chronic pancreatitis. *Ann Surg* 1989; **209**: 532-540.
36. Ahearne PM, Baille JM, Cotton PB, et al. An endoscopic retrograde cholangiopancreatography (ERCP)-based algorithm for the management of pancreatic pseudocysts. *Am J Surg* 1992; **163**: 111-116.
37. Andren-Sandberg A, Dervenis C. Pancreatic pseudocysts in the 21st century. Part 2: Natural history. *J Pancreas (Online)* 2004; **5**: 64-70.
38. Warshaw AL, Rattner DW. Timing of surgical drainage for pancreatic pseudocyst. Clinical and chemical criteria. *Ann Surg* 1985; **202**: 720-724.
39. Bourliere M, Sarles H. Pancreatic cysts and pseudocysts associated with acute and chronic pancreatitis. *Dig Dis Sci* 1989; **34**: 343-348.
40. Maringhini A, Uomo G, Patti R, et al. Pseudocysts in acute nonalcoholic pancreatitis: incidence and natural history. *Dig Dis Sci* 1999; **44**: 1669-1673.
41. Vitas GJ, Sarr MG. Selected management of pancreatic pseudocysts: Operative versus expectant management. *Surgery* 1992; **111**: 123-130.
42. Yeo CJ, Bastides JA, Lynch-Nyhan A, et al. The natural history of pancreatic pseudocysts documented by computed tomography. *Surg Gynecol Obstet* 1990; **170**: 411-417.
43. Bradley EL, Clements JL jun, Gonzalez AC. The natural history of pancreatic pseudocysts: a unified concept of management. *Am J Surg* 1979; **137**: 135-141.
44. Gouyon B, Levy P, Ruzsniowski P, et al. Predictive factors in the outcome of pseudocysts complicating alcoholic chronic pancreatitis. *Gut* 1997; **41**: 821-825.
45. Aranha GV, Prinz RA, Esguerra AC, Greenlee HB. The nature and course of cystic pancreatic lesions diagnosed by ultrasound. *Arch Surg* 1983; **118**: 486-488.
46. Beebe DS, Burburick MP, Onstad GR, et al. Management of pancreatic pseudocysts. *Surg Gynecol Obstet* 1989; **159**: 562-564.
47. Nguyen BL, Thompson JS, Edney JA, et al. Influence of the etiology of pancreatitis on the natural history of pancreatic pseudocysts. *Am J Surg* 1991; **162**: 527-531.
48. Bradley EL, Clements JL jun, Gonzalez AC. The natural history of pancreatic pseudocysts: a unified concept of management. *Am J Surg* 1979; **137**: 1135-1141.
49. Sarles H, Muratore R, Sarles JC. Etude anatomique des pancreatites chroniques de l'adulte. *Sem Hop* 1961; **25**: 1507-1522.
50. Sarles H, Martin M, Camatte R, Sarles JC. Le demembrement des pancreatites: Les pseudokystes des pancreatites aiguës et des pancreatites chroniques. *Pres Med* 1963; **5**: 237-240.
51. Nealon WH, Walser E. Main pancreatic ductal anatomy can direct choice of modality for treating pancreatic pseudocysts (surgery versus percutaneous drainage). *Ann Surg* 2002; **235**: 751-758.
52. Hancke S, Pedersen JF. Percutaneous puncture of pancreatic cysts guided by ultrasound. *Surg Gynecol Obstet* 1976; **142**: 551-552.
53. Gumaste V, Pitchumoni CS. Pancreatic pseudocyst. *Gastroenterologist* 1996; **4**: 33-43.
54. Bhattacharya D, Ammori BJ. Minimally invasive approaches to the management of pancreatic pseudocysts. *Surg Laparosc Endosc Percutan Tech* 2003; **13**: 141-148.
55. Van Sonnenberg E, Wittich GR, Casola G, et al. Percutaneous drainage of infected and non-infected pancreatic pseudocysts: Experience in 101 cases. *Radiology* 1989; **170**: 757-761.
56. Tsiotos G, Sarr M. Management of fluid collections and necrosis in acute pancreatitis. *Curr Gastroenterol Rep* 1999; **1**: 139-144.
57. Neff R. Pancreatic pseudocysts and fluid collections - percutaneous approaches. *Surg Clin North Am* 2001; **81**: 399-403.
58. D'Agostino HB, Van Sonnenberg E, Sanchez RB, et al. Treatment of pancreatic pseudocyst with percutaneous drainage and octreotide. *Radiology* 1993; **187**: 685-688.
59. D'Egido A, Schein M. Percutaneous drainage of pancreatic pseudocysts: a prospective study. *World J Surg* 1991; **16**: 141-146.
60. Anderson R, Sundberg I, Bengmark S. Management of pancreatic pseudocysts. *Br J Surg* 1989; **76**: 550-552.
61. Spivak H, Galloway J, Amerson J, et al. Management of pancreatic pseudocysts. *J Am Coll Surg* 1998; **186**: 507-511.
62. Adams DB, Anderson MC. Percutaneous catheter drainage compared with internal drainage in the management of pancreatic pseudocyst. *Ann Surg* 1992; **215**: 571-578.
63. Grosso M, Gandini G, Cassinis MC, et al. Percutaneous treatment (including pseudocystogastrostomy) of 74 pancreatic pseudocysts. *Radiology* 1989; **173**: 493-497.
64. Heider RBS, Meyer AA, Galanko JA, et al. Percutaneous drainage of pancreatic pseudocysts is associated with a higher failure rate than surgical treatment in unselected patients. *Ann Surg* 1999; **229**: 781-787.
65. Rogers BH, Cicurel NJ, Seed RW. Transgastric needle aspiration of a pancreatic pseudocyst through an endoscope. *Gastrointest Endosc* 1975; **21**: 133-134.

66. Kozarek RA, Brayko CM, Harlan J, *et al.* Endoscopic drainage of pancreatic pseudocysts. *Gastrointest Endosc* 1985; **31**: 322-328.
67. Smits MF, Rauws EA, Tytgat GN, *et al.* The efficacy of endoscopic treatment of pancreatic pseudocysts. *Gastrointest Endosc* 1995; **42**: 202-207.
68. Gumaste UV, Deve PB. Pancreatic pseudocyst drainage – the needle or the scalpel? *J Clin Gastroenterol* 1991; **13**: 500-505.
69. Barkin JS, Hyder SA. Changing concepts in the management of pancreatic pseudocysts. *Gastrointest Endosc* 1989; **35**: 62-64.
70. Beekingham IJ, Krige JE, Bornman PC, *et al.* Endoscopic management of pancreatic pseudocysts. *Br J Surg* 1997; **84**: 1638-1645.
71. Catalano MF, Geenen JE, Schmalz MJ, *et al.* Treatment of pancreatic pseudocysts with ductal communication by transpapillary pancreatic duct endoprosthesis. *Gastrointest Endosc* 1995; **42**: 214-218.
72. Barthet M, Sahel J, Bodiou-Bertei C, *et al.* Endoscopic transpapillary drainage of pancreatic pseudocysts. *Gastrointest Endosc* 1995; **42**: 208-213.
73. Huibregtse K, Schnider B, Vrij AA, *et al.* Endoscopic pancreatic drainage in chronic pancreatitis. *Gastrointest Endosc* 1988; **34**: 9-15.
74. Giovannini M, Pesenti C, Rolland AL, *et al.* Endoscopic ultrasound guided drainage of pancreatic pseudocysts or pancreatic abscesses using a therapeutic echo-endoscope. *Endoscopy* 2001; **33**: 473-477.
75. Norton ID, Clain JE, Wiersema MJ, *et al.* Utility of endoscopic ultrasonography in endoscopic drainage of pancreatic pseudocysts in selected patients. *Mayo Clin Proc* 2001; **76**: 794-798.
76. Chak A. Endosonographic-guided therapy of pancreatic pseudocysts. *Gastrointest Endosc* 2000; **52**: 23-27.
77. Kahaleh M, Shami VM, Conaway MR, *et al.* Endoscopic ultrasound drainage of pancreatic pseudocyst: a prospective comparison with conventional endoscopic drainage. *Endoscopy* 2006; **38**: 355-359.
78. Baron TH, Harewood GC, Morgan DE, Yates MR. Outcome differences after endoscopic drainage of pancreatic necrosis, acute pancreatic pseudocysts, and chronic pancreatic pseudocysts. *Gastrointest Endosc* 2002; **56**: 7-17.
79. Weckman L, Kylanpaa ML, Puolakkainen P, Halttunen J. Endoscopic treatment of pancreatic pseudocysts. *Surg Endosc* 2006; **20**: 603-607.
80. Schutz SM, Leung JWC. Pancreatic endotherapy for pseudocysts and fluid collections. *Gastrointest Endosc* 2002; **56**: 150-152.
81. Bumpers HL, Bradley EL III. Treatment of pancreatic pseudocysts. In: Howard J, Idezuki Y, Ihse I, eds. *Surgical Diseases of Pancreas*. Baltimore: Williams & Wilkins, 1998: 423-432.
82. Park A, Schwartz R, Tandan V, *et al.* Laparoscopic pancreatic surgery. *Am J Surg* 1999; **177**: 158-163.
83. Corvera CU, Kirkwood KS. Recent advances: general surgery. *BMJ* 1997; **315**: 586-589.
84. Mori T, Abe N, Sugiyama M, *et al.* Laparoscopic pancreatic cystgastrostomy. *J Hepatobiliary Pancreat Surg* 2000; **7**: 28-34.
85. Trias M, Taragona EM, Balague C, *et al.* Intraluminal stapled laparoscopic cystogastrostomy for treatment of pancreatic pseudocyst. *Br J Surg* 1995; **82**: 403.
86. Chowbey PK, Soni V, Sharma A, *et al.* Laparoscopic intragastric stapled cystogastrostomy for pancreatic pseudocyst. *J Laparoendosc Adv Surg Tech* 2000; **11**: 201-205.
87. Holeczy P, Danis J. Laparoscopic transgastric pancreatic pseudocystogastrostomy-first experience with extraluminal approach. *Hepatogastroenterology* 1998; **45**: 2215-2218.
88. Hagopian EJ, Texeira JA, Smith M, *et al.* Pancreatic pseudocyst treated by laparoscopic Roux-en-Y cystojejunostomy. Report of a case and review of the literature. *Surg Endosc* 2000; **14**: 967.
89. Ammori BJ, Bhattacharya D, Senapati PSP. Laparoscopic endogastric pseudocyst gastrostomy: a report of three cases. *Surg Laparosc Endosc Percutan Tech* 2002; **12**(6): 437-440.
90. Way LW, Legha P, Mori T. Laparoscopic pancreatic cystogastrostomy: the first operation in the new field of intraluminal laparoscopic surgery. *Surg Endosc* 1994; **8**: 235.
91. Secchi MA, Tagliaferri E, Quadrelli L, *et al.* Laparoscopic pancreatic cystogastrostomy. A simplified technique. *Br J Surg* 1998; **85**: Suppl 2, 196.
92. Smadja C, Badawy A, Vons C, *et al.* Laparoscopic cystogastrostomy for pancreatic pseudocyst is safe and effective. *J Laparoendosc Adv Surg Tech A* 1999; **9**: 401-403.
93. Gagner M. Laparoscopic transgastric cystogastrostomy for pancreatic pseudocyst. *Surg Endosc* 1994; **8**: 239.
94. Farrell TM, Hunter JG. Endogastric surgery. *Semin Laparosc Surg* 2000; **7**: 22-25.
95. Ramachandran MS, Goel D, Arora V, Kumar M. Gastroscopic-assisted laparoscopic cystgastrostomy in the management of pseudocysts of the pancreas. *Surg Laparosc Endosc Percutan Tech* 2002; **6**: 433-436.
96. Mouiel J, Crafa F. Pancreatic cyst treated by laparoscopic cysto-jejunal anastomosis on a Roux-en-Y loop. *Surg Endosc* 1995; **9**: 625.
97. Frantzides CT, Ludwig KA, Redlich PN. Laparoscopic management of a pancreatic pseudocyst. *J Laparoendosc Surg* 1994; **4**: 55-59.
98. Kohler H, Schafmayer A, Ludtke FE. Surgical treatment of pancreatic pseudocysts. *Br J Surg* 1987; **74**: 813-815.
99. Cooperman AM. The pancreas revisited I: diagnosis, chronic pancreatitis: surgical treatment of pancreatic pseudocyst. *Surg Clin North Am* 2001; **81**: 2001.
100. Nealon WH, Martin S. Analysis of surgical success in preventing recurrent acute exacerbations in chronic pancreatitis. *Ann Surg* 2001; **233**: 793-800.
101. Lang EK, Paolini RM, Pott Meyer A. The efficacy of palliative and definitive percutaneous versus surgical drainage of pancreatic abscesses and pseudocysts: A prospective study of 85 patients. *South Med J* 1991; **84**: 55-64.
102. Barthet M, Buggalo M, Moreira LS, *et al.* Management of cysts and pseudocysts complicating chronic pancreatitis: A retrospective study of 143 patients. *Gastroenterol Clin Biol* 1993; **17**: 270-276.
103. Froeschle G, Meyer-Pannwitz U, Brueckner M, *et al.* A comparison between surgical endoscopic and percutaneous management of pancreatic pseudocysts – long term results. *Acta Chir Belg* 1993; **93**: 102-106.
104. Nealon WH, Walser E. Surgical management of complications associated with percutaneous and/or endoscopic management of pseudocyst of the pancreas. *Ann Surg* 2005; **241**: 948-957.