
Billroth I anastomosis using a circular stapler for corrosive gastric stricture: a novel technique

S Mohsina, A Sonia, S Sureshkumar, G S Sreenath, V Kate

Department of Surgery, Jawaharlal Institute of Postgraduate Medical Education and Research
Pondicherry-605006, India

Corresponding author: Vikram Kate (drvikramkate@gmail.com)

Summary: Resection and hand-sewn Billroth I reconstruction is the commonly carried out procedure for type I gastric strictures. The use of staplers for Billroth I anastomosis is limited. Here we describe a unique technique of Billroth I anastomosis using a circular stapler without a gastrotomy in a case of corrosive gastric stricture. A fourteen-year-old girl with Type I gastric stricture underwent resection of the pre-pyloric stricture and Billroth I reconstruction, for which the shaft of the circular stapler was inserted through the open end of the stomach and a side-to-end anastomosis of the posterior wall of the stomach with the end of the duodenum was carried out. The distal cut open end of the stomach was closed with a linear cutter. The patient made an uneventful recovery. A circular stapler can be used by this technique for Billroth I anastomosis for a pre-pyloric corrosive stricture without a need for additional gastrotomy for introducing the stapler.

Key words: corrosive stricture, circular stapler, gastrectomy, gastroduodenal anastomosis

S Afr J Surg 2018;56(1)

<http://dx.doi.org/10.17159/2078-5151/2018/v56n1a2224>

Introduction

The clinical presentation of corrosive gastric injuries varies from acute gastric injuries such as hyperemia, extensive ulcers and mucosal erosions to chronic gastric strictures.¹ Acids tend to pool in the pre-pyloric area due to the corrosive induced pylorospasm and tends to produce short ring stricture of the stomach described as Type I gastric stricture. Billroth I type reconstruction is the most preferred method following distal gastrectomy for Type I pyloric stricture.¹

Conventionally, the Billroth I reconstruction is done by carrying out a limited resection of pre-pyloric stricture with the pylorus followed by gastroduodenal hand-sewn anastomosis. Although staplers have widely replaced hand-sewn anastomotic procedures, their use in Billroth I reconstruction is limited. There are a few reports of various techniques of use of a circular stapler for gastroduodenal anastomosis.²⁻⁶ Most of the techniques describing the use of circular staplers for Billroth I anastomosis required an additional gastrotomy for introducing the instrument or passage of the instrument through the part of the stomach to be resected. Here we describe a novel technique of carrying out Billroth I reconstruction for a type I gastric stricture using a circular stapler without the need for an additional gastrotomy.

Case Summary and Technique

A 14-year-old girl presented to the department of surgery of a tertiary care hospital, seven days following accidental consumption of toilet cleaner (acid). The patient presented with complaints of epigastric pain and vomiting which was managed conservatively and followed up with serial endoscopies. The patient presented with features suggestive of gastric outlet obstruction one month following the injury. Upper GI endoscopy (UGIE) revealed a normal esophagus and inflamed pylorus with gastric outlet obstruction. A nasogastric tube was inserted under endoscopic guidance and a feeding jejunostomy was carried out to improve the patient's nutritional status. After a period of two months, a UGIE was carried out which revealed a normal esophagus with a normal proximal stomach and a pre-pyloric stricture. Barium studies were carried out which confirmed the pre-pyloric stricture. The patient was posted for elective Billroth I gastrectomy.

Intraoperative details

Under general anesthesia, in supine position, the abdomen was opened through an upper midline incision in layers. A full thickness stricture was noted at the pre-pyloric region for a length of 2 cm (Figure 1A). The rest of the stomach was found to be normal. The right gastric and right gastro epiploic artery

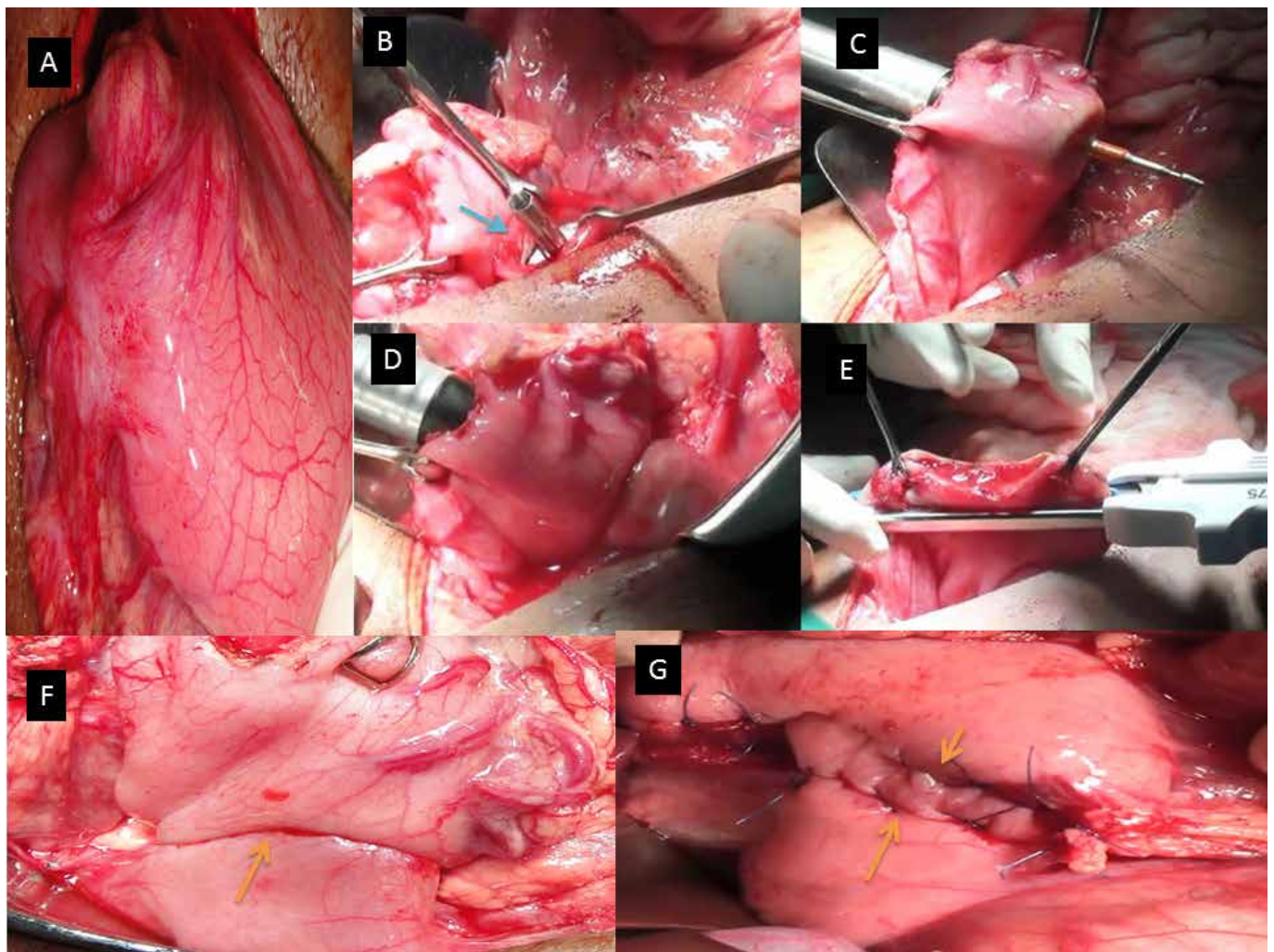


Figure 1: **1A:** Intraoperative photograph showing the pyloric stricture; **1B-1E:** Intraoperative photograph showing the Billroth I reconstruction using circular stapler. **1B:** Anvil of the circular stapler placed in the duodenum (blue arrow); **1C:** passing the shaft of circular stapler through the open end of the stomach closer to the greater curvature; **1D:** Firing of the stapler to create side-to-end gastroduodenal anastomosis between posterior wall of stomach and end of the duodenum; **1E:** Closure of the open end of stomach with a linear cutter; **1F:** Intraoperative photograph showing the stapled side-to-end gastroduodenal anastomosis (yellow arrow); **1G:** Intraoperative photograph showing the closed cut end of the stomach (yellow arrows) which has been inverted with interrupted sero-muscular stitches.

was identified and ligated following which resection of the stricture with the pylorus was carried out.

The Billroth I reconstruction was carried out using a circular stapler (Ethicon Proximate ILS CDH 29 A) (Figure 1B-1E). The anvil was inserted into the duodenal end after ascertaining the size using a sizer and was fixed with purse string sutures (Figure 1B). The shaft of the 29 mm circular stapler was inserted through the open end of the stomach close to the greater curve about 5cm proximal to the cut end (Figure 1C). The anvil and the shaft were locked and a side-to-end gastroduodenal anastomosis was carried out with the end of the duodenum to the side of the posterior wall of the stomach (Figure 1D). The distal cut open end of the stomach was closed with a linear cutter (Figure 1E) and the suture

line (Figure 1F) was inverted with interrupted sero-muscular sutures (Figure 1G). The abdomen was closed in layers and the patient withstood the procedure well.

Post-operatively, the patient made an uneventful recovery. The patient remains asymptomatic and has gained weight during the follow-up period of one year.

Discussion

The use of stapled anastomotic techniques constitutes a major advance in gastrointestinal surgery by providing safe and secure anastomosis with shorter operating time. Circular staplers are widely used in areas where it is difficult to carry out hand-sewn anastomosis such as following low anterior

resection or in esophago-jejunal anastomosis. Recently, there are reports of its use in Billroth I reconstruction; however, the techniques described are varied.

The first report of use of circular stapler for Billroth I reconstruction following distal gastrectomy was by Nance et al.² In this technique, a gastrotomy was made on the anterior wall of the remnant stomach for insertion of the instrument. In a following study, Becker et al. described a technique where the cut edge of the gastric remnant was left open while creating the stapled side-to-end gastroduodenal anastomosis.³ However, this technique was contended by Nakane et al. in terms of greater contamination of the field, who described a modification of the technique without leaving the whole cut edge open.⁴ These techniques were, however, described in patients who underwent resection for gastric cancer. The technique described in the present report is similar to these, however, this has been carried out in a patient of corrosive gastric stricture. This technique allows for the visual examination of gastric remnant for signs of inflammation as well as the anastomotic line, without a need for an additional gastrotomy. Takeuchi et al. described a modification of the previously described techniques in patients of gastric cancer by performing the anastomosis first followed by gastric resection distal to anastomosis, thus reducing the number of instruments required to one circular and linear stapler.⁵ Similar modifications were described for gastric cancer patients, but were contended due to the possible risk of cancer cell implantation. A similar technique was adapted for use in benign pyloric stricture by Hasukic et al.⁶ This technique, however does not allow for visual inspection of the cut edge of the gastric remnant as the resection is carried out after the creation of anastomosis when compared with the technique described in the present study. There might also be difficulty encountered in these techniques while passing the instrument through a thickened pylorus as opposed to the present technique. The present technique, however, utilised an additional linear cutter when compared to the technique used by Hasukic et al.⁶

To the best of our knowledge no similar technique has been described in literature with the use of circular stapler for corrosive stricture. This becomes relevant for developing countries where the prevalence of corrosive injuries is

relatively high. This technique is easy to perform and provides a secure suture line when compared to hand-sewn anastomosis. There is also a considerable reduction in the operation time and avoidance of the need for an additional gastrotomy when compared to the conventional methods of using a circular stapler.

Conclusion

Although a number of techniques for use of circular staplers for Billroth I reconstruction have been described, it is seldom practised for the reconstruction for a benign gastric stricture. This report demonstrates a simple, safe and easy-to-perform technique without need for additional gastrotomy and shorter operating time in a patient with a pre-pyloric corrosive stricture.

Disclosure: Nil

Acknowledgements: Nil

Conflict of interest: Nil

REFERENCES

1. Ananthakrishnan N, Parthasarathy G, Kate V. Chronic corrosive injuries of the stomach- a single unit experience of 109 patients over 30 years. *World J Surg.* 2010;34(4):758-64. doi: 10.1007/s00268-010-0393-8
2. Nance FC. New techniques of gastrointestinal anastomosis with the EEA stapler. *Ann Surg.* 1979;189:587-600.
3. Becker HD, Herfarth C, Liersch W, Schreiber HW. *Surgery of the stomach.* Springer, Berlin Heidelberg New York London Paris Tokyo, p. 35-49.
4. Nakane Y, Kanbara T, Michiura T, Inoue K, Iiyama H, Nakai K et al. Billroth I gastrectomy using a circular stapler to treat gastric cancer. *Surg Today.* 2001;31(1):90-92. doi: 10.1007/s005950170229
5. Takeuchi K, Tsuzuki Y, Ando T, Sekihara M, Hara T, Kori T, et al. A modified stapling technique for performing Billroth I anastomosis after distal gastrectomy. *World J Surg.* 2005;29(1):113-5. doi:10.1007/s00268-004-7356-x
6. Hasukić S, Muratović O, Hasukić I. Use of a circular stapler for Billroth I anastomosis after distal gastrectomy. *S Afr J Surg.* 2013;51(4):144-5. doi:10.7196/SAJS.1631