

# HIV post-tuberculous broncho-oesophageal fistulas: A surgical solution

G Alexander

King Dinuzulu Hospital Complex, Sydenham 4091, Durban, South Africa

Corresponding author: Gerard Alexander (mdalexg@hotmail.com)

**Summary:** We present a patient with HIV/AIDS with multiple tracheo-oesophageal fistulas probably due to previous tuberculosis. An Ivor-Lewis procedure was successfully undertaken following stringent pre-operative preparation. Surgical repair of persistent post-tuberculous tracheo-oesophageal fistulas may be safely undertaken in selected patients with HIV/AIDS.

**Keywords:** trachea; oesophagus; fistula

S Afr J Surg 2017;55(2)

## Case Report

A 27-year-old female was referred with a suspected tracheo-oesophageal fistula. She complained of an intermittent productive cough exacerbated by ingestion of both liquids and solids. She was previously diagnosed with and completed treatment for drug sensitive tuberculosis (DS-TB). She was emaciated (albumin 18 g/l) with an unsuppressed viral load. A gastrograffin swallow inferred the presence of two tracheo-oesophageal fistulas. This was confirmed at 24–28 cm on upper endoscopy and again at bronchoscopy where the fistulas were noted in the main bronchi just below the carina, measuring about 2 cm in diameter on the right and about 0.5 cm on the left (Figure 1). The stomach appeared normal. There was no histological evidence of active TB or malignancy on biopsy. The chest radiograph and computed tomography (CT) scan of the chest showed scattered bilateral bronchiectasis with no significant mediastinal lymph nodes. Twelve weeks of intensive inpatient medical optimization including nutritional support via a nasogastric tube improved her general condition, but as the fistula persisted, surgery was undertaken to close it.

Oesophageal pathology in the upper two-thirds of the oesophagus necessitating an oesophago-gastrectomy requires an Ivor-Lewis procedure in which a mini-laparotomy is used to mobilise the stomach, and a right thoracotomy, entering the thoracic cavity in the fifth intercostal space, is utilised to mobilise the thoracic oesophagus and resect the diseased oesophageal segment. Following a stomach pull-through into the right thoracic cavity, a partial gastrectomy and end to side anastomosis is undertaken to maintain oesophago-gastric continuity.

In view of the number and size of the fistulas, the more predictable nature of a stomach conduit as well as patient co-morbid factors, an Ivor-Lewis procedure was undertaken with selective lung ventilation. The oesophagus was vertically incised at the suspected site of the fistulas. No subcarinal lymph nodes were evident. The oesophagus was then circumferentially excised around the fistulas leaving a 2 cm rim of tissue. Approximately 5 cm of oesophagus was excised proximally to the fistula and another 5 cm distal to it. The right fistula was closed in 2 layers using oesophageal tissue as a patch whilst the left was primarily closed using interrupted 3/0 Vicryl® absorbable. The repair was re-enforced with an intercostal muscle flap.

Ventilation was undertaken using an appropriately placed left sided double lumen Mallinckrodt endotracheal tube.

The post-operative course was uneventful. She was discharged after two weeks and has remained well over the last year.

## Discussion

### Introduction

Due to its anatomical proximity, major airway-oesophageal fistulas predominantly occur as a complication of carcinoma of the esophagus.<sup>1</sup> Trauma and chronic inflammatory disorders especially that of tuberculosis (TB) are the commonest non-malignant causes.<sup>1-4</sup>

Infection of the subcarinal, paratracheal and parabranchial lymph nodes is thought to result in caseative necrosis and abscess formation with eventual rupture into the oesophagus

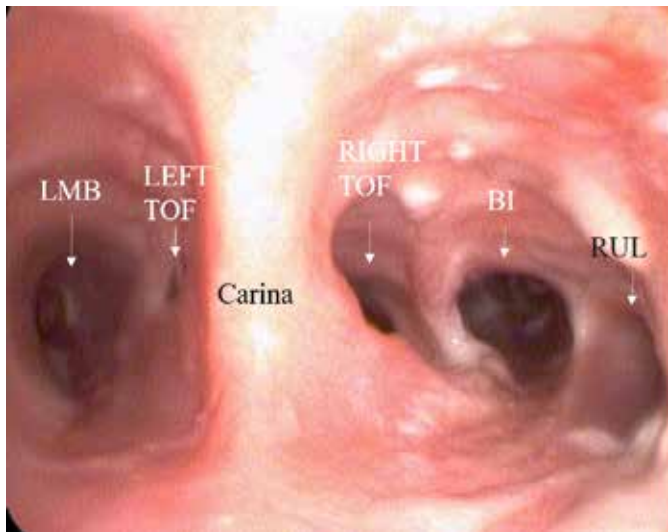


Figure 1: Distal major airway showing subcarinal broncho-oesophageal fistulas

and trachea.<sup>2,3</sup> Most patients with an infective aetiology present with respiratory symptoms and dysphagia. A real time fluoroscopy swallow study using a non-ionic iodinated contrast agent should be the initial investigation.<sup>1,3</sup>

Though relatively rare, the incidence of benign major airway-oesophageal fistulas are increasing due to the high prevalence of immunosuppression associated with HIV/AIDS.

It has also been hypothesised that the development of benign inflammatory fistulas may result from an acute or chronic traction diverticulum due to peri-oesophageal fibrosis secondary to a resolving adenitis.<sup>3</sup> Other rarer causes include, primary tracheal ulcers and primary oesophageal tuberculosis.<sup>2</sup>

A chronic cough or occasional dyspnea may be associated with small fistulas whilst paroxysmal coughing after ingestion of fluids and solids is usually suggestive of larger fistulas.<sup>2,3</sup> Chronic fistulas may also result in increased susceptibility

to recurrent pulmonary infections, eventually leading to bronchiectasis.<sup>3</sup>

If the initial diagnostic investigations are unhelpful, usually due to collapse of the fistula tract, a CT oral contrast swallow may confirm the diagnosis. CT has a proven role in neonatal tracheo-oesophageal fistulas.<sup>1</sup>

Conservative management or pre-operative patient preparation may include a period of total parenteral nutrition (TPN), anti-retroviral therapy, NGT and or percutaneous endoscopic gastrostomy (PEG) feeds (5). NGT feeds may delay healing of the fistula due to persistent physical contact, promotion of gastro-oesophageal reflux and the resultant colonisation of the NGT.<sup>4</sup>

Surgery is usually required when benign fistulas are associated with pulmonary or mediastinal infection.<sup>2,4</sup> The location of the fistula dictates the site of surgical incision required for repair. An interposition flap using muscle, pleura or pericardium is also necessary.<sup>3</sup> Despite the high risk of oesophageal stent migration, this form of management may be necessary in patients unsuitable for surgery.<sup>5</sup>

**Conflict of interest:** none declared.

#### REFERENCES

1. Hegde RG, Kalekar TM, Gaighive MI, Bandgar AS, Pawar SS, Khadse GJ. Esophagobronchial fistulae: Diagnosis by MDCT with oral contrast swallow examination of a benign and a malignant cause. *Indian J Radiol Imaging.* 2013;23:168-72.
2. Wigley FM, Murray HW, Mann RB, Saba GP, Kashima H, Mann JJ. Unusual Manifestation of Tuberculosis: TE fistula. *Am J Med.* 1976;60:310-4.
3. Spalding AR, Burney DP, Richie RE. Acquired Benign Bronchoesophageal Fistulas in the Adult. *Ann Thorac Surg.* 1979;28:378-83.
4. Baijal R, Ramegowda PKH, Jain M, Gupta D, Shah N, Kulkarni S. Clinical profile and management of tuberculous Bronchoesophageal fistula. *J Digestive Endosc.* 2013;4:103-6.
5. Pagano G, Dodi F, Camera M, Passalacqua G, Malfatto E, De Maria A. *AIDS* 2007;21:2561-3.