

Minimally invasive approach for lesions involving the frontal sinus

D E Lubbe,¹ MB ChB, FCORL (SA); K A Stephenson,¹ MB ChB, MRCS, DOHNS; P Semple,² FCS (Neuro) (SA), MMed, PhD

¹Division of Otorhinolaryngology, University of Cape Town, South Africa

²Department of Neurosurgery, University of Cape Town, South Africa

Corresponding author: D E Lubbe (doclubbe@gmail.com)

Background. Traditional open surgery for frontal sinus pathology and cerebrospinal fluid (CSF) leaks is complex and involves a craniotomy. Minimally invasive options offer an alternate solution. We describe and assess the outcome of a minimally invasive approach for lesions and defects involving the frontal sinus.

Methods. The technique introduces an endoscope via a small frontal sinusotomy accessed via a small medial brow incision. This allows excellent visualisation of the frontal sinus. Fine thin-shafted instruments traditionally used during tympanoplasty or pituitary surgery are passed through the sinusotomy together with an endoscope for dissection and tissue excision. This technique can be combined with conventional endonasal surgery.

Results. We describe the use of this technique in three patients: A fracture of the posterior table of the right frontal sinus with CSF leak, a right frontal sinus osteoma and a right frontal sinus mucocoele. Symptom resolution occurred in all patients and no short-term postoperative complications occurred.

Conclusion. This approach avoids the morbidity associated with a craniotomy and obviates the need for postoperative intensive care required for conventional osteoplastic flap surgery or extensive endonasal surgery required for the alternative minimally invasive endoscopic technique. Our initial success merits further assessment of the use of this technique.

S Afr J Surg 2015;53(2):62-64. DOI:10.7196/sajsnew.1781



Cerebrospinal fluid (CSF) leaks secondary to frontal sinus fractures are usually repaired by neurosurgeons through a standard craniotomy or osteoplastic flap procedure with obliteration of the frontal sinus or cranialisation of the intracranial contents (removal

of the posterior wall of the frontal sinus and allowing the frontal lobe to rest against the anterior wall of the sinus).^[1] The objective of surgery is to stop or avoid a potential CSF leak and to avoid the risk of future meningitis. The frontal sinus is usually obliterated during the osteoplastic flap procedure, separating it from the rest of the paranasal sinuses and nasal cavity. Alternatively an endoscopic endonasal approach to frontal sinus CSF leaks can be used. This requires a modified Lothrop procedure for access, necessitating removal of the superior part of the nasal septum, anterior to the first olfactory fibre, and resection of the floor of both frontal sinuses to visualise the posterior wall of the frontal sinuses. This requires advanced technical skills and expensive equipment with operating times averaging 3 - 4 hours. If the modified Lothrop procedure fails, repair is problematic using the traditional approaches since no contained cavity exists to obliterate the sinus. Problematic sinus drainage can occur with stenosis of the neo-ostium even with a modified Lothrop procedure.^[3]

Methods

We describe a simple technique where the endoscope is used through a small medial brow incision. Combined surgery thus

implies the use of an endoscope through a small frontal sinusotomy with a conventional endonasal endoscopic approach. Adequate access to the whole frontal sinus is obtained and fractures of the posterior wall can be repaired, tumours can be removed and mucocoeles managed through this minimally invasive approach.

Surgical technique

Patient preparation and anaesthesia is the same as typically used for functional endoscopic sinus surgery (FESS). The procedure is performed with the patient in a supine position, either lying flat or with the head slightly elevated at 15 degrees. Total intravenous anaesthesia using Propofol and Remifentanyl optimises the surgical field by providing normotensive anaesthesia with a low pulse rate. Local anaesthetic is injected immediately below the medial aspect of the eyebrow and a modified Lynch-Howarth incision used for the skin incision (Fig. 1). The orbicularis oculi muscle is incised and the mucoperiosteum elevated to expose the anterior table of the frontal sinus. A 1 × 1 cm frontal sinusotomy is drilled through the anterior table of the frontal sinus, just large enough to allow introduction of a zero degree endoscope and an instrument (Fig. 2). The incision is located medial to the supratrochlear and supraorbital nerves in order to preserve sensation to the forehead. Delicate, thin-shafted instruments are required; the instruments traditionally used during tympanoplasty or pituitary surgery are easy to pass through the sinusotomy together with an endoscope. For fractures involving the posterior wall of the frontal sinus, the frontal sinus mucosa

overlying the fracture is first removed; this is best done using a small elevator. A diamond drill may be used at the fracture site to ensure all mucosa is adequately removed and to remove any irregular bony edges. If a CSF leak is present, this must be repaired first; abdominal fat, fascia or synthetic dura is placed through the fracture site as an underlay graft, similar to the principles of repairing a tympanic membrane defect. Temporalis fascia is easy to harvest from the post-auricular area with minimal morbidity associated with the donor site (Fig. 3). It is important to ensure that the fronto-nasal duct mucosa is adequately removed and the

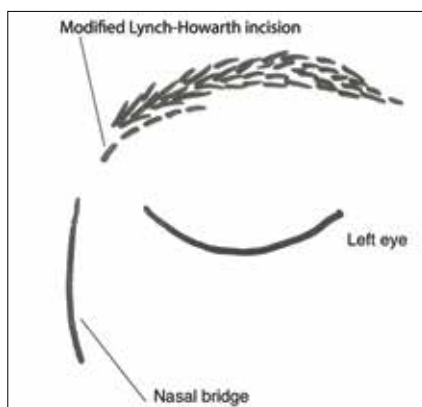


Fig. 1. Diagram of modified Lynch-Howarth eyebrow incision (dotted line).

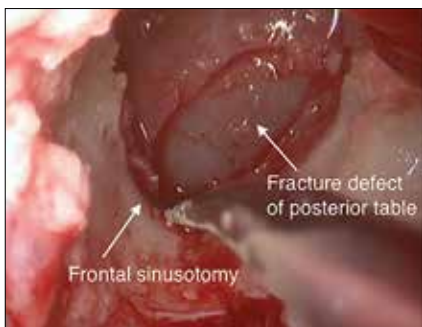


Fig. 2. Frontal sinusotomy with fracture in the posterior table of the frontal sinus.

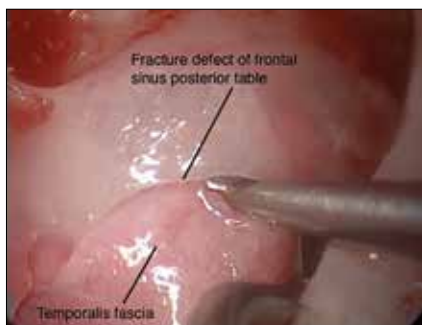


Fig. 3. Underlay graft through frontal sinus fracture.

frontal sinus ostium plugged if the sinus is to be obliterated. Abdominal fat is used to obliterate the frontal sinus in large defects where direct repair alone is insufficient to control a CSF leak. Lastly, the periosteum is sutured over the sinusotomy to prevent herniation of fat through the small defect created in the anterior table of the frontal sinus. The wound is closed in two layers using a dissolvable suture and the skin closed with a nylon suture. If there is a concern regarding adequate obliteration of the fronto-nasal duct, the endoscope can be passed endonasally and the frontal recess obliterated from below using a pedicled flap from either the nasal septum or middle turbinate. The anterior third of the middle turbinate can be rotated into the frontal recess to ensure complete obliteration of the frontal sinus. The repair is held in place by a dural sealant. No nasal packing is required and the patient can be monitored in a general ward for 24 hours before discharge.

For sinonasal tumours extending to but not invading the frontal sinus, the frontal sinusotomy gives adequate access to address the frontal sinus component in most cases. The tumour can be removed using curettes and an endonasal drill is used to ensure that diseased bone is removed. For tumours involving the anterior table or where bony erosion is significant, the traditional approaches are advised. Laterally localised frontal sinus mucocoeles can be accessed through the frontal sinusotomy and the mucocoele marsupialised into the medial aspect of the frontal sinus.

We describe three cases to illustrate the indications for the combined approach to lesions involving the frontal sinus, summarised in Table 1.

Results

Case 1

A 25-year-old male was assaulted in 2005, sustaining a major head injury.

He was admitted for observation but no neurosurgical procedure was required at the time of injury. He subsequently developed headaches and intermittent rhinorrhoea; an episode of bacterial meningitis was diagnosed in September 2010, 5 years after his injury. On admission to our unit in May 2011, CSF rhinorrhoea was confirmed on beta-2-transferrin testing. The combined open and endoscopic minimally invasive technique described was used to repair a left frontal sinus CSF leak and related fracture of the posterior table of the sinus (Figs. 2 and 3). No short-term postoperative complications were observed. The CSF leak recurred in October 2013; the patient then underwent neurosurgery – a craniotomy with anterior cranial fossa repair was performed.

Case 2

Right-sided frontal headaches were the principal presenting complaint of this 43-year-old female patient. A computerised tomography (CT) of the paranasal sinuses demonstrated an osteoma of the right frontal sinus with secondary frontal sinus opacification (Fig. 4). The combined open and endoscopic minimally invasive technique described were used to remove the osteoma (Fig. 5). It was found to be 2 × 2 cm in size, pedicled upon the posterior sinus wall and intersinus septum, and occluding the frontal sinus ostium. No postoperative complications occurred and follow-up to date has been uneventful.

Case 3

A 19-year-old male was referred to our ear, nose and throat (ENT) unit with a 5-year history of nasal obstruction and hyposmia. He had noted displacement of his right eye over a period of 2 years (Fig. 6) and made mention of a facial injury and fracture of his left zygoma, sustained in January 2013. CT was performed at the time of the injury (Fig. 7) and showed an incidental,

Table 1. Indications for combined approach to lesions involving the frontal sinus

		Presenting complaint	Pathology
Case 1	Male, 25 years	Watery rhinorrhoea post blunt head injury	Fracture of posterior table left frontal sinus with CSF leak
Case 2	Female, 43 years	Right frontal pain	Right frontal sinus osteoma
Case 3	Male, 19 years	Displacement of right globe with nasal blockage	Right frontal sinus mucocoele

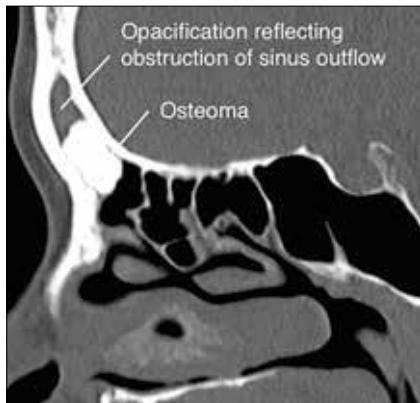


Fig. 4. CT scan, parasagittal plane, demonstrating osteoma of right frontal sinus with secondary sinus outflow obstruction.

laterally located frontal sinus mucocoele and ethmoidal polyposis. Grade 3 nasal polyposis was evident on nasendoscopic examination and he was diagnosed with Samter's triad – asthma, nasal polyposis and aspirin sensitivity. FESS included polypectomies and ethmoidectomies with clearance of the frontal recesses. In addition, the combined open and endoscopic minimally invasive technique described was used to access the lateral frontal sinus mucocoele, to ensure medial communication and drainage to the nasal cavity. No postoperative complications occurred. The displacement of the right globe and facial appearance improved markedly and he remains under ENT care for nasal polyposis management.

Discussion

The osteoplastic flap procedure has been the gold standard approach for repair of frontal sinus fractures with CSF leaks, the removal of frontal sinus tumours and the management of laterally localised frontal sinus mucocoeles. It is however associated with significant morbidity. The surgery requires postoperative intensive care and has potential major sequelae and complications. The frontal bone flap may undergo necrosis with significant cosmetic implications. Frontal sinus mucocoeles may develop years after the surgery if all the frontal sinus mucosa is not adequately removed during obliteration of the sinus.^[2]

The alternative technique described here is relatively simple, minimally invasive, with the only morbidity being that associated with the small skin incision that predictably heals well.

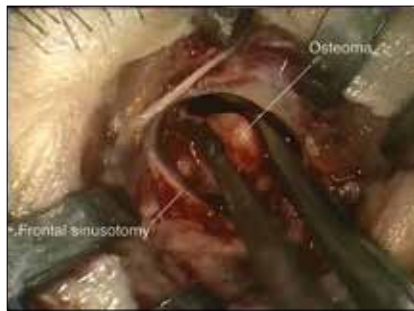


Fig. 5. Removal of osteoma right frontal sinus through sinusotomy.

Excellent endoscopic visualisation of the posterior table of the frontal sinus is obtained through a frontal sinusotomy; any defect can be repaired under direct vision by either an underlay or overlay technique, the frontal sinus mucosa can be removed and the sinus obliterated with abdominal fat if required. Ideally the fracture should be repaired and the frontal sinus not obliterated in order to maintain functionality and ventilation of the sinus. In the event that obliteration is essential (for a large defect with a significant CSF leak), the frontal sinus can be further isolated from the nasal cavity by swinging a pedicled middle turbinate mucosal flap into the frontal recess. Due to the minimally invasive nature of the procedure, intensive care is not required and patients can typically be discharged the following day.

An approach through a modified Lynch-Howarth incision may however risk supraorbital or supratrochlear nerve injury and it is imperative that the incision is made medial to the nerves and that care is taken during elevation of the periosteal flap. Injury to the nerves will result in numbness of the forehead; special care must therefore be taken to safeguard against this. Although there is a theoretical risk of mucocoele formation years later, this risk also exists with an osteoplastic flap procedure. It is imperative to remove all frontal sinus mucosa if the decision has been made to obliterate the sinus. One limitation of this approach is the inability to gain access to the lateral aspect of a well-pneumatised frontal sinus. This procedure should therefore not be attempted in patients who have very large frontal sinuses that extend beyond the lateral canthus of the eye. It is not possible to strip the mucosa off the lateral aspect of the sinus or to repair a defect that lies laterally to the lateral canthus of the eye.

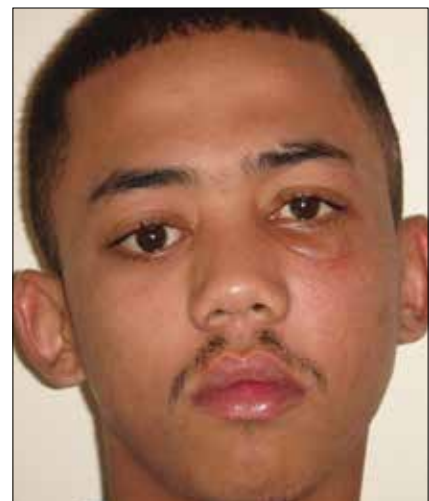

Fig. 6. Clinical photograph of patient, Case 3; displacement of right eye.

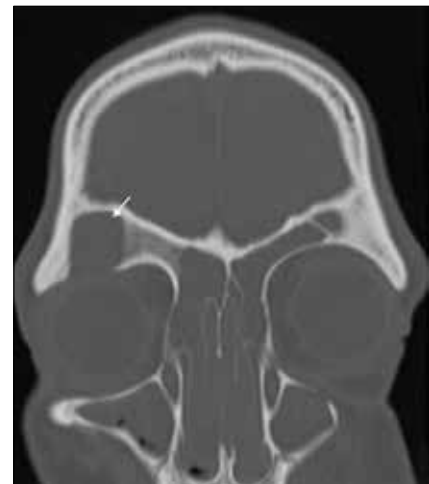

Fig. 7. CT scan, coronal plane, demonstrating lateral mucocoele of right frontal sinus (white arrow).

For these patients, a craniotomy remains the procedure of choice.

A combined endonasal and transfrontal minimally invasive approach is a good alternative approach for frontal sinus fractures (with or without a CSF leak), tumours extending to the frontal sinus and frontal sinus mucocoeles; it should be considered before embarking on major surgery that could be associated with permanent sequelae.

REFERENCES

1. Tedaldi M, Ramieri V, Foresta E, Cascone P, Iannetti G. Experience in the management of frontal sinus fractures. *J Craniofac Surg* 2010;21(1):208-210. [http://dx.doi.org/10.1097/SCS.0b013e3181cfe87]
2. Murphy J, Jones NS. Frontal sinus obliteration. *J Laryngol Otol* 2004;118(8):637-639. [http://dx.doi.org/10.1258/0022215041917943]
3. Becker SS, Duncavage JA, Russell PT. Endoscopic endonasal repair of difficult-to-access cerebrospinal fluid leaks of the frontal sinus. *Am J Rhinol Allergy* 2009;23(2):181-184. [http://dx.doi.org/10.2500/ajra.2009.23.3291]