

Isolated gallbladder perforation following blunt abdominal trauma

S Cheddie, MMed (Surg), FCS (SA); C G Manneh, MB ChB; N M Naidoo, FCS (SA)

Madadeni Hospital and Department of General Surgery, Nelson R Mandela School of Medicine, College of Health Sciences, University of KwaZulu-Natal, Durban, South Africa

Corresponding author: S Cheddie (scheddie@gmail.com)

A 32-year-old man sustained an isolated perforation of the gallbladder following blunt abdominal trauma. A preoperative diagnosis was made on an ultrasound scan, which showed a pericholecystic fluid collection only. At laparotomy, a gallbladder perforation at the infundibulum was identified with a localised bile collection, warranting a cholecystectomy. Isolated gallbladder injury from blunt abdominal trauma is rare, and a high index of suspicion is required to establish the diagnosis. Cholecystectomy is the treatment of choice.

S Afr J Surg 2014;52(4):118-119. DOI:10.7196/SAJS.2111



Blunt abdominal trauma (BAT) has been reported to account for 66.3% of admissions to a level I trauma unit in KwaZulu-Natal Province, South Africa.^[1]

Patients are often managed conservatively in the absence of haemodynamic instability and peritonism.

Selective non-operative management is a well-validated strategy in the management of BAT, less than 10% of patients undergoing laparotomy.^[2] This case highlights a rare isolated injury from BAT that can be addressed easily with appropriate surgery.

Case report

A 32-year-old man presented with right upper quadrant (RUQ) tenderness following a blow to the abdomen with the butt of a gun.

He was haemodynamically stable and had no signs of peritonitis. His blood profiles were normal, and an erect chest radiograph showed no evidence of free air under the diaphragm. An ultrasound scan of the abdomen revealed pericholecystic fluid (11 mm diameter). Laparotomy revealed an isolated perforation of the gallbladder at the infundibulum with a localised bile collection in the sub-hepatic space (Fig 1). There was no evidence of duodenal, liver or biliary tract injury. A retrograde cholecystectomy was done in view of inflammation and bile staining at Calot's triangle. The postoperative course was uneventful.

Discussion

Isolated gallbladder perforation from BAT is rare, because this organ is protected by the liver and rib cage. It accounts for 1.5%

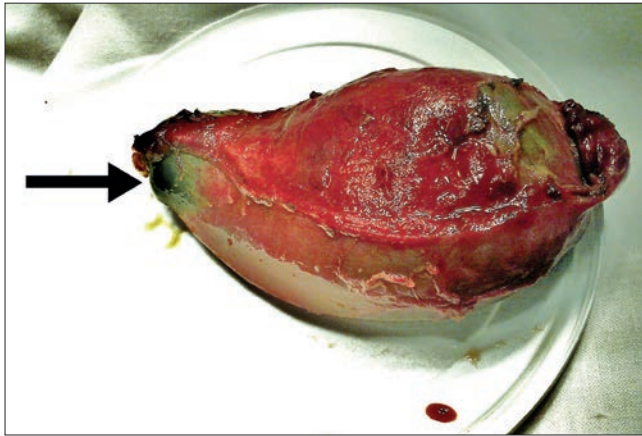


Fig. 1. Cholecystectomy specimen showing perforation at the infundibulum (arrow).

of injuries found at laparotomy for BAT.^[2] The spectrum of injury includes contusion of the gallbladder wall, perforation and avulsion from the liver bed. The pathophysiology includes a high-impact injury combined with associated risk factors such as a thin gallbladder wall, distended gallbladder and high biliary tract pressures due to sphincter of Oddi spasm from alcohol use. The fundus is the most frequent site of perforation. Combined injuries involving the duodenum, liver and spleen are common.^[3]

Patients often present with RUQ tenderness only, and an early clinical diagnosis is difficult to establish. The passage of sterile bile from an uninfected gallbladder causes minimal peritoneal irritation, often delaying the presentation. An abdominal ultrasound scan may show complex echogenic pericholecystic fluid collection, a thickened, hypoechoic, oedematous gallbladder wall, a collapsed gallbladder lumen despite prolonged fasting, and disruption of the gallbladder wall with focal loss of its reflectivity.^[4] An abdominal computed tomography (CT) scan is most accurate in the diagnosis of gallbladder injury. Blood in the gallbladder most reliably presents as high-density fluid

within the gallbladder lumen. Other CT findings suggestive of gallbladder injury include thickening or indistinctness of the gallbladder wall and active arterial extravasation into the lumen. Complete avulsion of the gallbladder results in displacement of the gallbladder from its fossa. Pericholecystic fluid and collapsed gallbladder lumen are less specific indicators of gallbladder trauma.^[5]

The recommended treatment for gallbladder perforation is a total cholecystectomy, but a retrograde subtotal cholecystectomy may be required if the gallbladder is very friable.^[3] Although laparoscopy is used for diagnostic purposes in haemodynamically stable patients with BAT, gallbladder contusion/laceration and partial avulsion can be managed safely by laparoscopic cholecystectomy.^[6]

Conclusion

Isolated gallbladder trauma from BAT poses a diagnostic challenge and may result in delays in instituting appropriate management. Ultrasound and a CT scan of the abdomen will detect the injury readily in cases of diagnostic doubt. Exploratory laparotomy with cholecystectomy is the treatment of choice. The role of diagnostic laparoscopy and laparoscopic cholecystectomy remains investigational.

REFERENCES

1. Cheddie S, Muckart DJJ, Hardcastle TC, et al. Direct admission versus inter-hospital transfer to a level I trauma unit improves survival: An audit of the new Inkosi Albert Luthuli Central Hospital trauma unit. *S Afr Med J* 2011;101(3):176-178. [http://doi:10.7196/SAMJ.4170]
2. Howes N, Walker T, Allorto NL, Oosthuizen GV, Clarke DL. Laparotomy for blunt abdominal trauma in a civilian trauma service. *S Afr J Surg* 2012;50(3):30-32. [http://dx.doi.org/10.7196/SAJS.998]
3. Sharma O. Blunt gall bladder injuries: Presentation of twenty-two cases with review of the literature. *J Trauma* 1995;39(3):576-580. [http://dx.doi.org/10.1097/00005373-199509000-00029]
4. Kao EY, Desser TS, Brooke Jeffrey R. Sonographic diagnosis of traumatic gallbladder rupture. *J Ultrasound Med* 2002;21(11):1295-1297. [http://dx.doi.org/10.1016/s0020-1383(85)80008-5]
5. Wittenberg A, Minotti AJ. CT diagnosis of traumatic gallbladder rupture. *AJR Am J Roentgenol* 2005;185(6):1573-1574. [http://dx.doi.org/10.2214/AJR.04.1637]
6. Liess BD, Awad ZT, Eubanks WS. Laparoscopic cholecystectomy for isolated traumatic rupture of the gallbladder following blunt abdominal injury. *J Laparoendosc Adv Surg Tech A* 2006;16(6):623-625. [http://dx.doi.org/10.1089/lap.2006.16.623]