

Haemangiopericytoma/solitary fibrous tumour of the greater omentum

J H R Becker,¹ MB ChB, MMed (Surg), FCS (SA), FRCS (Edin and Glasg); M Z Koto,¹ MB ChB, FCS (SA); O Y Matsevych,¹ MD (UA); N M Bida,² MB ChB, MMed (Path), FFPPath (SA), MRCPath, MBA, MPH, Cert Mol Biol

¹ Department of Surgery, Faculty of Health Sciences, School of Medicine, University of Limpopo (Medunsa Campus), Pretoria, South Africa

² Department of Histopathology, Faculty of Health Sciences, School of Medicine, University of Limpopo (Medunsa Campus), Pretoria, South Africa

Corresponding author: J H R Becker (jhr.becker@telkomsa.net, hennie.becker@ul.ac.za)

We report a rare case of haemangiopericytoma/solitary fibrous tumour of the greater omentum in a 41-year-old woman. It presented as a large mobile abdominal mass measuring 30 × 24 × 8 cm. A computed tomography scan confirmed the presence of a large vascular tumour, and biochemical tumour markers were non-contributory. The tumour was removed through a conventional laparotomy incision with the aid of a Ligasure dissector. There were no macroscopic metastases, and histologically it was benign. The size of >5 cm, however, suggests that it may have been malignant. In the absence of visible metastases and in view of the favourable histological features, it was decided to follow up the patient very closely and give further treatment if necessary.

S Afr J Surg 2014;52(4):111-113. DOI:10.7196/SAJS.2274



Haemangiopericytoma is a very rare tumour of the Zimmermann pericyte.^[1,2] A pericyte is a cell found in the wall of capillaries, originally described by Stout and Murray.^[1] Pericytes have a contractile function that helps to regulate blood flow in the capillaries. They appear anywhere in the body, although tumours affecting them occur predominantly in the lower extremities, pelvic fossa and retroperitoneum.^[2] This may be because pericytes in the lower half of the body are functionally more active against gravity in the control of blood flow. Haemangiopericytoma of the greater omentum is a rarely documented tumour, with only 12 cases reported until 2003.^[2-11] We could find no cases reported after that year, and the case presented here may be the 13th. A tumour size >5 cm and mitotic index >4/high-power field are strongly suggestive of malignancy, and adjuvant chemotherapy should be considered.

Case report

A 41-year-old woman was admitted to George Mukhari Academic Hospital, Limpopo Province, South Africa, with complaints of a distended abdomen, early satiety and episodic postprandial vomiting. She had noted gradual enlargement of her abdomen over the past 3 years, attributing it to her 'recent pregnancy'. The pregnancy had turned out to be a molar pregnancy, and an intra-abdominal mass had also been present. The molar pregnancy was successfully treated with uterine evacuation, but the patient had not attended for further investigation of the intra-abdominal mass.

On general examination the patient appeared healthy. Abdominal examination revealed a non-tender, nodular, very mobile (from side to side and up and down) mass filling the

entire abdominal cavity. She had normocytic, normochromic anaemia, with a haemoglobin concentration of 7.6 g/dL. Other laboratory results were normal, including beta-human chorionic gonadotrophin, carcinoembryonic antigen, carbohydrate antigen 19.9 and alpha-fetoprotein. An abdominal contrast-enhanced computed tomography (CT) scan showed a large abdominopelvic vascular heterogeneous mass with multiple cystic and necrotic areas (Figs 1 and 2). The origin of the mass could not be established on the CT scan. At laparotomy via a midline incision

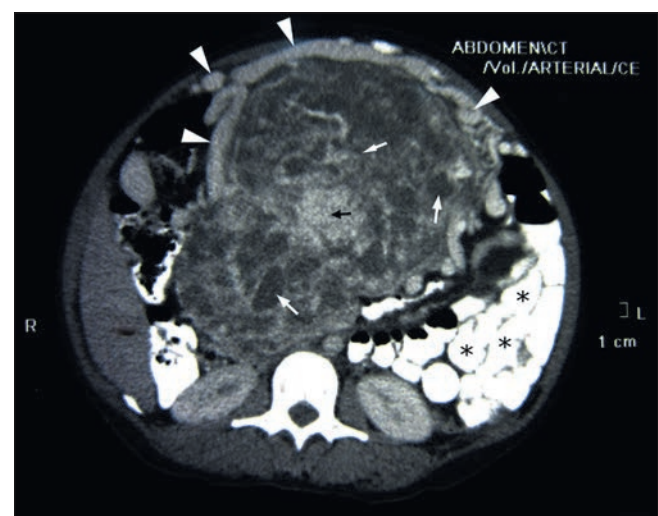


Fig. 1. Computed tomography scan. Axial cuts of the abdominal tumour demonstrate large surface arteries (arrow heads) and huge vascular (black arrow) and cystic spaces (white arrows) in the tumour. Small bowel is displaced to the left inferior part of the abdominal cavity (asterisks).

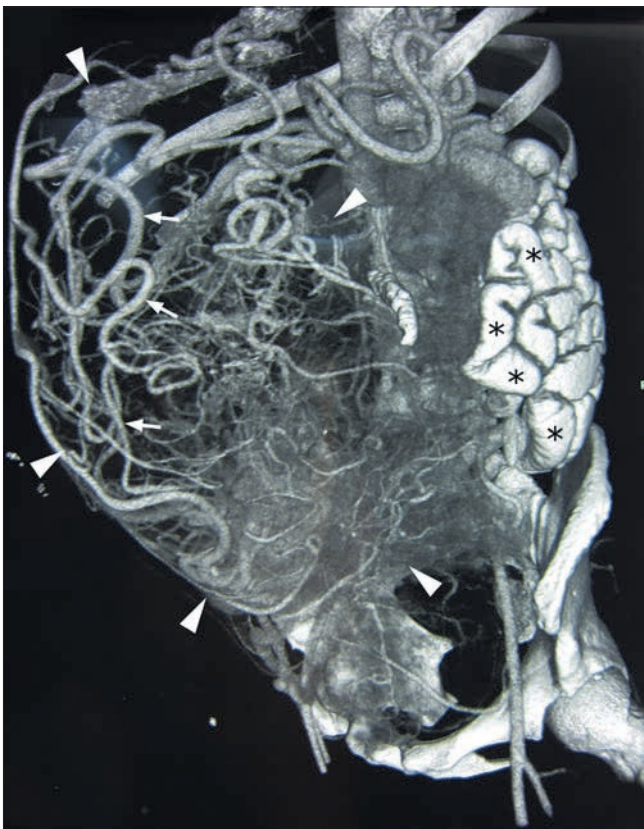


Fig. 2. Large vascular tumour filling the entire abdomen (arrow heads), large blood vessels (arrows), and posteriorly displaced bowel (asterisks).

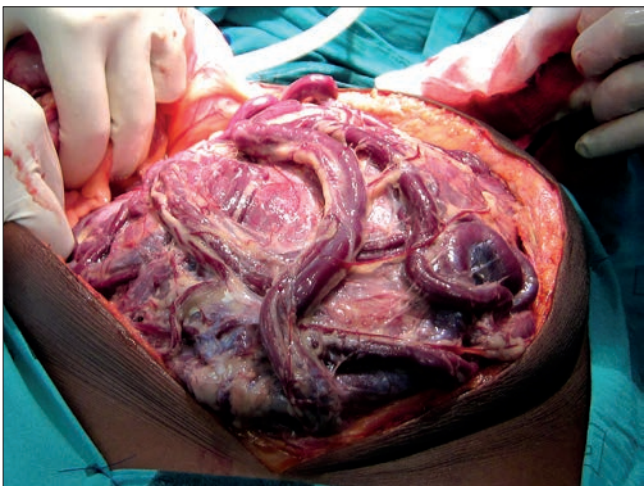


Fig. 3. Large surface blood vessels on the tumour.

a large, lobular, very vascular mobile mass was found (Fig. 3). It originated from the omentum with attachments to the mesentery of the small bowel and the right lobe of the liver. On the surface of the mass there were multiple grossly enlarged (1 - 2 cm diameter) pulsating arteries and veins, originating from the right gastroepiploic artery and vein and spreading into the gastrocolonic ligament (Fig. 3). The mass was completely removed and the patient made an uneventful recovery. Use of a Ligasure (Fig. 4) for the dissection made it possible to remove the entire tumour with minimum blood loss in a short time; the conventional 'clip and tie'

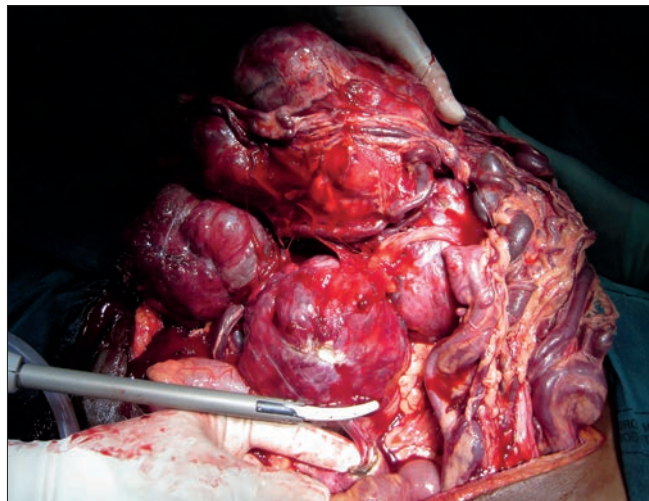


Fig. 4. Ligasure facilitating the dissection.

would have taken much longer and resulted in more blood loss in an already anaemic patient.

The surgical specimen was examined and sections were taken for paraffin embedding, as well as processing using the standard haematoxylin and eosin method.

Macroscopic findings

A soft-tissue mass measuring 30 × 24 × 8 cm was attached to the omentum. On the cut surface the mass was soft and haemorrhagic with no areas of necrosis. Cystic spaces containing yellowish fluid alternated with solid areas. Representative sections were taken from the soft-tissue mass.

Microscopic findings

Many sections were examined and showed solid proliferation of oval to spindle-shaped cells, interspersed by staghorn-type vascular spaces, lined by endothelial cells. No mitosis was present and nuclear atypia was not observed. There were no foci of tumour necrosis.

Sections prepared by the silver impregnation technique showed pericellular deposition of reticulin coarse fibre.

Immunohistochemical examination showed strong positive immunostaining with vimentin as well as bcl-2 (Figs 5 and 6). CD 34 was confined to the endothelium lining the vessels.

Discussion

Haemangiopericytoma arising from the omentum is extremely rare.^[2-11] The primary treatment is surgery, and an R0 excision is preferable. The role of adjuvant chemotherapy or targeted therapy is not well established when there are no demonstrable metastases, in contiguity, lymphatic or haematogenous.

Malignancy can be expected when the tumour is larger than 5 cm, has a high mitotic index and has areas of necrosis. The tumour in our case measured 30 × 24 × 8 cm, but no mitosis or areas of necrosis were found on histological examination; there were also no demonstrable metastases and no residual tumour after removal. We decided not to give the patient any further adjuvant therapy until local or systemic signs of recurrence can

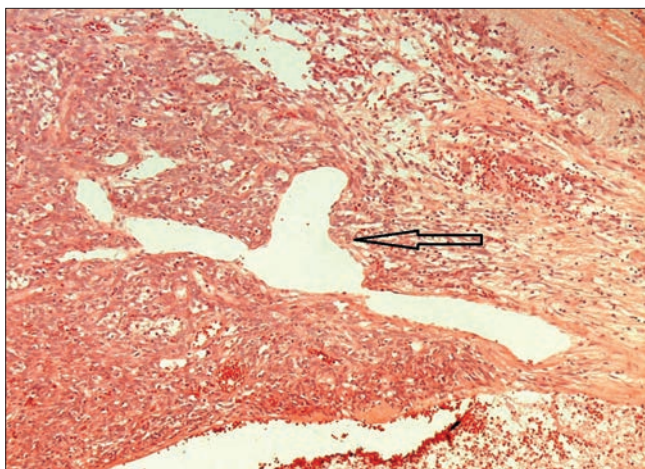


Fig. 5. Photomicrograph of a histological section of the tumour (H&E \times 20), illustrating staghorn-type vessels (arrow).

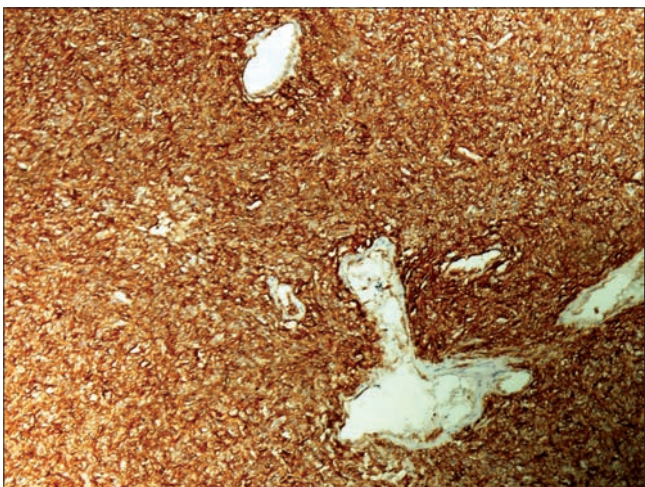


Fig. 6. Photomicrograph of a bcl-2 immunostained section illustrating strongly positive immunoreactivity (\times 20).

be demonstrated. She will be followed up regularly at the surgical outpatient department, where she will be assessed clinically as well as by abdominal ultrasound. CT and magnetic resonance imaging scans will be done if there is any suspicion of recurrence.

Haemangiopericytoma is characterised microscopically by a solid proliferation of oval to spindle-shaped cells that appear cytologically bland, often with vascular arcades interspersed. In some areas, typical staghorn architecture of thin-walled branching vessels is observed. The tumour may exhibit variable degrees of cellularity, and in more cellular areas vessels therefore tend to be small and collapsed and can only be highlighted by reticulin stains. A few cases of aggressive behaviour and even distant metastases have been described.^[12-13]

Microscopic criteria often used to predict biological behaviour in primary tumours include the degree of cellularity, the degree of nuclear atypia and the presence of tumour necrosis.^[12-13] The presence of distant metastases is unequivocal evidence of malignancy.

Our patient's tumour had huge veins and arteries (1 - 2 cm in diameter) (Figs 3 and 4) on the surface, and large vascular spaces

deeper in the parenchyma (Figs 1 and 2). There is a possibility that microangiopathic haemolysis of red blood cells had taken place.^[14] The anaemia could be explained by breakdown of red blood cells, as is found in giant haemangiomas. The platelets were normal, and the patient had no stigmata of a consumption coagulopathy as is found in Kasabach-Merritt syndrome.

It is currently considered that the term haemangiopericytoma should be reserved for neuropathologists, and the term solitary fibrous tumour rather than haemangiopericytoma should be favoured by soft-tissue pathologists. The reason for this change in nomenclature is because the staghorn-branching vascular pattern representative of haemangiopericytoma is found in 15% of all soft-tissue tumours. According to soft-tissue pathologists, the term solid fibrous tumour better describes a rare heterogeneous group of benign and malignant neoplasms along a morphological continuum.^[13,15,16]

Conclusion

We report a case of haemangiopericytoma/solitary fibrous tumour of the omentum. This very rare tumour was treated successfully with complete surgical removal. On histological examination it appeared to be benign, except that the size favours malignancy, tumours larger than 5 cm being considered malignant. Our patient had no demonstrable metastases, so it was decided not to provide any adjuvant therapy. She will be closely followed up and investigated for recurrence, local or systemic, the final arbiter for malignancy.

REFERENCES

1. Stout AP, Murray MR. Hemangiopericytoma: A vascular tumor featuring Zimmerman's pericytes. *Ann Surg* 1942;116(1):26-33.
2. Shiba H, Misawa T, Kobayashi S, Yokota T, Son K, Yanaga K. Hemangiopericytoma of the greater omentum. *J Gastrointest Surg* 2007;11(4):549-551. [<http://dx.doi.org/10.1007/s11605-007-0099-x>]
3. Stout AP, Hendry J, Purdie FJ. Primary solid tumors of the greater omentum. *Cancer* 1963;16:231-233.
4. Goldberger RE, Schein CJ. Hemangiopericytoma of the omentum: Report of a case with a unique presentation and review of the literature. *Am Surg* 1968;34(4):291-295.
5. Imachi M, Tsukamoto N, Tsukimori K, et al. Malignant hemangiopericytoma of the omentum presenting as an ovarian tumor. *Gynecol Oncol* 1990;39(2):208-213. [[http://dx.doi.org/10.1016/0090-8258\(90\)90434-M](http://dx.doi.org/10.1016/0090-8258(90)90434-M)]
6. Schwartz RW, Reames M, McGrath PC, Letton RW, Appleby G, Kenady DE. Primary solid neoplasms of the greater omentum. *Surgery* 1991;109(4):543-549.
7. Cajano P, Heys SD, Eremin O. Hemangiopericytoma of the greater omentum. *Eur J Surg Oncol* 1995;21(3):323-324. [[http://dx.doi.org/10.1016/50748-7983\(95\)91888-4](http://dx.doi.org/10.1016/50748-7983(95)91888-4)]
8. Bertelotto M, Cittadini G Jr, Crespi G, Perrone C, Pastorino R. Hemangiopericytoma of the greater omentum: US and CT appearance. *Eur Radiol* 1996;6(4):454-456.
9. Rao SR, Rao RS, Sampat MB. Hemangiopericytoma of the greater omentum. *Indian J Gastroenterol* 2000;19(1):33-35.
10. Kaneko K, Shirai Y, Wakai T, Hasegawa G, Kaneko I, Hatakeyama K. Hemangiopericytoma arising in the greater omentum: Report of a case. *Surg Today* 2003;33(9):722-724. [<http://dx.doi.org/10.1007/s00595-003-2559-6>]
11. Bovino A, Basso L, Giacomo GD, Pisanelli MC, Basile U, Toma D. Hemangiopericytoma of the greater omentum: A rare cause of acute abdominal pain. *J Exp Clin Cancer Res* 2003;22(4):649-650.
12. Vincent Y. Solitary fibrous tumor. January 2013. <http://medicine.medscape.com/article/1255879-overview> (accessed 15 April 2014).
13. Penel N, Amela EY, Decanter G, Robin YM, Marec-Berard P. Solitary fibrous tumors and so called hemangiopericytoma. *Sarcoma* 2012 (2012), Article ID 690251. [<http://dx.doi.org/10.1155/2012/690251>]
14. Kempson RL, Fletcher CDM, Evand HL, Hendrickson MR, Sibley RK. *Atlas of Tumor Pathology: Tumors of the Soft Tissues*. Washington, DC: Armed Forces Institute of Pathology, 1998:371-377.
15. Prop RP, Scharfman WB. Hemangioma-thrombocytopenia syndrome associated with microangiopathic hemolytic anemia. *Blood* 1966;28(5):623-633.
16. McMenamin ME, Fletcher CD. Malignant myopericytoma: Expanding the spectrum of tumours with myopericytic differentiation. *Histopathology* 2002;41(5):450-460. [<http://dx.doi.org/10.1046/j.1365-2559.2002.01537.x>]