

Percutaneous thrombin injection for pseudoaneurysm treatment

G Bydawell

Lake, Smit & Partners, Durban
G Bydawell, MB ChB, FRCR

Corresponding author: G Bydawell (bydawell@lakesmit.co.za)

Pseudoaneurysm of the femoral artery is a well-documented complication following arterial access. There are several treatment options, but percutaneous injection of thrombin, using ultrasound guidance, has become increasingly popular worldwide and is the therapy of choice in most vascular centres. This short review highlights the procedure and provides step-by-step guidance for radiologists who are interested in performing thrombin injection.

S Afr J Rad 2013;17(1):41-42. DOI:10.7196/SAJR.792

Pseudoaneurysm of the common femoral artery (CFA) is a well-recognised complication following angiography.^[1] Incidence rates of up to 0.2% of diagnostic angiograms and 8% of interventional procedures have been reported.^[2,3] The incidence increases with cardiac procedures owing to several factors, including longer procedure time, larger sheath sizes (7F and higher) and anti-platelet treatment.

The main treatment options for symptomatic pseudoaneurysms include ultrasound-guided compression, percutaneous thrombin injection or surgical repair. Ultrasound-guided compression is easy to perform and is often successful in thrombosing the aneurysm sac, but is very time-consuming and painful and has a high recurrence rate.^[4] Surgical closure is technically straightforward, but usually requires theatre time and general anaesthetic, and is not without complications such as wound infection or nerve damage.^[5]

In the last decade, percutaneous thrombin injection has become the treatment of choice for iatrogenic femoral artery pseudoaneurysm.^[6,7] This was first described in 1986 by Cope *et al.*, but has gained increasing popularity in the last 2 decades.^[8] The technique is simple to perform for any practitioner with ultrasound intervention skills and is usually done in the ultrasound suite, or even at the patient's bedside, using a portable ultrasound unit. Procedural time normally does not exceed 15 minutes.

Technique

The first step is careful sonographic assessment of the pseudoaneurysm and the adjacent common femoral artery. Flow within the pseudoaneurysm sac has a typical 'yin-yang' sign. The neck is normally seen posteriorly and is usually thin and longitudinal. A large neck diameter (e.g. >10 mm) is a relative contra-indication for thrombin injection because of a slightly higher risk of distal embolisation.

There are several thrombin preparations available. In our centre, we use human thrombin from the Tisseel kit (Baxter US) where the thrombin powder is mixed with the calcium chloride solution and drawn up into a 1ml syringe. Next, the pseudoaneurysm sac is punctured under ultrasound guidance, using a thin-calibre needle (e.g. 21G). The tip of the needle is positioned in the anterior aspect of the sac, i.e. as far away from the neck as possible. Thrombin is

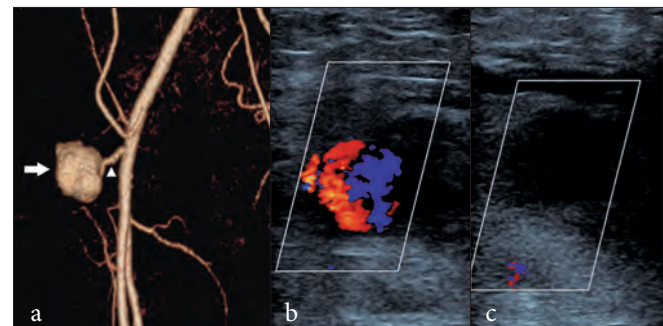


Fig. 1. A pseudoaneurysm (closed arrow), with a thin longitudinal neck (arrowhead), is seen adjacent to the common femoral artery and is well depicted on (a) 3D reformatted CT. Note the typical yin-yang sign indicating turbulent flow on (b) ultrasound doppler evaluation. This aneurysm was treated successfully with thrombin injection with complete haemostasis on follow-up ultrasound evaluation, as noted by (c) the lack of duplex Doppler signal.

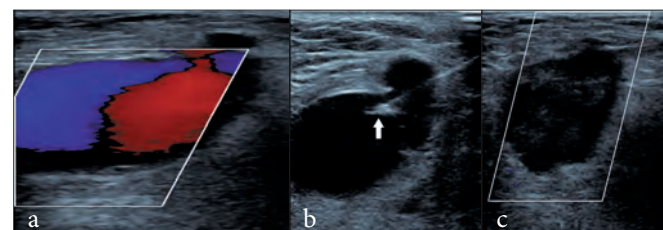


Fig. 2. A larger pseudoaneurysm is confirmed on ultrasound (a). Percutaneous thrombin injection was performed. (b) Tip of the needle (closed arrow) positioned superficially within the aneurysm sac. (c) Complete haemostasis.

then carefully injected in 0.1 ml increments using continuous B mode ultrasound imaging. Thrombus will begin to form around the tip of the needle within a few seconds, and then the remainder of the sac should progressively thrombose. Usually between 0.1 and 0.3 ml is adequate to achieve haemostasis.

Thereafter the native CFA is assessed with Doppler ultrasound to confirm patency and the patient is returned to the ward for observations

RADIOLOGICAL TIPS

and 4 - 6 hours bed rest. An ultrasound scan should ideally be performed the following day to confirm haemostasis.

Most recent studies report success rates between 95 and 100%.^[3] On rare occasions, a repeat injection is necessary. Complications are rare, estimated between 0 and 4%, and include distal embolisation, allergic reaction and infection. Regarding thromboembolic complications, it is estimated that small thrombi enter the native arterial circulation in approximately 2% of cases although the vast majority of these patients remain asymptomatic, and it is accepted that most of the thrombus is lysed by the natural circulating lytic agents.^[3]

Conclusion

The incidence of arterial access site complication is likely to increase in this era of minimal access intervention. Percutaneous thrombin injection is a simple, safe and effective technique for managing femoral pseudoaneurysms. The procedure is evidenced-based and is endorsed by large regulatory bodies such as the National Institute for Clinical Excellence (NICE) in the UK.^[9] There is a short learning curve, and the risks associated with the procedure are very low, with recent prospective studies showing no significant complications.^[10]

Radiologists need to be aware of the various management options for this condition and, with the benefit of image-guidance skills, are encouraged to familiarise themselves with the technique of thrombin injection.

1. Katzenschlager R, Ugurluoglu A, Ahmadi A, et al. Incidence of pseudoaneurysm after diagnostic and therapeutic angiography. *Radiology* 1995;195:463-466.
2. Messina LM, Brothers TE, Wakefield TW, et al. Clinical characteristics and surgical management of vascular complications in patients undergoing cardiac catheterization: Interventional vs diagnostic procedures. *J VascSurg* 1991;13:593-600.
3. Morgan R, Belli AM. Current treatment methods for postcatheterization pseudoaneurysms. *J VascRadiol* 2003;14:697-710. [<http://dx.doi.org/10.1097/01.RVI.0000071089.76348.6A>]
4. Eisenberg L, Paulson EK, Kliewer MA, et al. Sonographically guided compression repair of pseudoaneurysms: further experience from a single institution. *Am J Roentgenol* 1999;173:1567-1573.
5. Lumsden AB, Miller JM, Kosinski AS, et al. A prospective evaluation of surgically treated groin complications following percutaneous cardiac procedures. *Am Surg* 1994;60:132-137.
6. Paulson EK, Sheafar DH, Kliewer MA, et al. Treatment of iatrogenic femoral arterial pseudoaneurysms: comparison of US-guided thrombin injection with compression repair. *Radiology* 2000;215:403-408.
7. Brophy DP, Sheiman RG, Amatulle P, et al. Iatrogenic femoral pseudoaneurysms: Thrombin injection after failed US-guided compression. *Radiology* 2000;214:278-282.
8. Cope C, Zeit R. Coagulation of aneurysms by direct percutaneous thrombin injection. *Am J Roentgenol* 1986;147:383-387.
9. IPG060 Thrombin Injections for Pseudoaneurysm Guidance May 2004. London: National Institute for Health and Clinical Excellence, 2004.
10. Schneider C, Malisius R, Kuchler R, et al. A prospective study on ultrasound-guided percutaneous thrombin injection for treatment of iatrogenic post-catheterisation femoral pseudoaneurysms. *Int J Cardiol* 2009;131(3):356-361. [<http://dx.doi.org/10.1016/j.ijcard.2007.10.052>]