

## Conclusion

Among other causes dysphagia can be caused by a rare anomaly of the SA. The workup of a patient with dysphagia should always include barium swallow which will show a distinct concavity in the thoracic oesophagus,<sup>2</sup> and chest X-ray which may reveal a

right-sided aortic arch. Computed tomography can be used to diagnose anomalies of the aortic arch. Arch aortography is very important in diagnosing the anomalies of the arch.

## References

1. Bayford D. Account of a single case of obstructed deglutition. *Mem Med Society* 1794; 2: 275-285.
2. Morris CD, Kanter KR, Miller JJ. Late-onset dysphagia lusoria. *Ann Thorac Surg* 2001; 71: 710-712.
3. Janssen M, Baggen MGA, Veen HF, Jonkman JGJ, Ouwendijk RJ. The arteria lusoria: clinical findings, diagnostics and therapy. *Neth J Med* 1996; 48: A51-A100.
4. Drucker MH, Symbas PN. Right aortic arch with aberrant left subclavian artery: symptomatic in adulthood. *Am J Surg* 1980; 139: 432-434.
5. Keiffer E, Bahni A, Koskas E. Aberrant subclavian artery: surgical treatment in thirty three adult patients. *J Vasc Surg* 1994; 19: 100-111.

# A case of atypical meningioma

**M A Mabiletsa**

BSc, MB ChB

**L D R Tsatsi**

MB ChB, FCRad (D) SA

Department of Diagnostic Radiology  
Medical University of Southern Africa

## Introduction

A 35-year-old female patient presented with a first episode of generalised convulsion and confusion. She also reported weakness in both lower limbs and urinary incontinence. On examination she was found to have a hard, immobile elliptical non-tender midline mass on the forehead. She also had weakness of the lower limbs. The cranial nerves were intact.

Skull X-ray showed an expansile lobulated, lytic lesion in the frontal bone in the midline, above the orbital

roofs, which were not involved (Fig. 1). There was destruction of the inner table. An associated hyperostosis of the mid-frontal bone below the lesion was noted. At this point, the differential diagnosis was a primary aggressive bone lesion with intracranial extension. Axial computed tomography (CT) scans demonstrated a large well-defined lobulated extra-axial mass in the frontal lobe, extending on both sides of the falx. It

was abutting the frontal bone at an obtuse angle. It measured 7.0 × 8.0 × 5.6 cm in diameter. The lesion was isodense to grey matter with multiple areas of calcification. There was intense and inhomogeneous enhancement with areas of rim enhancement (Figs 2 and 3). The erosion of adjacent frontal bone and hyperostosis were confirmed. There was moderate

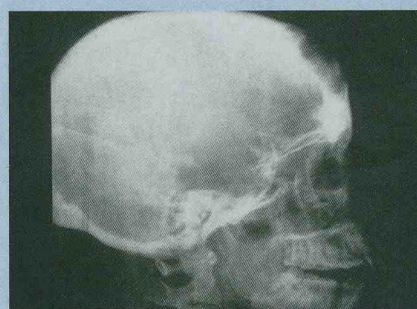


Fig. 1. Lateral skull X-ray showing a lytic lesion in the frontal bone.

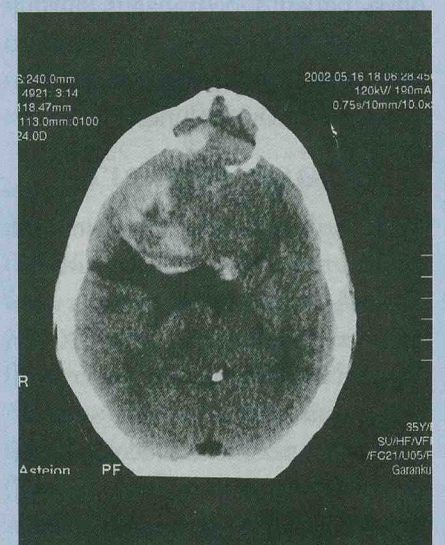


Fig. 2. Axial CT scan, non-contrast, showing a tumour in the midfrontal lobe with calcifications, and moderate oedema and bone erosion.

peritumoral oedema and minimal mass effect on the right lateral ventricle, the anterior cerebral and right middle hydrocephalus. Differential diagnoses of typical meningioma and dural metastases with bone involvement were made. An angiogram was done to exclude involvement of the venous sinuses and also to assess the blood supply. It showed a dual blood supply by both the left internal (Fig. 4) and external carotid arteries and the right internal carotid (Fig. 5). A persistent tumour blush into the venous phase was also noted and there was also displacement of the anterior cerebral arteries to the left side (Fig. 5).

The patient was operated on and the tumour was resected. A histological diagnosis of syncytial meningioma was made.

## Discussion

Meningiomas are the most common primary non-glial brain tumours and comprise 13 - 19% of all primary intracranial neoplasms. Most meningiomas are benign but 6% are atypical or aggressive and 1 - 2% are frankly

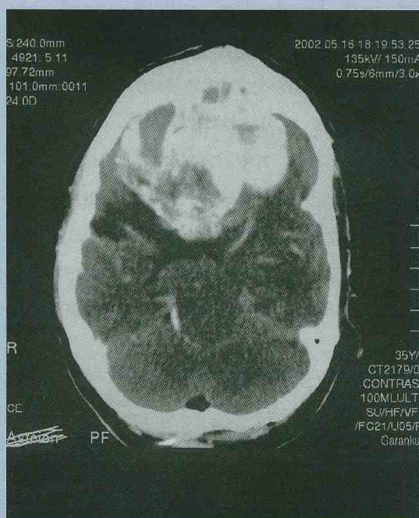


Fig. 3. Axial CT scan, post-contrast, showing inhomogeneous enhancement of the tumour.

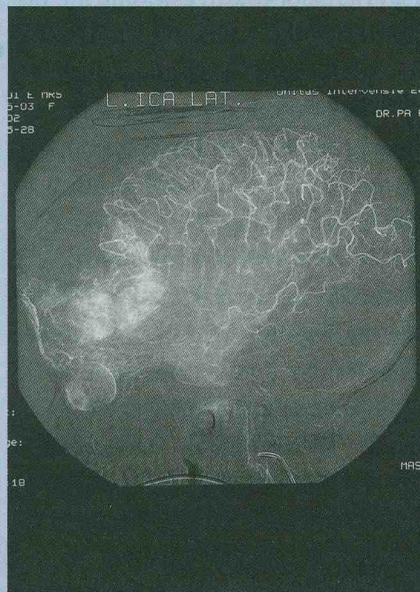


Fig. 4. Angiogram of the left internal carotid artery. Lateral view, late arterial phase showing an intense tumour blush anteriorly.

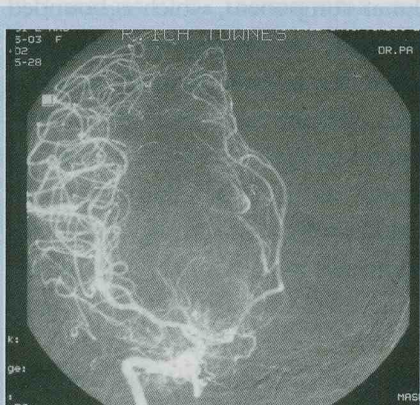


Fig. 5. Right internal carotid artery, Towne's view, showing displacement of anterior cerebral arteries to the left.

malignant. Meningiomas arise from arachnoid cap cells that line the inner dura but may arise anywhere that these cells are located. Convexity meningiomas, overlying the lateral portion of the cerebral hemisphere, form the majority. Other sites are parasagittal, sphenoid wing, juxtasegellar frontobasal and posterior fossa. Less typical sites include the optic nerve sheath and intraventricular. Ten per cent arise in the spine. Very rarely,

meningiomas also arise wholly outside the craniospinal axis, in the ear and temporal bone, mandible, foot, mediastinum or lung. Most meningiomas are sporadic and of unknown aetiology. Recognised risk factors include genetic factors (e.g. neurofibromatosis type 2, in which the tumours may be multiple and en plaque) and cranial irradiation. Meningiomas occur most often in individuals between 40 and 60 years of age, and affect women more than men. The clinical symptoms are related to the mass effect on the adjacent structures and they depend greatly on size and location of the lesion. Meningiomas commonly present with seizures. Other symptoms include headaches, visual impairment, focal neurological deficits and confusion. The histological grading of meningiomas is based on the current World Health Organization (WHO) classification, which together with the extent of tumour resection, determines the likelihood of tumour recurrence.

The majority of meningiomas (80 - 90%) are benign and classified as WHO grade 1. Atypical meningiomas correspond to WHO grade 2 and they have a higher rate of recurrence than grade 1 tumours, particularly after subtotal resection. Anaplastic or malignant meningiomas (WHO grade 3) are the rarest (1 - 3%).

Plain X-ray of the skull may show hyperostosis; those tumours with a great deal of hyperostosis tend to recur infrequently. If a destructive and mixed bone reaction is seen then the tumour recurrence is more common. Our patient showed a mixed bone reaction, with both destruction and hyperostosis of adjacent bone, which is not typical in benign meningiomas.

Calcification of the tumour, blistering of the sphenoid sinus, and evidence of increased vascularity (enlarged meningeal vascular grooves and foramen spinosum) are other findings. On CT imaging meningiomas are well-defined extra-axial masses, which displace adjacent brain. Most are iso to slightly hyperdense compared with normal brain, and there is a strong uniform enhancement after intravenous contrast. There is usually minimal perifocal oedema. Calcifications and adjacent hyperostosis may be evident. Meningioma en plaque cloaks the inner table, resulting in pronounced hyperostosis of the adjacent bone. Magnetic resonance imaging (MRI) may show hypo to isointense signal lesions on T1-weighted imaging and iso to hyperintense on T2-weighted imaging with a strong homogeneous enhancement post gadolinium. Most meningiomas show a characteristic dural thickening that tapers peripherally (dural tail sign), accurately localising the tumour to the dural or subdural space. Angiography

plays a major role in assessing the vascularity of the tumours preoperatively. It can also demonstrate involvement of the adjacent venous sinuses. It gives rise to a 'spoke-wheel' appearance and a characteristic 'mother-in-law' phenomenon.

Atypical meningiomas have been found to occur commonly in parasagittal regions, followed by cerebral convexities. Peak incidence is in younger age groups than occurs with benign meningiomas. Meningiomas do not always follow the appearance outlined above. Atypical appearance includes a low attenuation area of necrosis/haemorrhage/cystic and fatty change, or non-homogeneous or ring-enhancing areas due to tumour infarction. A comma-shaped semilunar component, which is bounded by dura, with the spherical component free to grow beyond the dura, may also be seen. The latter correspond to WHO grade 2. The recurrence rate is higher than in benign meningiomas. Diagnostic criteria for atypical meningiomas are either

increased mitotic activity (4 or more mitotic figures per 10 high-power field) or at least 3 of the following features: increased cellularity, small cells with a high ratio of nucleus to cytoplasm, prominent nucleoli, sheet-like growth pattern and geographic necrosis.

## Acknowledgement

We would like to acknowledge Dr N Khan for helping with the final modifications.

## Bibliography

1. Joseph E, Sanhyamani S, Rao MB, Radhakrishnan VV. Atypical meningiomas — clinicopathological analysis. *Neurology India* 2000; **48**: 338-342.
2. Hunwitz RA. [www.neurorad.ucsf.edu/previous-cases/09012001.html](http://www.neurorad.ucsf.edu/previous-cases/09012001.html) (last accessed 06 June 2004.)
3. Hunwitz RA. [www.hopkinsmedicine.org/radiology/disorders/meningioma.cfm](http://www.hopkinsmedicine.org/radiology/disorders/meningioma.cfm) (last accessed 06 June 2004.)
4. Hunwitz RA. [www.medpharm.co.za/safp/2000/june2000/cranium/html](http://www.medpharm.co.za/safp/2000/june2000/cranium/html) (last accessed 06 June 2004.)
5. Whittle IR, Smith C, Navoo P, Colile D. Meningiomas seminar. *Lancet* 2004; **363**: 1535-1543.
6. Lamszus K. Meningioma. Pathology, genetics, and biology. *J Neuropathol Exp Neurol*; **63**: 275-286.