

# A case of dysphagia lusoria

**E Fynn**

MB ChB (GH), DCH (SA)

**N Z Makhanya**

MB ChB

Department of Diagnostic Radiology  
Medical University of Southern Africa

**L M Ntlhe**

MB ChB, FCS (SA)

Department of General Surgery  
Medical University of Southern Africa

## Introduction

Dysphagia lusoria is the result of oesophageal compression by a congenital vascular anomaly. The syndrome of oesophageal compression from an abnormal vascular structure was first described by Bayford in 1794.<sup>1</sup> He identified a misplaced right subclavian artery (SA) encroaching on a patient's oesophagus during autopsy. We report a case of an adult with late-onset dysphagia lusoria with complications in the lungs.

## Case report

A 56-year-old man was admitted to the hospital for peripheral vascular disease but developed dysphagia with aspiration pneumonia. Chest X-ray revealed right upper-lobe aspiration pneumonia and a barium swallow revealed a persistent indentation of the posterior oesophagus at the level of T4 (Fig. 1). Arch aortography demonstrated an aberrant right SA arising distal to the left subclavian and coursing behind the oesophagus toward the right (Fig. 2).

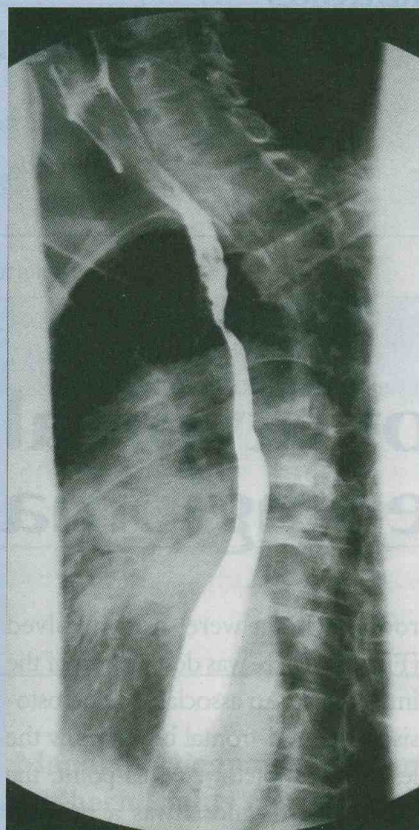


Fig. 1. A smooth extrinsic mass impresses on the posterior wall of the upper oesophagus.

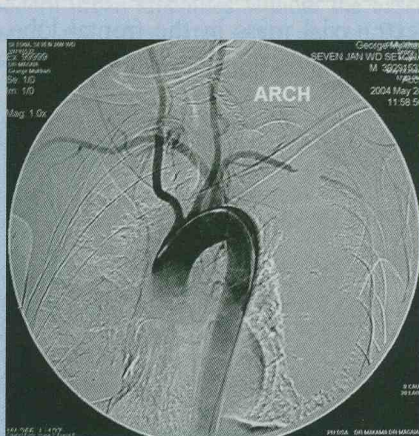


Fig. 2. Aortogram showing the aberrant right subclavian artery coursing posterior to the oesophagus.

## Discussion

An aberrant right SA is the most common non-aortic vascular lesion impressing on the oesophagus. The aberrant right SA arises just distal to the normal left SA and traverses obliquely to the right, posterior to the oesophagus. The impression is extramural and so typical of the abnormality.<sup>2</sup>

A barium contrast examination of the oesophagus shows a characteristic diagonal impression at the level of 4th thoracic vertebra.<sup>3</sup>

Dysphagia lusoria is present in 1 in 200 persons. Symptoms of dysphagia may occur at any age. Adults usually present with dysphagia and children more often present with respiratory symptoms. In adults, dysphagia starts after the 4th decade. Adult presentation of dysphagia lusoria is rare; 23 cases secondary to right-sided aortic arch and aberrant left SA have been reported.<sup>2,4</sup>

Keiffer *et al.*<sup>5</sup> classified four groups of patients with this vascular anomaly.

Group 1: Patients with dysphagia caused by non-aneurysmal aberrant SA.

Group 2: Patients with asymptomatic occlusive disease of non-aneurysmal aberrant SA.

Group 3: Patients with aneurysmal aberrant SA without aortic lesions, with or without oesophageal compression or arterial thromboembolism.

Group 4: Patients with an aortic (usually aneurysmal) lesion involving the origin of the aberrant SA aneurysm.

Our patient presented with adult late-onset dysphagia lusoria with complications typically seen in children. The patient underwent operative surgery and his symptoms were relieved.



## Conclusion

Among other causes dysphagia can be caused by a rare anomaly of the SA. The workup of a patient with dysphagia should always include barium swallow which will show a distinct concavity in the thoracic oesophagus,<sup>2</sup> and chest X-ray which may reveal a

right-sided aortic arch. Computed tomography can be used to diagnose anomalies of the aortic arch. Arch aortography is very important in diagnosing the anomalies of the arch.

## References

1. Bayford D. Account of a single case of obstructed deglutition. *Mem Med Society* 1794; 2: 275-285.
2. Morris CD, Kanter KR, Miller JJ. Late-onset dysphagia lusoria. *Ann Thorac Surg* 2001; 71: 710-712.
3. Janssen M, Baggen MGA, Veen HF, Jonkman JGJ, Ouwendijk RJ. The arteria lusoria: clinical findings, diagnostics and therapy. *Neth J Med* 1996; 48: A51-A100.
4. Drucker MH, Symbas PN. Right aortic arch with aberrant left subclavian artery: symptomatic in adulthood. *Am J Surg* 1980; 139: 432-434.
5. Keiffer E, Bahni A, Koskas E. Aberrant subclavian artery: surgical treatment in thirty three adult patients. *J Vasc Surg* 1994; 19: 100-111.

# A case of atypical meningioma

**M A Mabiletsa**

BSc, MB ChB

**L D R Tsatsi**

MB ChB, FCRad (D) SA

Department of Diagnostic Radiology  
Medical University of Southern Africa

## Introduction

A 35-year-old female patient presented with a first episode of generalised convulsion and confusion. She also reported weakness in both lower limbs and urinary incontinence. On examination she was found to have a hard, immobile elliptical non-tender midline mass on the forehead. She also had weakness of the lower limbs. The cranial nerves were intact.

Skull X-ray showed an expansile lobulated, lytic lesion in the frontal bone in the midline, above the orbital

roofs, which were not involved (Fig. 1). There was destruction of the inner table. An associated hyperostosis of the mid-frontal bone below the lesion was noted. At this point, the differential diagnosis was a primary aggressive bone lesion with intracranial extension. Axial computed tomography (CT) scans demonstrated a large well-defined lobulated extra-axial mass in the frontal lobe, extending on both sides of the falx. It

was abutting the frontal bone at an obtuse angle. It measured 7.0 × 8.0 × 5.6 cm in diameter. The lesion was isodense to grey matter with multiple areas of calcification. There was intense and inhomogeneous enhancement with areas of rim enhancement (Figs 2 and 3). The erosion of adjacent frontal bone and hyperostosis were confirmed. There was moderate

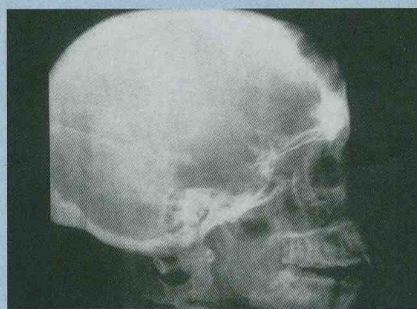


Fig. 1. Lateral skull X-ray showing a lytic lesion in the frontal bone.

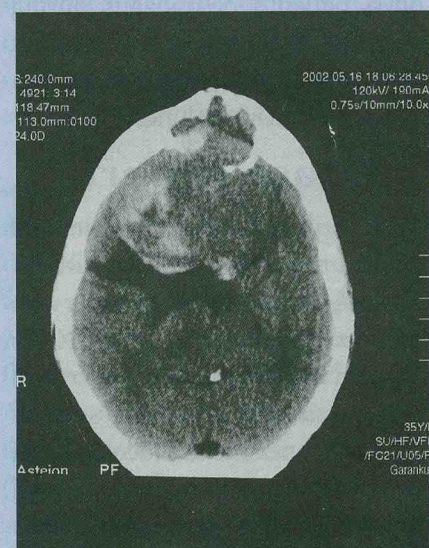


Fig. 2. Axial CT scan, non-contrast, showing a tumour in the midfrontal lobe with calcifications, and moderate oedema and bone erosion.