

# Diagnosis of chronic inflammatory bowel disease — a dilemma

**M E Kisansa**

*MB ChB, MMed Rad (D)*

*Department of Diagnostic Radiology  
Medical University of Southern Africa*

A 44-year-old black female patient presented with chronic bloody diarrhoea of 6 months duration. She had not responded to antibiotic treatment.

Previous medical history revealed that she had been treated for a non specific arthropathy 1 year prior to onset of the gastrointestinal (GIT) symptoms.

Clinical examination revealed the patient to be in a good general condition with no fever and no pallor. The cardiovascular and respiratory systems were within normal limits. The abdomen was soft with no tenderness elicited and no palpable masses. No skeletal abnormalities were reported.

Laboratory investigations showed a normal haemoglobin and erythrocyte sedimentation rate. The chest X-ray, urea and electrolytes were normal.

The liver function tests revealed elevated alkaline phosphatase (ALP), alanine aminotransferase (ALT) and gamma-glutamyltranspeptidase (GGT). HIV enzyme-linked immunosorbent assay and HIV antibody status were negative.

Gastroscopy was normal. The barium enema revealed involvement of

the ascending, transverse and descending colon and sigmoid colon with multiple fissural ulcers (Figs 1 and 2), pseudo diverticuli (Fig. 3) and loss of haustral pattern. The ascending colon showed areas of stricturing (Fig. 4). The sigmoid colon was relatively spared. Features of cobblestoning and fistula formation were not evident.

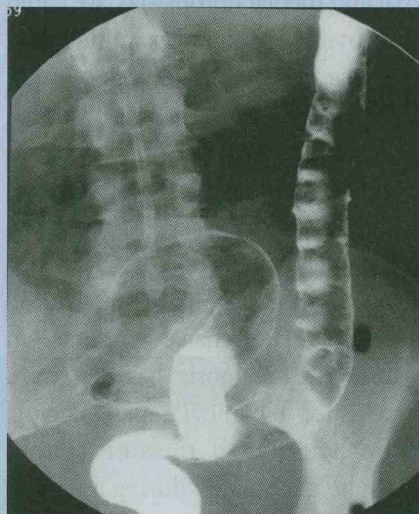


Fig. 1. Loss of haustration of the entire sigmoid and descending colon with superficial ulcers present in the descending colon.

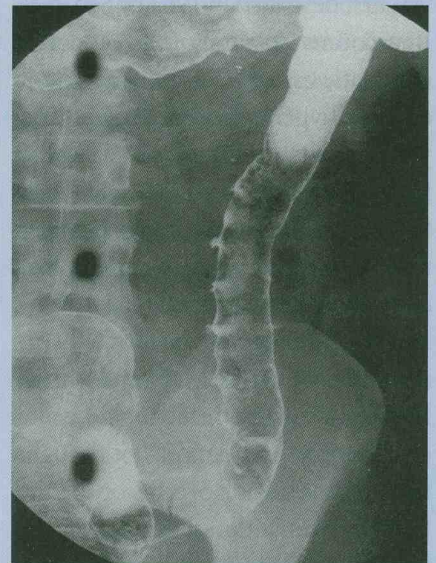


Fig. 2. Loss of haustration may be noted in the descending and sigmoid colon. Rose thorn ulcers are present. The mucosa of the bowel is of granular appearance.

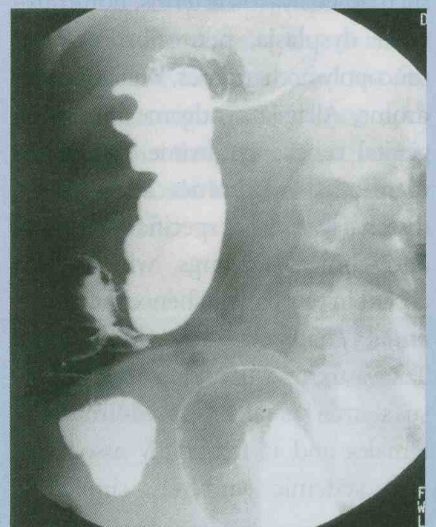

Fig. 3. Shortening of the ascending colon with areas of pseudo sacculation evident. Strictures of the proximal ascending colon are also seen.

Sigmoidoscopy showed inflamed congested mucosa of the rectum. The sigmoid colon was normal. The descending, transverse and ascending colon showed inflamed granular mucosa with widespread ulcerations. Multiple biopsies were taken. Biopsy results showed chronic nonspecific inflammation.

The patient improved rapidly on oral steroids.

## Discussion

It is difficult to make a precise diagnosis in a setup where the enema features are of a mixed pattern. These features give a mixed picture of

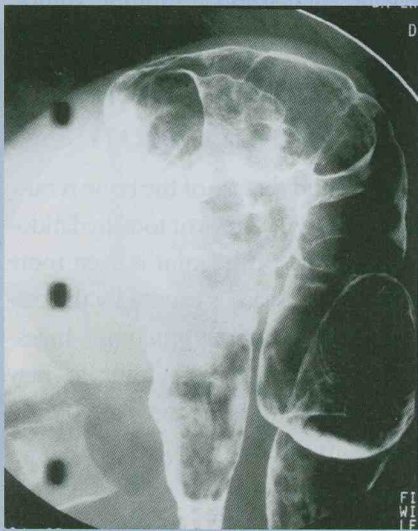


Fig. 4. Narrowing and shortening of the ascending colon.

Crohn's disease and ulcerative colitis, although findings on sigmoidoscopy showed features of the latter. Biopsy showed changes due to chronic inflammation.

Inflammatory bowel disease is difficult to diagnose due to the multiple aetiologies present in our environment.

## Crohn's disease

This inflammatory bowel disease rarely occurs in the black population. Crohn's disease is a chronic granulomatous inflammatory condition of unknown aetiology, involving the GIT. The disease is rare among patients of African descent although 4 cases have been reported from South Africa. Crohn's is common in patients of European and Jewish origin.<sup>1,2</sup>

In Crohn's disease biopsies reveal

changes similar to ulcerative colitis with lymphoid hyperplasia and non-caseating granulomas. Non-caseating granulomas can also be seen in a variety of other colonic diseases, e.g. tuberculosis, amoebiasis, schistosomiasis and fungal infections. The commonest regions of involvement are the terminal ileum and the colon. Gastric involvement is uncommon and oesophageal involvement is rare.<sup>2</sup>

Extensive jejunoileitis is common in young patients. Older patients tend to have localised regional ileitis. Ano-rectal disease occurs in older patients and runs a shorter course.<sup>3</sup>

There is a need for repeated diagnostic evaluation in these patients, with repeat biopsies for definite diagnosis.<sup>4</sup>

Other inflammatory bowel diseases common in South Africa are as follows.

**Ulcerative colitis.** This condition is more common than Crohn's disease in black patients. The barium enema findings are lead pipe colon, shortening, coarse granular mucosa, collar-button ulcers and inflammatory bowel polyps.<sup>5</sup>

**Tuberculosis.** Ulceration, with the long axis perpendicular to the axis of the intestine, undermining and bowel-wall thickening. Pseudo-polyps are uncommon.

**Schistosomiasis.** This disease is caused by the parasite *Schistosoma mansoni*. The GIT changes present are predominantly found in the rectum

with stricturing.<sup>6</sup>

**Amoebic colitis.** This is an acute infective colitis characterised by loss of haustral pattern with granular appearance, collar-button ulcers, cone-shaped caecum, amoebomas and thickened ileocaecal valve. Multiple stenoses are also seen.<sup>7</sup> Some of the features seen in our patient are similar to those found in amoebic colitis, although amoebic colitis is not commonly associated with arthropathies and usually runs an acute course.

From a clinical point of view, with a history of arthropathy as well as chronic diarrhoea and therapeutic response to steroids, one is inclined towards Crohn's disease and ulcerative colitis as the differential diagnosis in this patient.

## References

1. Chapman S, Nakielny R. *Aids to Radiological Differential Diagnosis*. 3rd ed. Edinburgh: WB Saunders, 1995: 530-531.
2. Goldman CD, Kodner JJ, Fry RD, MacDermott RP. Clinical and operative experience with non Caucasian patients with Crohns disease. *Dis Colon Rectum* 1986; **29**: 317-321.
3. Freeny PC, Stevenson GW. *Margulis and Burhenmes Alimentary Tract Radiology*. 5th ed. St Louis, Missouri: Mosby, 1994.
4. Kirsner JB. Problems in the differentiation of ulcerative colitis and Crohn's disease of the colon: The need for repeated diagnostic evaluations. *Gastroenterology* 1995; **68**: 187.
5. Grainger RG Allison DJ. *Diagnostic Radiology: an Anglo-American Textbook of Imaging*. 2nd ed. vol. 2. Edinburgh: Churchill Livingstone, 1992: 931.
6. Chapman S, Nakielny R. *Aids to Radiological Differential Diagnosis*. 3rd ed. Edinburgh: WB Saunders, 1995: 210-211.
7. Dahnert W. *Radiology Review Manual*. 3rd ed. Baltimore: Williams and Wilkins, 1996: 576-577.