

# Meningioma — a review of 52 cases

**E Fynn**

*MB ChB, DCH (SA)*

**N Khan**

*MB BS, FCRad (D) SA*

**A Ojo**

*MB ChB*

*Department of Diagnostic Radiology  
Medical University of Southern Africa*

## Abstract

Meningiomas are extra-axial neoplasms representing 15 - 20% of primary intracranial neoplasms. Incidence peaks in patients aged 40 - 60 years, and they more commonly affect women than men. Most meningiomas arise from arachnoidal cells on the inner surface of the dura and they therefore grow inward toward the brain to form bulky intradural tumour masses. Most meningiomas are benign, but ~6% are atypical or aggressive, and 1 - 2% are frankly malignant. Common locations for meningiomas include the cerebral convexity, parasagittal region, sphenoid wing, olfactory groove, tuberculum sellae, posterior fossa, and cavernous sinus.

## Introduction

Meningiomas are benign extra-axial tumours commonly seen in female patients. They form the bulk of

brain tumours seen in our hospital. In this study, we retrospectively examined the computed tomography (CT) images of meningiomas that were diagnosed and confirmed histologically and we assessed their epidemiological characteristics. This article reviews 52 cases of histologically proven meningiomas. The findings were compared with the literature.

## Patients and methods

We retrospectively reviewed the CT images of 52 meningioma cases diagnosed and confirmed histologically at George Mukhari Hospital between December 2001 and December 2003. CT imaging was performed using the Toshiba Asteion multislice CT scanner, Tokyo, Japan. Both pre- and post-contrast axial scans were done using 5 x 5 mm slices.

The CT images were analysed retrospectively. We examined the age and sex distribution as well as the location of the pathology in relation to the skull. Tumour locations were classified into eight groups: convexity, falx, parasellar, sphenoid ridge, clivus, middle cranial fossa, olfactory groove and optic nerve sheath meningioma.

## Radiological appearance

### Plain X-rays

Hyperostosis is one of the major features of meningioma on plain radi-

ographs. It indicates the site of attachment of the tumour to the meninges. Bone erosion and blistering of the sphenoid sinus, lytic skull lesions and calcification may be seen. Enlarged meningeal vascular grooves reflect dilatation of the meningeal arteries supplying the tumour and veins draining it. Calcification is seen in 20 - 25% of cases and can be diffuse or focal.

### Computed tomography

Plain and contrast-enhanced CT scans demonstrate most meningiomas. They are iso- to hyperdense on precontrast and demonstrate intense homogeneous enhancement with contrast. The tumour may have cystic components and calcification in some cases. Peritumoral oedema may be seen as well. Haemorrhage and intratumoral fluid-filled cysts may be seen.

### Magnetic resonance imaging

Most meningiomas are iso- or slightly hypointense to grey matter on T1-weighted studies and hyperintense to grey matter. T2-weighted images are variable. There is intense contrast enhancement after gadolinium administration. Perifocal hyperintensity due to oedema may be seen.<sup>1</sup>

### Angiography

Most meningiomas are vascular tumours and may give rise to a spoke-wheel appearance. Late arterial and capillary-phase films show a prominent, homogeneous prolonged vascular blush called the mother-in-law phenomenon — the contrast shows up early and stays late into the venous phase. En plaque meningiomas are depicted as an area of poor vascularity.<sup>1</sup>

## Results

### Prevalence, age and sex distribution

Of the 52 cases, 37 (71%) were female and 15 (29%) were male, with a mean age of 47 years (range 2 - 83 years) (Fig. 1). Two cases (4%) were considered to be childhood meningiomas.

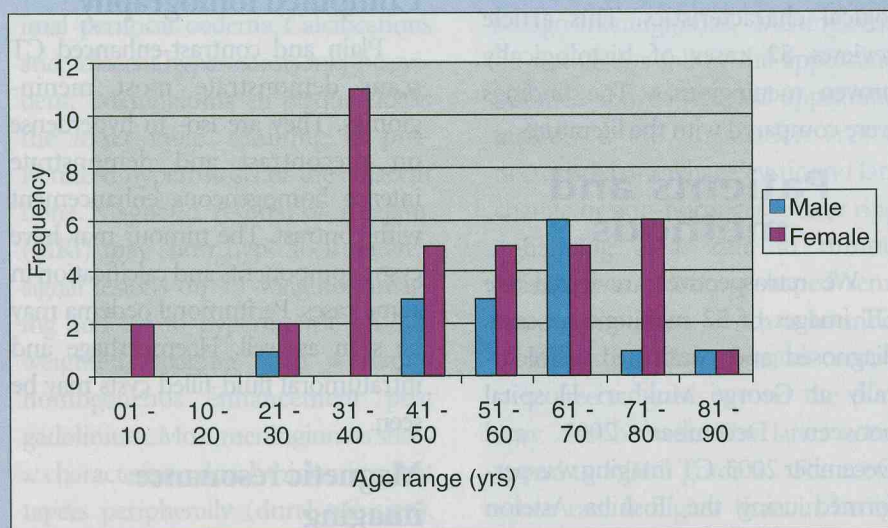


Fig. 1. Summary of age and gender distribution.

## Discussion

Meningiomas are slow-growing benign tumours composed of neoplastic meningothelial cells concentrated in the arachnoid villi which penetrate the dura. They are the most common extra-axial tumours and account for 15 - 18% of intracranial tumours in adults.

They are sometimes associated with type 2 neurofibromatosis. Ten per cent of patients with multiple meningiomas have type 2 neurofibromatosis.<sup>2</sup>

The epidemiology of meningioma can be studied in two ways; using

either hospital-based or community-based data. Community-based data are more accurate than hospital-based data which may be biased by referral patterns.<sup>3</sup> The annual incidence of meningiomas is quoted as 6 per 100 000 population of all central nervous system tumours.<sup>4</sup> An estimated 2 - 3% of the population have incidental asymptomatic meningiomas

and according to autopsy studies 8% of these are multiple.<sup>5</sup> In our series no multiple meningiomas were recorded.

### Age and gender

As in our series, the female preponderance of meningioma is confirmed in the literature.<sup>5,6</sup> Females are more vulnerable to the factors that predispose to meningioma formation such as sex hormones, trauma, and radiation therapy.<sup>7</sup> Meningiomas are twice as common in women as in men, and the incidence is highest after the fifth decade of life.<sup>2,4</sup> Childhood meningiomas are uncommon, but they have been well described in the

literature, with slight male predominance and lower frequency of dural attachments.<sup>4</sup> In a study of intracranial meningiomas Erdinçler *et al.*<sup>8</sup> reported 2.4% incidence out of 1200 paediatric brain tumours. Paediatric meningiomas are frequently associated with neurofibromatosis.

### Anatomical distribution

Meningiomas can arise from the dura at any site, most commonly from the skull vault, from the base (the planum sphenoidale, the sphenoid wing, the petrous ridge, the cavernous sinus and the parasellar region), and at sites of dural reflections (falx cerebri, tentorium cerebelli and the dura of the adjacent venous sinuses). Other less common intracranial sites of origin are the optic nerve sheaths and the choroid plexus (intraventricular meningioma). Very rarely, meningiomas arise wholly outside the craniospinal axis, in the ear and temporal lobe, mandible, foot, mediastinum and lung and skin.<sup>4</sup>

The convexity meningioma is the most frequent location of these tumours in adults.<sup>3</sup> This is not different from our findings. The majority of our cases were supratentorial. In a study by Rohringer *et al.*,<sup>3</sup> the majority of tumours were located on the cerebral convexity (Fig. 2).

## Conclusion

Meningiomas are common benign intracranial tumours seen in our hospital. Accurate diagnosis before treatment has been greatly facilitated by the availability of CT. Epidemiological characteristics are equally important in arriving at correct diagnosis.

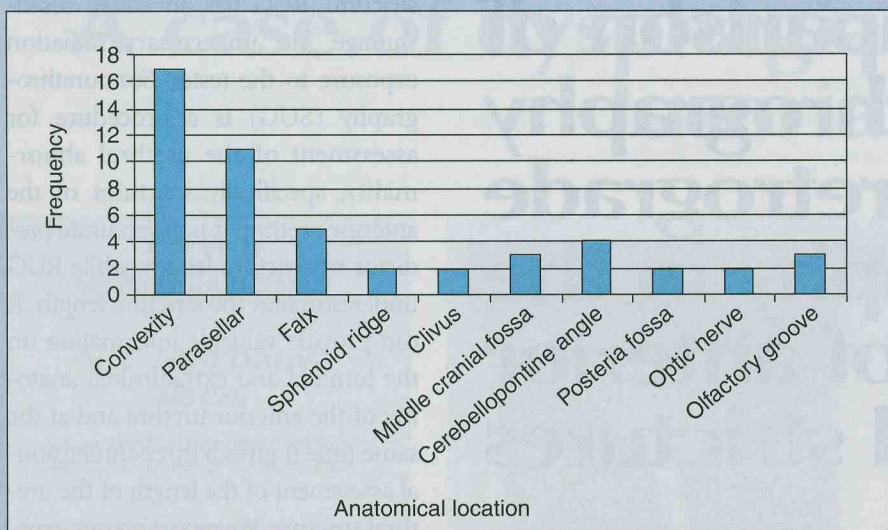


Fig. 2. Graphical presentation of anatomical location in 52 cases.

## References

1. Osborne AG. *Diagnostic Neuroradiology*. St Louis, Missouri: Mosby, 1994.
2. Dahnert W. *Radiology Review Manual*. 5th ed. Philadelphia: Lippincot Williams and Wilkins, 2003.
3. Rohringer M, Sutherland GR, Louw DF, Sima AAF. Incidence and clinicopathological features of meningiomas. *J Neurosurg* 1989; **71**: 665-672.
4. Whittle IR, Smith C, Navoo P, Collie D. Meningiomas. *Lancet* 2004; **363**: 1535-1543.
5. Takano N, Asano K, Miura H, Itoh S, Suzuki S. Meningiomas with brain oedema. Radiological characteristics and review of the literature. *Clinical Imaging* 2002; **26**: 243-249.
6. Raco A, Agrillo A, Gagliardi FM, Cantore G. Surgical options in the management of falcomeningiomas: report of 13 cases. *Surg Neurol* 2004; **61**: 157-164.
7. Black PM. Meningiomas. *Neurosurgery* 1993; **32**: 643-657.
8. Erdinler P, Lena G, Sarioglu AC, Kunday C, Choux M. Intracranial meningiomas in children: Review of 29 cases. *Surg Neurol* 1998; **49**: 136-141.

## Manager, Diagnostic Imaging Northern Lights Health Region

Fort McMurray, Alberta, CANADA

Northern Lights Health Region (NLHR) in Alberta, Canada services one of Canada's fastest growing and prosperous municipalities. At work and home, the Region offers both the benefits of a growing northern hub and those of a rural town. Residents of Fort McMurray enjoy modern urban amenities without the hassles of big city living. Geographically the largest region in Alberta, NLHR's staff and physicians serve almost 70,000 people from more than 20 centers located throughout the region. Due to a recent retirement, the Region is now seeking a new Manager, Diagnostic Imaging to lead this well functioning area.

The new Manager will take a proactive approach to planning and delivering Diagnostic Imaging Services to patients in the Northern Lights Regional Health Centre. The breadth of this role, combined with the strong team, stable work environment and growing community, provides a unique opportunity to an adventurous Diagnostic Imaging specialist looking for a challenge and an exciting opportunity in beautiful Alberta, Canada.

Reporting to the Director, Critical Care, the Manager, Diagnostic Imaging is responsible for leading the Diagnostic Imaging group in a manner that provides high quality ultrasound, CT, mammography and radiology services. The role directs staff and equipment, provides quality service and ensures delivery in a safe, timely and cost effective manner.

To explore this opportunity further, please forward your resume in confidence to [laurie.sterritt@rayberndtson.ca](mailto:laurie.sterritt@rayberndtson.ca) or phone Laurie Sterritt, Lee Rennison or Lisa Kershaw at (604) 685-0261.