

The transjugular intrahepatic portosystemic shunt (TIPSS) procedure — a review

I C Duncan
FFRad (D)

Unitas Interventional Unit
Centurion
Gauteng

Management of acute variceal bleeding

Patients with portal hypertension may either be asymptomatic or present with symptoms due to variceal bleeding, ascites, encephalopathy or hypersplenism. Variceal haemorrhage occurs in up to 85% of cases at the gastro-oesophageal junction. The management of variceal bleeding, and in particular of an acute life-threatening haemorrhage, is both complex and difficult. Direct active interventions aimed at controlling variceal bleeding include sclerotherapy, band ligation, vaso-active drug administration, balloon tamponade and surgery. Mechanical balloon tamponade and systemic pharmacological therapy may be used either alone or in combination. The use of balloon tamponade is associated with 10 - 20% morbidity, including aspiration,

oesophageal perforation and ulceration. There is also a 30% rebleed rate within 72 hours with a 30% early and late associated mortality.¹ Endoscopic sclerotherapy is more effective than balloon tamponade in controlling acute variceal haemorrhage.² Emergency endoscopic sclerotherapy is the currently preferred method of treatment for acute variceal haemorrhage and is effective in up to 90% of cases, although multiple endoscopic treatments are often required.³ Variceal band ligation is effective, particularly with large varices, and has a lower rebleeding rate than sclerotherapy.⁴ However, neither endoscopic sclerotherapy nor band ligation addresses the underlying portal hypertension, and rebleeding occurs in up to 50% of patients thus treated.

Surgery can be considered for patients with recurrent variceal bleeding despite use of the abovementioned treatments. Non-shunt operations include urgent liver transplantation, devascularisation procedures and splenectomy. Portosystemic shunt procedures are aimed at either diverting portal blood flow, e.g. portocaval or mesocaval shunts, or decompressing the portal system but pre-

serving portal blood flow, e.g. the distal splenorenal (Warren) or Sarfeh shunts. However, the operative mortality associated with surgical portocaval shunt creation in Child's class C patients is as high as 50%.⁵ The overall surgical mortality rate regardless of expected clinical outcome and type of shunt created, is around 10 - 20%.⁶ The TIPSS (transjugular intrahepatic portosystemic shunt) procedure developed from a search for a less invasive non-surgical technique aimed at reducing portal pressure.

The TIPSS procedure

Historical overview

Rösch and co-workers created the first percutaneous intrahepatic portosystemic shunts in 1969 in experimental animals.⁷ In 1982, Colapinto and co-workers described the creation of percutaneous intrahepatic shunts in 6 human subjects.⁸ A tract was dilated through the liver parenchyma between a hepatic vein and an intrahepatic portal vein using a balloon catheter inflated across the tract for 12 hours. Despite a reduction in portal venous pressure, 4 of the 6 patients developed recurrent bleeding. Both Colapinto and Rösch had experienced major problems in maintaining long-term patency of their shunts. It was only later with the advent of metallic stents that a renewed interest in the TIPSS procedure came about as these stents could now keep the parenchymal tract open, improving long-term shunt patency.⁹⁻¹²

Technique

A TIPSS can be created under either local or general anaesthesia, although anaesthetic support through-

out the procedure is mandatory. A sheath is placed via an internal jugular vein into a hepatic vein (initially usually the right one). A long curved needle is then placed through the sheath and under fluoroscopic guidance is thrust through the wall of the hepatic vein and adjacent parenchyma into a major branch of the portal vein. A rigid guidewire is then passed through the needle into the portal system and the needle is removed and replaced by a diagnostic catheter. Contrast injected through this catheter allows visualisation of the portal system as well as the presence of any visible portosystemic collaterals and varices. The catheter is then exchanged for a balloon catheter and the tract is dilated between the hepatic and portal veins. This parenchymal tract is then stented to ensure shunt patency (Figs 1a - c). Generally self-expanding stents of 10 - 12 mm diameter are used. Pressure measurements are obtained after stent placement. The goal of treatment is to reduce the portosystemic pressure gradient to less than 10 - 15 mmHg.¹³ In most cases the stent is initially dilated to a diameter of 8 mm, but if the portosystemic pressure gradient exceeds 15 mmHg then the stent can be further expanded to 10 or 12 mm diameter to ensure further reduction of any residual pressure gradient. If this pressure gradient reduction is still insufficient a second shunt can be placed through the left hepatic lobe. If varices are visualised the left gastric and/or short gastric veins can be catheterised through the shunt and embolised using occlusion coils, gelfoam, cyanoacrylate or sclerosing agents (Figs 2a and 2b).

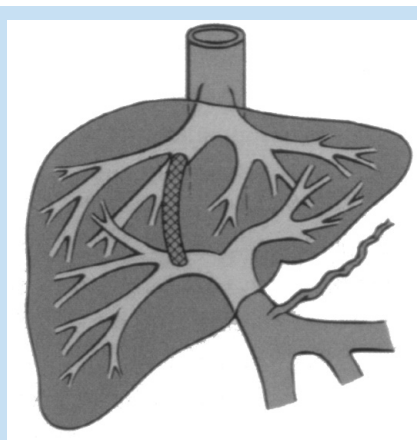


Fig. 1a. Diagrammatic representation of the TIPSS shunt with stenting of the tract created between the portal and hepatic veins.

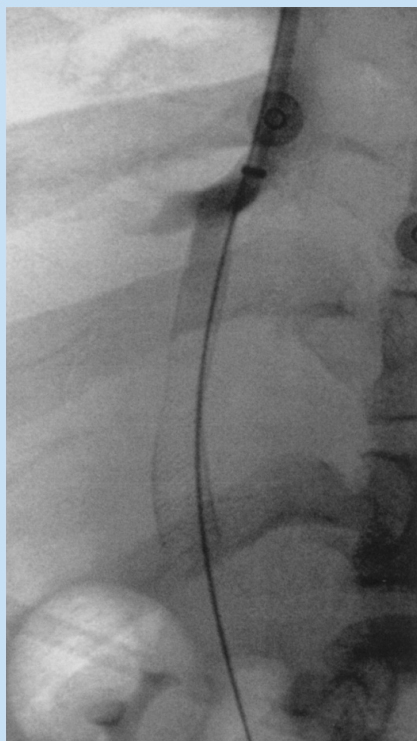


Fig. 1b. Following TIPSS creation, a self-expanding wallstent has been used to maintain patency of the parenchymal tract between the right hepatic vein and the right portal vein.

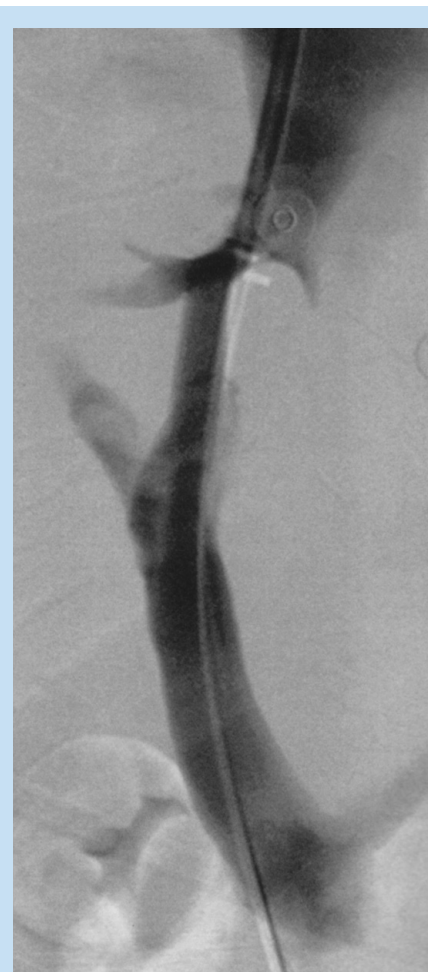

Fig. 1c. A final check portogram shows flow of contrast through the shunt into the hepatic vein thereby decompressing the portal system. It is important that there still be some visible flow of contrast beyond the stent into the intrahepatic portal branches otherwise encephalopathy and liver failure may result.

Indications, contraindications and patient selection

The indications for and contraindications to TIPSS remain controversial. The National Digestive Diseases Advisory Board summarised them in 1994 as follows.¹⁴

1. The two accepted indications are:
 - Acute variceal bleeding that cannot be successfully controlled with medical treatment or sclerotherapy
 - Recurrent variceal bleeding unresponsive to medical therapy or repeated sclerotherapy.
 2. Additional indications include:
 - Intractable ascites
 - Portal hypertension due to hepatic venous outflow obstruction (Budd-Chiari syndrome).
- TIPSS is not recommended for the initial therapy of acute variceal haemorrhage.

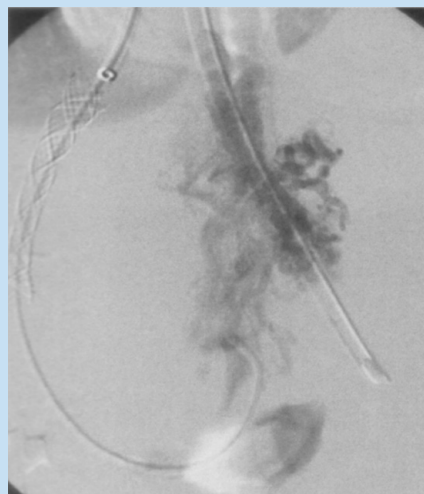


Fig. 2a. After placement of the stent the check portogram demonstrates persistent filling of collateral veins and varices via the coronary vein.

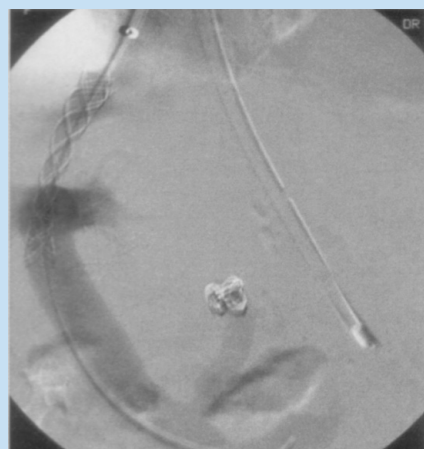


Fig. 2b. These can then be embolised before the catheters are withdrawn from the portal system.

Absolute contraindications to TIPSS include:

- Severe right-sided heart failure with markedly elevated central venous pressure
- Polycystic liver disease
- Severe hepatocellular failure.

Relative contraindications to TIPSS include:

- Active intrahepatic or systemic infection
- Hypervascular hepatic tumours
- Severe hepatic encephalopathy refractory to medical therapy
- Portal vein thrombosis.

Adequate pre-procedural imaging of the liver is essential for several reasons including review of the hepatic and portal venous anatomy, exclusion of any hypervascular tumour along the intended tract, and confirmation of a patent portal vein. This may be accomplished by colour-flow Doppler ultrasound, computed tomography (CT), magnetic resonance imaging (MRI) or indirect arterial portography (Fig. 3). Portal vein occlusion is a relative contraindication as portal vein recanalisation may be possible before placement of the TIPSS if the occlusion is due to soft thrombus.¹⁵ This is usually not possible in cases of chronic portal occlusion.

The only definitive treatment for the underlying advanced hepatic pathology that has caused the secondary portal hypertension is liver transplantation. The use of TIPSS as a bridging procedure prior to transplantation is controversial. However, pre-transplantation TIPSS has been shown to improve the medical condition and nutritional status of patients, reduce operative blood loss and procedure time, and decrease hospital stay.¹⁶

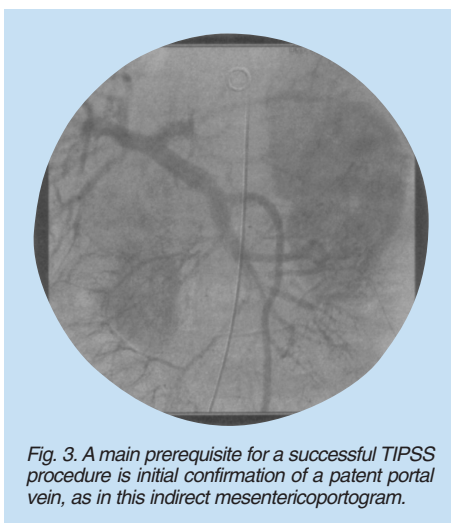


Fig. 3. A main prerequisite for a successful TIPSS procedure is initial confirmation of a patent portal vein, as in this indirect mesenteric portogram.

TIPSS has been used in patients with variceal bleeding at atypical sites such as colonic, stomal and anorectal varices, portal hypertensive gastropathy and patients with hepatorenal syndrome.^{17,18}

It is vital to assess the anatomy of the hepatic and portal veins before a TIPSS procedure. Apart from portal patency, the position of the portal vein bifurcation is the most critical anatomical feature to be identified. Schultz *et al.*¹⁹ showed in a study of 31 cadavers that the portal bifurcation was found to be extrahepatic in 48.4%, intrahepatic in 25.8% and 'junctional' (i.e. within 1 cm of the capsule) in 25.8%.

Results and complications

The technical success rates for TIPSS reported in the literature are over 95%. However, in general poor long-term durability appears to be the rule, with an average 25% rate of rebleeding at 1 year. This is usually due to shunt stenosis or occlusion. Shunt stenosis is very common, occurring in between 31% and 80% of cases within 1 year.^{20,21} Shunt stenosis occurs in one of two locations, either being within the parenchymal portion, accounting for 30% of stenoses (but 70% of symptomatic stenoses), or at the outflow hepatic vein.^{22,23}

Histologically the stenosis within the outflow vein is due to intimal hyperplasia whereas that seen in the stent lumen is a thickened neo-intima consisting of myofibroblasts and collagen, termed 'pseudo-intimal hyperplasia'. There is mounting evidence that the development of this pseudointimal hyperplasia may be related to associated bile duct injury and bile leakage.^{24,25} This huge rate of

restenosis means that close radiological follow-up of the shunts is mandatory. Repeat percutaneous hepatic venography is more efficacious but also more invasive and expensive than Doppler ultrasonography. In an attempt to reduce this huge restenosis rate, covered stents are now being used and have improved short- to mid-term shunt patency.²⁶⁻²⁸ With repeated interventional procedures, the assisted patency rates increase to 80 - 90% at 1 year and 87% at 3 years.^{21,23,29}

Other complications related to the TIPSS procedure can be divided into short-term and long-term ones. Procedural morbidity occurs in up to 10% of cases,³⁰ intraperitoneal haemorrhage in 3 - 13% and haemobilia in 1 - 4%. Transient increases in serum bilirubin, transaminases, prothrombin time and ammonia are seen in 10 - 20% of cases during the first post-procedural week. About 25% of patients develop new or worsened encephalopathy, but only 5% are unresponsive to medical treatment. Death from fulminant hepatic failure occurs in 3 - 7% of patients within 30 days. Acute shunt thrombosis is reported in 3 - 4% of cases. Acutely thrombosed shunts can be reopened by mechanical clot disruption or thrombolysis or placement of additional stents. Other peri-procedural complications include fever and sepsis (3 - 10%), stent malposition or migration (1 - 5%), acute renal failure and cardiac arrhythmias. The procedure-related mortality rate is 0 - 2%, death mainly being due to extracapsular perforation with intraperitoneal haemorrhage, hepatic arterial injury or acute right heart failure. Overall 30-day mortality rates are variable (3 - 45%) and are probably related more

to the underlying pathology than the procedure itself. Roessle *et al.*³¹ reported an overall 1-year survival rate of 87% with rates of 100%, 86% and 73% for patients in Childs-Pugh classes A, B and C respectively.

Occasionally worsening of the encephalopathy or liver failure after TIPSS can necessitate stent reduction or even shunt occlusion.

When TIPSS is performed for intractable ascites about 50 - 75% of patients will have partial or complete resolution within 1 month.^{32,33}

Conclusions

TIPSS is a seldom-performed procedure in South Africa. We have performed only 13 cases in our combined practice (Johannesburg and Pretoria) since 1994. Among the reasons for this small number may be the greater availability and efficacy of endoscopic variceal treatment and medical therapies for portal hypertension, lack of knowledge about the availability and usage of the TIPSS procedure, lack of suitable interventional expertise in many state hospitals and outside the main centres, and lack of a full-time liver transplant programme in South Africa. Locally TIPSS has essentially been employed as a palliative procedure. Throughout the world the TIPSS procedure has lost much of its initial popularity owing to poor long-term primary shunt patency rates, although as mentioned these can be improved significantly by performing secondary and further interventions. It is hoped that newer technologies, including the use of covered stents or drug-eluting stents, will reduce the high stenosis rate, leading to better long-term primary patencies and durability of the TIPSS.

References

1. Teres J, Planas R, Panes J, *et al.* Vasopressin/nitroglycerin infusion vs oesophageal tamponade in the treatment of acute variceal bleeding. *Hepatology* 1990; **11**: 964-968.
2. Moreto M, Zaballa M, Bernal A, *et al.* A randomized trial of tamponade or sclerotherapy as immediate treatment for bleeding oesophageal varices. *Surg Gynecol Obstet* 1988; **167**: 331-334.
3. Grace ND. Diagnosis and treatment of gastrointestinal bleeding secondary to portal hypertension: American College of Gastroenterology Practice Parameters Committee. *Am J Gastroenterol* 1997; **92**: 1081-1091.
4. Gimson AE, Ramage JK, Panos MZ, *et al.* Randomized trial of variceal banding ligation versus portocaval shunting in patients with severe cirrhosis and variceal haemorrhage. *Lancet* 1993; **342**: 391-394.
5. Cello JP, Grendell JN, Crass RA, *et al.* Endoscopic sclerotherapy versus portocaval shunting in patients with severe cirrhosis and variceal hemorrhage. *N Engl J Med* 1984; **31**: 1589-1594.
6. Orloff MJ, Orloff MS, Orloff SL, *et al.* Three decades of experience with emergency portocaval shunt for actively bleeding oesophageal varices in 400 unselected patients with cirrhosis of the liver. *J Am Coll Surg* 1995; **180**: 257-272.
7. Rösch J, Hanafee WN, Snow H. Transjugular portal venography and radiological portocaval shunt: an experimental study. *Radiology* 1969; **92**: 1112-1114.
8. Colapinto RF, Stronell RD, Birch SJ, *et al.* Creation of an intrahepatic portosystemic shunt with a Gruntzig balloon catheter. *Can Med Assoc J* 1982; **26**: 267-268.
9. Palmaz JC, Sibbit RR, Reuter SR, *et al.* Expandable intrahepatic portocaval shunt stents: early experience in the dog. *Am J Roentgenol* 1985; **145**: 821-825.
10. Rösch J, Uchida BT, Putnam JS, *et al.* Experimental intrahepatic portocaval anastomosis: use of expandable Gianturco stents. *Radiology* 1987; **162**: 481-485.
11. Rössle M, Richter GM, Noldge G, *et al.* Performance of an intrahepatic portocaval shunt (PCS) using a catheter technique: a case report. *Hepatology* 1988; **8**: 1348.
12. Richter GM, Noeldge G, Palmaz JC, *et al.* The transjugular intrahepatic portosystemic stent-shunt (TIPSS): results of a pilot study. *Cardiovasc Interv Radiol* 1990; **13**: 200-207.
13. LaBerge JM, Ring EJ, Gordon RL, *et al.* Creation of transjugular portosystemic shunts with the Wallstent endoprosthesis: results in 100 patients. *Radiology* 1993; **187**: 413-421.
14. Shiffman ML, Jeffers L, Hoofnagle JH, *et al.* The role of transjugular intrahepatic portosystemic shunts for treatment of portal hypertension and its complications: a conference sponsored by the National Digestive Diseases Advisory Board. *Hepatology* 1995; **22**: 1591-1597.
15. Radosovich PM, Ring EJ, LaBerge JM, *et al.* Transjugular intrahepatic portosystemic shunts in patients with portal vein occlusion. *Radiology* 1993; **186**: 523-527.
16. Menegaux F, Keeffe EB, Baker E, *et al.* Comparison of transjugular and surgical por-

- tosystemic shunts on the outcome of liver transplantation. *Arch Surg* 1994; **129**: 1018-1023.
17. Haskal ZJ, Scott M, Rubin RA, *et al*. Intestinal varices: treatment with transjugular intrahepatic portosystemic shunt. *Radiology* 1994; **91**: 183-187.
 18. Sturgis TM. Hepatorenal syndrome: resolution after transjugular intrahepatic portosystemic shunt. *J Clin Gastroenterol* 1995; **20**: 241.
 19. Schultz SR, LaBerge JM, Gordon RL, *et al*. Anatomy of the portal vein bifurcation: extra-versus intrahepatic locations — implications for transjugular intrahepatic portosystemic shunt. *J Vasc Interv Radiol* 1994; **10**: 457-459.
 20. Rossle M, Siegerstetter V, Huber M, *et al*. The first decade of the transjugular intrahepatic portosystemic shunt (TIPS): state of the art *Liver* 1998; **18**: 73-89.
 21. La Berge JM, Somberg KA, Lake JR, *et al*. Two-year outcome following transjugular intrahepatic portosystemic shunt for variceal bleeding: Results in 90 patients. *Gastroenterology* 1995; **108**: 1143-1151.
 22. Saxon RS, Ross PL, Mendel-Hartvig J, *et al*. Transjugular intrahepatic portosystemic shunt patency and the importance of stenosis location in the development of recurrent symptoms. *Radiology* 1995; **197**: 801-804.
 23. Haskal ZJ, Pentecost MJ, Soulen MC, *et al*. Transjugular intrahepatic portosystemic shunts stenosis and revision: Early and midterm results. *Am J Roentgenol* 1994; **163**: 439-444.
 24. LaBerge JM, Ferrell LD, Ring EJ, *et al*. Histopathologic study of stenotic and occluded transjugular intrahepatic portosystemic shunts. *J Vasc Interv Radiol* 1993; **4**: 779-786.
 25. Saxon RR, Mendel-Hartvig J, Corless CL, *et al*. Bile duct injury as a major cause of stenosis and occlusion in transjugular intrahepatic portosystemic shunts: Comparative histopathologic analysis in humans and swine. *J Vasc Interv Radiol* 1996; **7**: 487-497.
 26. Saxon RR, Timmersmans HA, Uchida BT, *et al*. Stent-grafts for revision of TIPS stenoses and occlusions: A clinical pilot study. *J Vasc Interv Radiol* 1997; **8**: 539-548.
 27. Haskal ZJ. Improved patency of transjugular intrahepatic portosystemic shunts in humans: Creation and revision with PTFE stent-grafts. *Radiology* 1999; **213**: 759-766.
 28. Sze DY, Vestring T, Liddell RP. Recurrent TIPS failure associated with biliary fistulae: Treatment with PTFE-covered stents. *Cardiovasc Intervent Radiol* 1999; **22**: 298-304.
 29. Sterling KM, Darcy MD. Stenosis of transjugular intrahepatic portosystemic shunts: Presentations and management. *Am J Roentgenol* 1997; **168**: 239-244.
 30. Freedman AM, Sanyal AJ, Tisando J, *et al*. Complications of transjugular intrahepatic portosystemic shunts: A comprehensive review. *Radiographics* 1993; **13**: 1185-1210.
 31. Roessle M, Haag K, Ochs A, *et al*. The transjugular intrahepatic portosystemic stent-shunt procedure for variceal bleeding. *N Engl J Med* 1994; **330**: 165-171.
 32. Crenshaw WB, Gardon FD, McEniff NJ, *et al*. Severe ascites: efficacy of the transjugular intrahepatic portosystemic shunt in treatment. *Radiology* 1996; **200**: 185-192.
 33. Ochs A, Roessle M, Haag K, *et al*. The transjugular intrahepatic portosystemic stent-shunt procedure for refractory ascites. *N Engl J Med* 1995; **332**: 1192.