

Conned by Conn's syndrome

F Ismail, MB BCh
Z Lockhat, FCRad (D) SA

Department of Radiology, Pretoria Academic Hospital, University of Pretoria

S Ellemdin, MB BCh, MMed Int Med
L van der Linde, MB ChB, DOH&M

Department of Internal Medicine, Pretoria Academic Hospital, University of Pretoria

Abstract

Conn's syndrome is a rare condition among hypertensive patients; imaging of the aldosterone-producing adenoma (APA) can prove challenging but is nonetheless very important for surgical planning and cure. We present two patients with MRI (magnetic resonance imaging) confirmation of APA with negative and equivocal CT (computed tomography) scans.

Case 1

A 40-year-old woman presented with uncontrolled hypertension and weakness since May 2001. On examination, her blood pressure was 144/107 mmHg. A 12-lead electrocardiogram (ECG) reading showed left ventricular hypertrophy.

Haematological investigation demonstrated that the patient had a metabolic alkalosis with bicarbonate of 26.4 mmol/l. Her initial potassium level was low, i.e. 1.3 mmol/l (normal is 3.3 - 5.3 mmol/l) and initial sodium was high, i.e. 149 mmol/l (normal is 135 - 147 mmol/l). Her renin level was <4.5 mIU/l (low), aldosterone was 2 234 pmol/l (high) and her transtubular potassium gradient was 17 (high). A diagnosis of

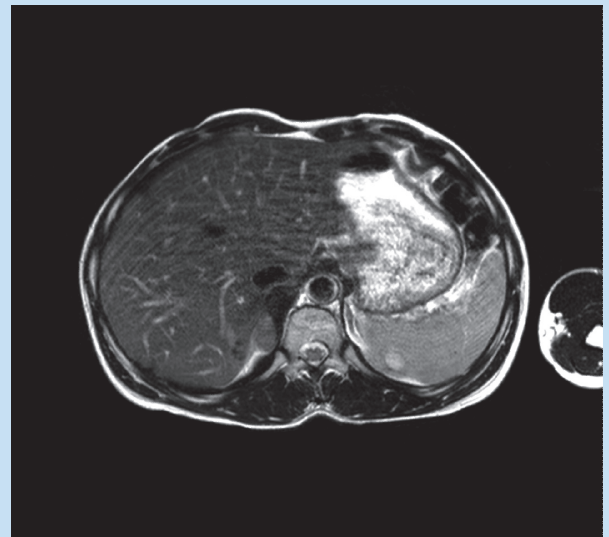


Fig. 2. Axial T2 (TR 2.01/TE 100) weighted MRI sequence demonstrates a right adrenal mass which has higher signal compared with the liver but lower signal compared with surrounding fat.

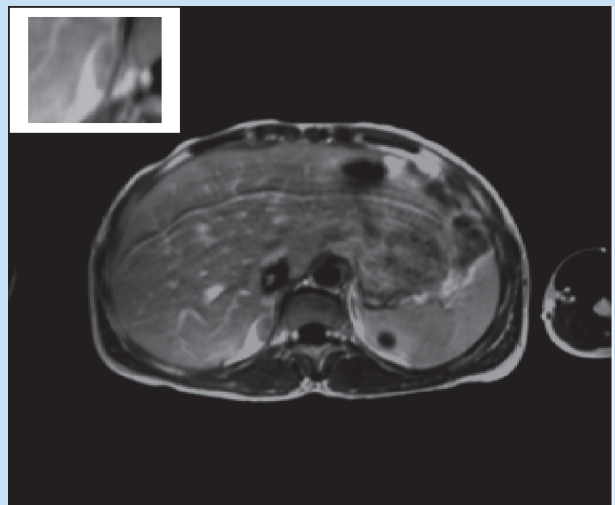


Fig. 3. The post-gadolinium T1 weighted (TR 525/TE 13) axial MRI demonstrates contrast enhancement of the mass easily visualised in the right adrenal gland. There is an incidental simple cyst in the left kidney. The left adrenal gland is well demonstrated and is normal.

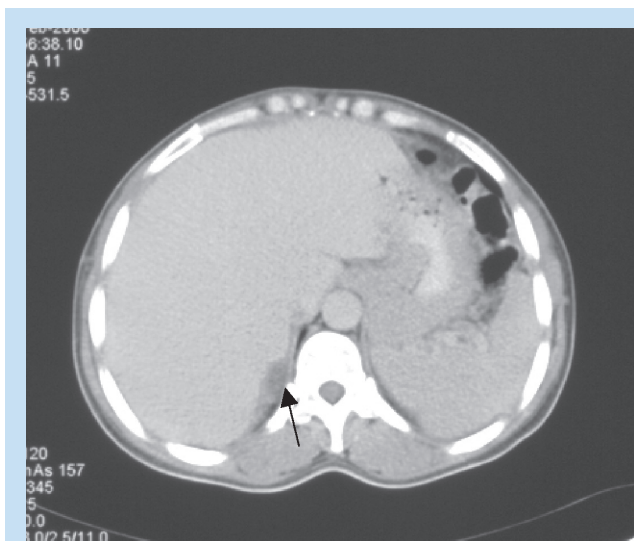


Fig. 1. Axial venous phase CT demonstrates a low-density area in the region of the right adrenal gland suggestive of a possible mass.

Conn's syndrome was confirmed biochemically. She was referred for radiological evaluation to establish the site of the pathology.

Imaging

Computed tomography (CT) (Fig. 1) was indicative of a low-density, non-contrast-enhancing lesion in the right adrenal gland. This apparent lesion measured 5.9×6.2 mm and had a density of 20 HU post-contrast. The lesion was not well demonstrated as it was not possible to separate

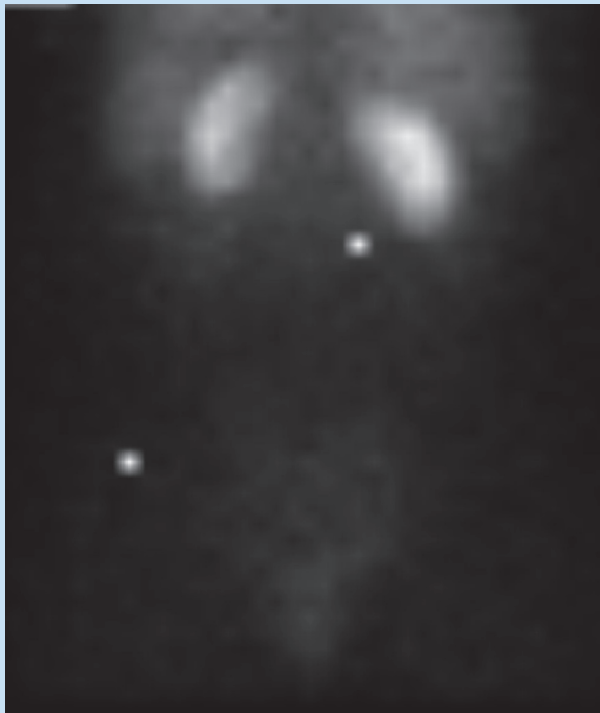


Fig. 4. Tc-99m DTPA scintigraphy in coronal posterior-anterior view demonstrates that the left kidney is smaller than the right, but both kidneys demonstrate normal tracer uptake.

3.3 mm and the lateral limb 3.5 mm. The CT scan thus suggested APA in the right gland but further imaging was required for confirmation.

Magnetic resonance imaging (MRI) confirmed the lesion in the medial limb of the right adrenal gland, measuring 1.2×1.2 cm, and demonstrated a high signal on the T2 sequence (Fig. 2) and contrast enhancement on the post-gadolinium T1-weighted sequence (Fig. 3). The lateral limb measured 3.8 mm with a homogeneous signal on all sequences. The MRI also confirmed that the left adrenal gland was normal. Thus, right adrenal APA was confirmed on MRI.

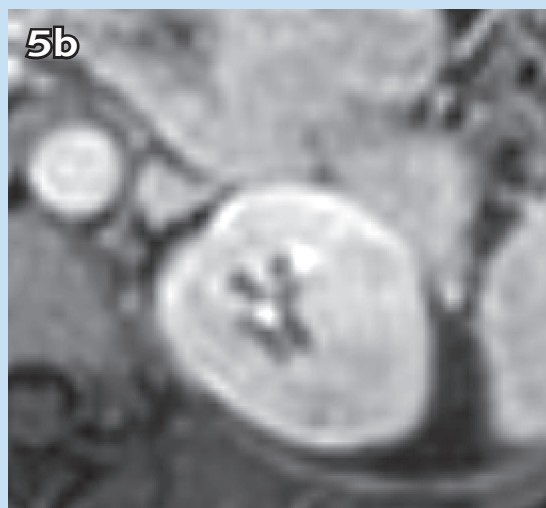
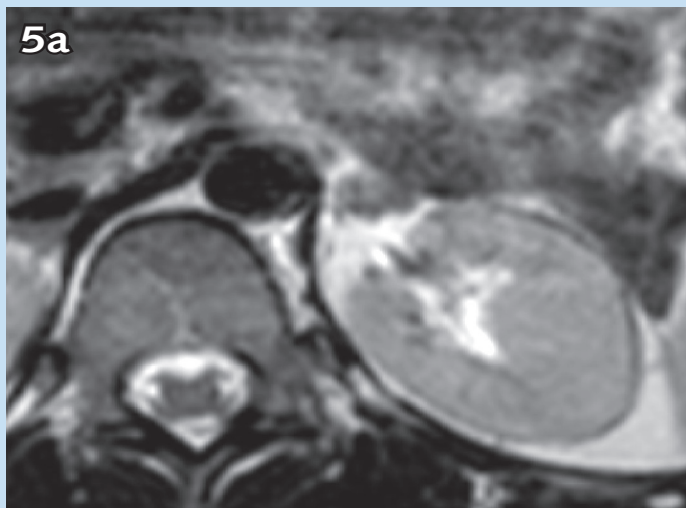
The patient underwent a right laparoscopic adrenalectomy and subsequently recovered from her hypertension and metabolic disturbances. Macroscopic histology of the specimen confirmed a well-circumscribed nodule in the right adrenal gland, measuring 1.8×1.2 cm, which was yellow in colour when sectioned. On microscopy, a cortical adenoma was found, consisting of cells with clear cytoplasm.

Case 2

A 30-year-old woman presented with uncontrolled hypertension. There were no other clinical symptoms of note. Examination revealed elevated blood pressure of 150/100 mmHg. Cardiac and ECG examination was normal. Biochemical evaluation was unremarkable.

Imaging

As part of her investigation, the patient had a renal ultrasound scan which demonstrated a small left kidney measuring 7.7×3.5 cm. The right kidney was 9.2×4.6 cm. Both kidneys demonstrated good cortico-medullary differentiation. The left renal artery demonstrated



Figs 5a and 5b demonstrate the mass in the body of the left adrenal gland, which is low signal on the T2 weighted sequence (Fig. 5a), and demonstrates contrast enhancement post-gadolinium (Fig. 5b).

the lesion from the surrounding vasculature and organs, and there was insufficient abdominal fat around the gland. Also, it was not possible to determine which part of the gland was affected. The left adrenal gland demonstrated homogeneous density, with the medial limb measuring

normal flow and calibre. Resistance indices were normal bilaterally. The patient went on to have a diuretic renogram to assess renal function. Tc-99m DTPA was administered intravenously, and the left kidney was found to be smaller than the right (Fig. 4). Both kidneys demonstrated normal tracer uptake and excretion.

The patient then had a formal angiogram (to exclude renal artery stenosis as a possible cause of her hypertension) which demonstrated normal flow and calibre in the renal arteries bilaterally. Venous sampling for aldosterone levels was performed. An elevated aldosterone level was found in the left renal vein, i.e. 244.0 pmol/l. This was still within normal limits for a patient in the supine position, with the upper limit of normal being <440 pmol/l; however, this was much higher than the level in the right renal vein (77.3 pmol/l) as well as higher than the aldosterone level in the inferior vena cava (80.5 pmol/l).

Contrast-enhanced CT was normal, with no enlargement of the adrenal glands present. Both adrenal glands were visualised displaying homogeneous contrast enhancement. The right adrenal gland measured 3.3 mm in the medial limb and 3.7 mm in the lateral limb; the left adrenal gland measured 4.1 mm in the medial limb and 3.5 mm in the lateral limb. Thus, CT was not helpful in the diagnosis of APA.

MRI demonstrated a mass in the left adrenal gland involving the body of the gland. It measured 1.1×0.93 cm. It was low signal as compared with the left kidney on the T2 weighted sequence (Fig. 5a) with contrast enhancement post gadolinium (Fig. 5b). The right adrenal gland was normal, and a diagnosis of left APA was confirmed.

In two patients with adrenal adenoma, therefore, the CT scan was inconclusive, while the diagnosis was made on MRI.

Discussion

Conn's syndrome was first described in 1955 by J W Conn in a patient who had an APA. The disease is more common in females, who present between the third and sixth decades of life. It is part of the differential for primary hyperaldosteronism, where bilateral adrenal hyperplasia (BAH) is the other differential. The prevalence is 0.3 - 1.2% of the hypertensive population.¹

Radiological studies that aid the diagnosis of adrenal adenomas include contrast-enhanced CT, MRI and adrenal vein sampling of aldosterone levels. Nuclear medicine studies include adrenal scintigraphy.

For adenomas measuring close to 1 cm or more, CT is the investigation method of choice. CT is reported to have a sensitivity of 60 - 85%.¹ Protocols include pre-contrast densitometry measurement and contrast enhancement densitometry measurement in the venous and delayed phase with calculation of contrast washout. More recently, adrenal venous sampling is reported to be the standard of reference for determining the cause of primary aldosteronism. However, this method is technically demanding, operator-dependent, costly and time-consuming, with a low but significant complication rate.²

MRI is valuable in the diagnosis of APA. In a study by Sohaib *et al.*, MRI detection of APA had an overall specificity of 100%, sensitivity of 70%, and accuracy of 85%. The mean size of lesions detected was 0.2×1.6 cm.³ CT and MRI are therefore both sensitive and specific in the diagnosis of APA. A comparative study by Lingam *et al.* demonstrated similar sensitivities and specificities for the detection of an APA for both CT (86% and 87.5%, respectively) and MRI (87.5% and 87.5%, respectively) with good inter-observer agreement.²

Sohaib *et al.* have shown that MR imaging is a specific test for the detection of APA. In the correct clinical setting, if APA is suspected and a unilateral nodule is detected with a contralateral normal gland, then the diagnosis of APA can be made and the patient may be treated surgically. Both APA and BAH show evidence of a substantial amount of intracellular lipid and signal intensity (SI) characteristics similar to those of other adenomas (as was demonstrated with our patient). Therefore, SI did not help in distinguishing between the two.³

It is important to distinguish BAH from APA as the former is treated medically and the latter, surgically. The best way is to measure each limb of the gland as well as the body. A study by Lingam *et al.* showed that CT has a sensitivity of 100% when a mean limb width >3 mm was used to diagnose bilateral adrenal hyperplasia, and a specificity of 100% was achieved when the mean limb width was ≥5 mm.⁴

Radiopharmaceuticals allow non-invasive assessment of adrenal function and can be used to differentiate between an APA and BAH.²

Recommendations

Both CT and MRI are valuable diagnostic tools in the diagnosis of APA and in differentiating APA from BAH. MRI has a similar sensitivity and specificity in the literature as compared with CT, but at our institution we are finding that MRI has a higher sensitivity, as demonstrated by these two cases. However, two cases alone are not statistically significant, therefore further research in this field is required. Adrenal vein sampling is the gold standard but has disadvantages. We intend to undertake further research in this regard to establish the best diagnostic protocol for our patients at our institution.

1. Jabbour SA, Goldstein BJ, Talavera F, Chausmer AB, Cooper M, Griffing GT. Conn syndrome. *www.emedicine.com* (accessed 13 May 2007).
2. Patel SM, Lingam RK, Beaconsfield TL, Tran TL, Brown B. Role of radiology in the management of primary aldosteronism. *Radiographics* 2007; 27: 1145-1157.
3. Sohaib SA, Peppercorn PD, Allan C, *et al.* Primary hyperaldosteronism (Conn syndrome): MR imaging findings. *Radiology* 2000; 214: 527-531.
4. Lingam RK, Sohaib SA, Vlahos I, *et al.* CT of primary hyperaldosteronism (Conn's syndrome): The value of measuring the adrenal gland. *Am J Roentgenol* 2003; 181: 843-849.