

Endovascular stent grafting of traumatic aortic arch pseudo-aneurysm

N Mahomed, MB BCH

T Briede, MB BCH, FCRad (SA)

M Modi, MB BCH, FCRad (SA), MMed

Department of Radiology, Chris Hani Baragwanath Hospital, University of the Witwatersrand, Johannesburg

Abstract

Endovascular stent graft repair for the treatment of post-traumatic aortic rupture is emerging as a safe, minimally invasive and attractive alternative to surgery. This report covers the importance of computer tomographic (CT) angiography as a non-invasive imaging modality in the diagnoses of post-traumatic aortic rupture and the role of CT in pre-endovascular stent work-up. A detailed discussion on the endovascular procedure including the major limitations to stent insertion follows, and a comparison of endovascular stent graft versus surgery.

Introduction

Post-traumatic aortic rupture is the cause of 16% of all deaths from motor vehicle accidents; of all patients sustaining such injury, 85% will die before reaching hospital. Fifty per cent of the remaining survivors will die within 24 hours.¹ Therefore, prompt diagnosis and treatment within this critical stage remains crucial.¹

The recent development of aortic stent grafts has brought the management of thoracic aortic aneurysms into the realm of interventional radiology as an alternative to conventional open surgery.² Stent graft

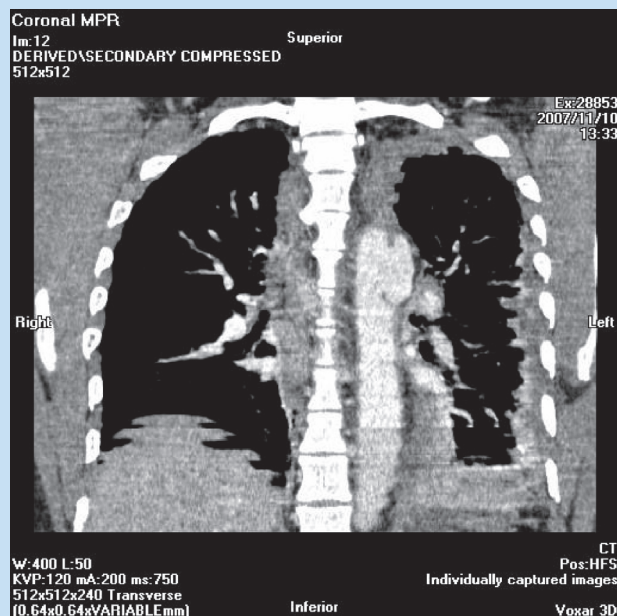


Fig. 2. Post-contrast chest CTA (coronal view), demonstrating the pseudo-aneurysm in the distal aortic arch.

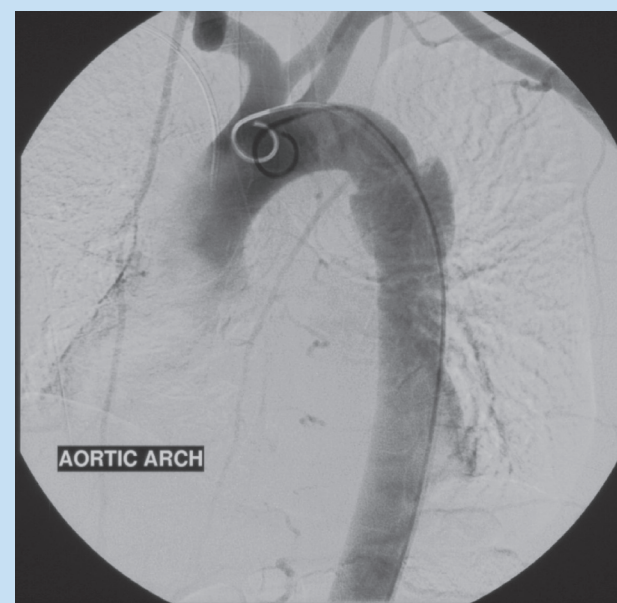


Fig. 3. Digital subtraction angiogram with the pigtail catheter in the aortic arch demonstrating the descending thoracic aortic pseudo-aneurysm distal to the origin of the LSA.

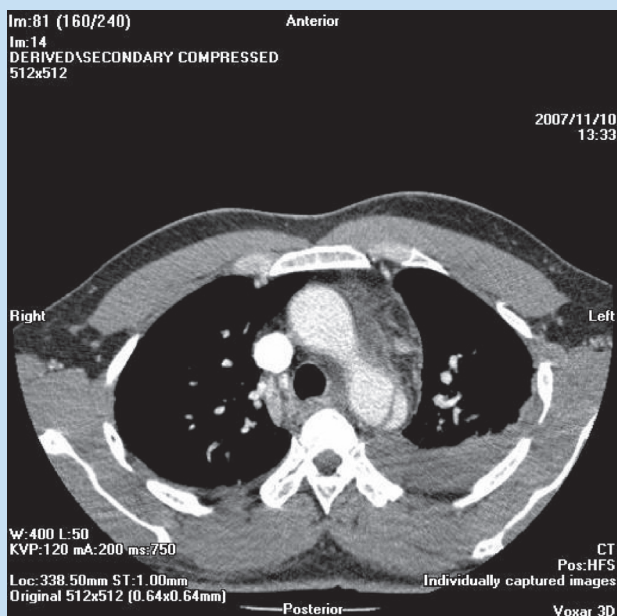


Fig. 1. Post-contrast chest CT angiogram (axial view), demonstrating a tear in the distal aortic arch associated with a left haemothorax.

placement is proving to be a safe, minimally invasive and effective treatment for thoracic aortic disease in poor surgical candidates, and short-term morbidity and mortality rates from endovascular repair compare favourably with those from surgery.²

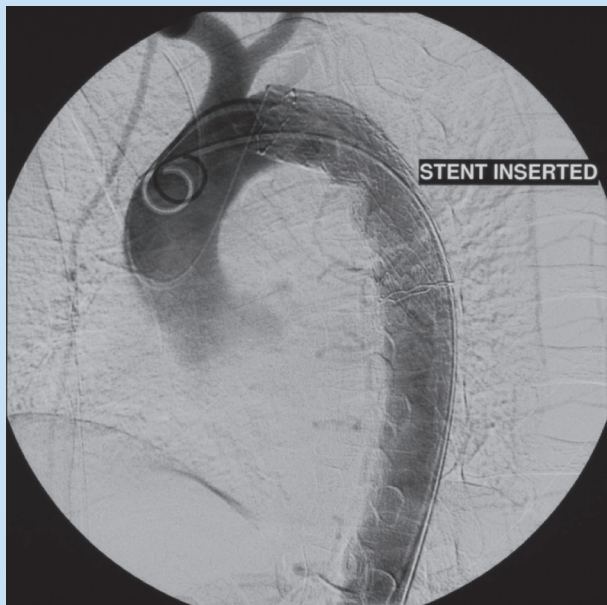


Fig. 4. Digital subtraction angiogram obtained after endovascular stent graft deployment, demonstrating complete exclusion of the pseudo-aneurysm and occlusion of the origin of the LSA.

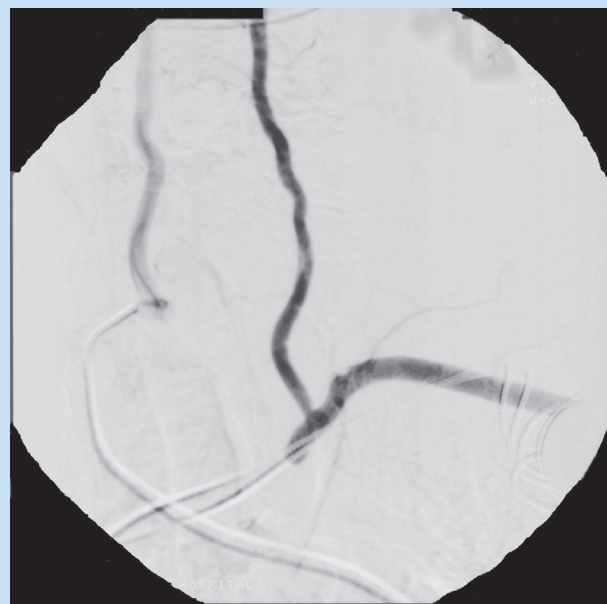

Fig. 5. Digital subtraction angiogram demonstrating LSA opacification due to retrograde flow from the left vertebral artery (as a subclavian artery steal phenomenon).

Case report

A 51-year-old taxi driver presented with significant chest pain following a high-impact motor vehicle accident. Chest X-ray demonstrated a widened mediastinum, and an urgent CT angiogram (CTA) of the chest was performed. The CTA revealed a dissection of the descending thoracic aorta distal to the origin of the left (L) subclavian artery

(Stanford B), complicated by a 4 cm long pseudo-aneurysm³ (Figs 1 and 2). An associated L haemothorax suggested leakage from the aneurysm.

The patient had a bovine-type aortic arch (i.e. the right (R) brachiocephalic artery and the L common carotid artery shared a common origin). These branches and the L subclavian artery were not involved in the dissection.

As the patient also had underlying hypertension and ischaemic heart disease, making him a poor surgical candidate, but was haemodynamically stable with no contraindication to aortic stenting, the decision was made to undertake an endovascular repair of the thoracic pseudo-aneurysm.

Endovascular procedure

The procedure was carried out under conscious sedation and local anaesthesia. The R common femoral artery was selected for deployment of the thoracic endograft (stent). An arterial cut-down was performed to obtain access for the required 20F introducer sheath. The cut-down was performed by the vascular surgical team. The previous CTA had revealed that the common femoral arteries were suitable in calibre as well as not being tortuous, so as to accommodate the introducer sheath and provide an arterial access site for the interventional procedure.

The L common femoral artery was also punctured percutaneously via a standard single-puncture needle with insertion of a 5F introducer sheath. This access site was used to perform thoracic arterial runs pre- and post-vascular stent deployment.

Pre-stent deployment thoracic aortography confirmed a large contained thoracic aorta pseudo-aneurysm originating just below the origin of the left subclavian artery (LSA) (Fig. 3). It was calculated that there was approximately 2 cm of normal aorta between the LSA and the start of the pseudo-aneurysm. At the outset, this seemed to indicate sufficient length for a good 'landing zone' to avoid any possible occlusion of the LSA. A sharply angulated curve between the aortic arch and thoracic aorta was noted, however; hence, deployment distal to the origin of the LSA would lead to excessive kinking of the stent with likely failure of the device and possible occlusion of the aorta. It was decided that the stent needed to be placed more proximally, with the risk of occluding the LSA (Fig. 4).

The thoracic aortic stent used was a Gore TAG thoracic covered endoprosthesis (stent). This required a 20F sheath introducer. The selected endoprosthesis diameter was 28 mm, with the stent length 15 cm. The stent diameter needs to be oversized relative to vessel diameter by approximately 10 - 15% to prevent migration of the stent and ensure good apposition against the vessel walls.² The stent contains an external Nitinol support structure which enables it to self-expand and provide sealing by radial force. In addition, there are sealing cuffs on both ends to prevent type 1 endovascular leaks.²

Intravenous heparin (5 000 IU) was administered prior to deployment of the stent. The delivery catheter containing the constrained stent was deployed via the introducer sheath with the proximal end of the graft occluding the LSA at the 'landing zone', as placement more distally was deemed unsuitable owing to the angulation between the aortic arch and the descending aorta. At the time of stent deployment, a 9 ml balloon was inflated to ensure adequate and complete stent expansion.

Post-deployment angiography demonstrated complete exclusion of the pseudo-aneurysm by the stent, with partial occlusion of the LSA

(Fig. 4). No endovascular leaks were demonstrated. The patient did not complain of any posterior fossa or left upper limb ischaemic symptoms post-procedure, due to adequate retrograde L vertebral and other collateral arterial flow (Fig. 5).

Discussion

There is controversy concerning the appropriate role of CT in the screening of chest trauma patients for aortic injuries, as plain radiographic findings for post-traumatic aortic rupture are nonspecific.¹ Traditional chest radiographic findings that suggest aortic injury include mediastinal widening >8 cm, loss of clarity of the aortic knob, displacement of the nasogastric tube to the right of the T4 spinous process, left apical pleural capping, widened paraspinal lines, widened right paratracheal stripe >5 mm, and loss of the descending aortic line.^{1,3} However, the value of these as positive predictive signs is poor. Most patients with mediastinal widening on chest X-ray (CXR) have normal CT findings with no mediastinal haemorrhage.¹ On the other hand, the negative predictive value of a normal CXR is high, at approximately 98%.¹

CT findings of aortic injuries include blood within the mediastinum, deformities of the aortic contour, intimal flaps, thrombus or debris protruding into the aortic lumen, the presence of a pseudo-aneurysm, or an abrupt tapering of the diameter of the descending aorta compared with the ascending aorta ('pseudocoarctation').^{1,3} Most of these aortic injuries occur at or distal to the level of the ligamentum arteriosus¹ in the aortic isthmus.

In addition to the evaluation of aortic injuries, CT demonstrates associated injuries such as subtle pneumothoraces, pneumomediastinum, lung trauma, thoracic spine fractures and other skeletal injuries. CTA of the abdomen allows evaluation of the arteries, including the diameter of the common iliac and femoral arteries and tortuosity as potential access sites for endovascular stent deployment.¹

It is well established that there is a high mortality rate for major aortic surgical repair, such as that for chronic Stanford type-B dissection which is 15%, reaching almost 40% for acute dissection.² Endovascular repair of thoracic aneurysms is emerging as an attractive alternative to surgical graft replacement in both high- and low-risk surgical patients.^{2,4} The benefit in high-risk surgical patients has already been established and, although the long-term results in low-risk patients are not known, the short-term mortality and morbidity compare favourably with that for surgery.²

The major limitations in selecting patients for endovascular repair are the lack of a suitable proximal landing zone (i.e. the aneurysm should arise at least 5 mm beyond the LSA) with 'first-generation' endovascular stents and inadequate vascular access.^{2,4} Generally, 10 - 15% oversizing of stent grafts is required to prevent migration and provide good apposition to the aortic wall. Ideally, the covered portion of stent grafts (excluding the length of the uncovered, bare extremities) should cross the lesion and at least 1.5 cm of the normal aorta at either end. Whenever possible, greater proximal and distal coverage should be used to prevent

late stent graft migration and endovascular leak due to aortic disease progression. However, a stent used for the treatment of aortic dissection may be relatively short as the goal is then simply to close the entry point.² When there is <15 mm of normal aorta between the aneurysm and the normal LSA, the covered part of the stent will have to occlude the origin of the LSA to ensure adequate length of the proximal landing zone. As described in our case report, the LSA origin would also have to be occluded when there is sharp angulation between the aortic arch and thoracic aorta such that deployment distal to the origin of the LSA would lead to excessive kinking of the stent with possible aortic occlusion.² If the LSA origin is to be occluded, a left carotid-subclavian artery bypass may be created electively beforehand if contralateral vertebral artery perfusion is inadequate or if the patient develops symptoms after stenting.² An alternative to covering the LSA would be the use of newer-generation notched or fenestrated stents.^{2,4}

Closure of the tear in post-traumatic arch rupture often occurs spontaneously after stent graft insertion. The most common complication after stent graft implantation is leakage into the aneurysm due to incomplete fixation of the stent graft to the aortic wall or due to graft defects.⁵ Other complications of endovascular repair of thoracic aortic aneurysms include expansion of the aortic tear and weakening of the aortic wall due to excessive balloon dilation of the stent graft, graft thrombosis and graft kinking.⁵ Rare complications, with reported rates of 4 - 17%, include graft occlusion caused by the inability of the stent graft to bend along the acute angle in the aortic arch, and shower embolism due to mural thrombus dispersion during repeated introduction of guide wires, angiographic catheters and delivery systems; this may cause cerebral infarction during the endovascular procedure.⁵

Conclusion

CT will remain at the forefront in the diagnosis of post-traumatic aortic rupture and for pre- and post-endovascular stent management. Good CT imaging obviates the need for invasive angiography in a significant number of patients.

Stent graft placement is proving to be a safe, minimally invasive and effective treatment for the management of post-traumatic aortic pseudo-aneurysms. The limitations of surgical repair include underlying comorbid disease, as described in our patient, whereas the major limitation to endovascular graft repair is anatomical suitability. In selected patients, short-term morbidity and mortality compare favourably with that obtained surgically.

1. Kuhlman J, Posniak M, Collins J. Radiographic and CT findings of blunt chest trauma: Aortic injuries and looking beyond them. *Radiographics* 1998; 18: 1085-1106.
2. Therasse E, Soulez G, Giroux MF, et al. Stent graft placement for the treatment of thoracic aortic diseases. *Radiographics* 2005; 25: 157-173.
3. Baron RL, Sagel RG, Stanley RJ. Computed tomography in the evaluation of mediastinal widening. *Radiology* 1981; 138: 107-113.
4. Kato N, Shimono T, Hirano T, et al. Aortic arch aneurysms, extra-anatomical bypass and endovascular stent grafting. *Cardiovasc Intervent Radiol* 2002; 25: 419-422.
5. Mita T, Arita T, Matsunaga N. Complications of endovascular repair for thoracic and abdominal aortic aneurysm: An imaging spectrum. *Radiographics* 2000; 20: 1263-1278.