

CT brain demonstration of basal ganglion calcification in adult HIV/AIDS patients

E Joseph, MB BCh, FFRad (Diag)

K Spiegel, MB BCh, FCRad Diag

Helen Joseph Hospital, Auckland Park, Johannesburg

Abstract

Involvement of the basal ganglia in AIDS encephalopathy is well documented in both adults and children. The pathology remains obscure. A type of inflammation with increased vascularity and disruption of the blood-brain barrier has been postulated. Calcification of the basal ganglia in encephalopathic HIV/AIDS children has been relatively well documented. Only two adult HIV cases with basal ganglion calcification (BGC) have been reported in the literature. At our institution over the past few years, we have noted an increasing number of adult AIDS patients with neurological complications, demonstrating BGC on CT examination. A retrospective review was done. Ninety-six adult cases were identified with BGC. Of these, 38 patients were HIV positive. Review of the 38 HIV-positive cases revealed that all of the patients presented clinically with encephalopathic symptoms, and all showed BGC associated with varying degrees of atrophy on CT scan. Reports of paediatric HIV cases with BGC and encephalopathy have suggested that the BGC is the end-stage phenomenon of a type of vasculopathy associated with blood-brain barrier disruption. The calcifications were seen to be progressive, as was the encephalopathy. The presence of BGC was deemed to be a poor prognostic indicator. Our study shows that BGC is not uncommon in AIDS encephalopathic adults. Further, since the radiological findings and clinical presentations in adults are the same as in children, we suggest that the pathological processes are also the same and that, in adults, as in children, BGC is the end-stage manifestation of an HIV vasculopathy.

Introduction

Computed axial tomographic (CT) demonstration of basal ganglion calcification (BGC) in children suffering from acquired immune deficiency syndrome (AIDS) with neurological complications, was first described by Belman *et al.*¹ in 1985. Later in 1985, Belman *et al.* reported on an additional 3 cases.² This was followed by a report in 1986, also by Belman *et al.*³ of a further 17 children, all of whom presented with progressive, ultimately fatal, encephalopathy and CT demonstration of BGC. There are only 2 reported cases of BGC in HIV-positive adults, both patients presenting with progressive dementia and eventual spastic quadriplegia.² Following the reports of BGC in children in 1985, Lantos *et al.*⁴ reviewed over 100 adult AIDS patients' CT scans, but no additional cases of adults with BGC were found. No further accounts of BGC, in either children or adults have since been reported.

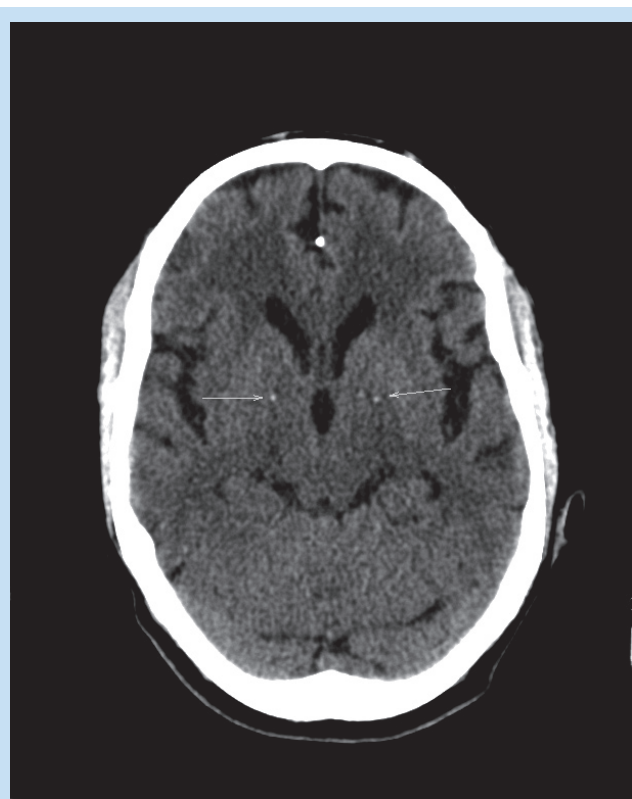


Fig. 1. Non-contrast CT scan of a 37-year-old male retroviral disease (RVD) positive patient showing basal ganglia calcification (arrows) and atrophy.

Objective

BGC is known to occur in paediatric cases of AIDS encephalopathy. The only 2 reported adult cases were drug addicts and it was unclear whether the BGC was related to the HIV disease or due to a drug-induced vasculitis.² At our institution an increasing number of adult HIV patients, presented for CT scan of the brain for neurological symptoms, were reported to have BGC. A retrospective study of these cases was undertaken. Our first aim was to confirm our suspicion that BGC in adult AIDS patients is not as uncommon as the literature implies. We also wished to document associated radiological and clinical findings with a view to finding whether there were any similarities to the reported paediatric cases.

Patients and methods

A 13-month period, January 2006 to February 2007, was selected. All reports of BGC were extracted after ethics approval had been granted. Patient files were not consistently available and clinical information was obtained from details provided on the CT scan request forms on which the reports are also written. Only those patients stated to have clinically

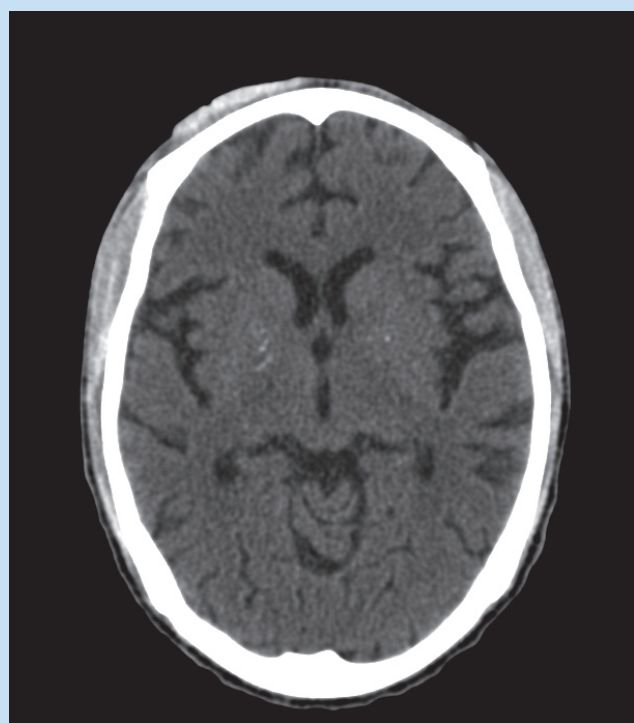


Fig. 2. Non-contrast CT scan brain of a 28-year-old RVD-positive male patient showing significant atrophy and basal ganglia calcification.

proven HIV disease were included in the study.

Results

There were 96 reported cases of BGC in both HIV-positive and HIV-negative patients over a 13-month period. The patients fell into three groups:

Group 1: 38 patients who presented with stroke or senile dementia, with no evidence of HIV disease. This group was excluded.

Group 2: 20 patients, some of whom had symptoms suggesting HIV-related disease, but their HIV status had not been proven. This group was excluded.

Group 3: 38 patients who were clinically proven to be HIV positive. These cases were reviewed for the purpose of our study.

Clinical findings

The age of the patients in the HIV-positive group varied between 20 and 59, with an average age of 38.34. All (100%) of the patients presented with confusion; 25 patients had additional neurological or psychiatric symptoms. Lumbar punctures (LP) had been performed on 20 of the 38 patients and 3 were indicative of meningitis (Table I).

Radiological findings

All patients (100%) showed bilateral, fine, punctate calcifications of the basal ganglia, associated with moderate to severe atrophy (Figs 1 and 2).

Additional findings are listed in Table II.

None of the patients suspected of having meningitis showed any radiological evidence to support the diagnosis, or to suggest the presence of an associated vasculitis. The radiological reports most frequently noted the BGC without suggesting a cause. Since there was nothing in

Table I. Clinical presentations

No. of patients	Findings
38 (100%)	Confusion
6	Confusion + seizures
7	Confusion + hemiplegia
3	Confusion + psychotic behaviour
9	Confusion + dyskinetic features
1	Confusion + cryptococcal meningitis deteriorating on treatment
1	Confusion + abnormal lumbar puncture, suspected to be tuberculous meningitis
1	Confusion + cryptococcal meningitis on lumbar puncture

Table II. Radiological findings additional to basal ganglion calcification and atrophy

No. of patients	Findings
1	Bilateral focal hypodense lesions in the head of the left caudate nucleus
1	Scattered hypodensities (at grey/white matter interface and in deep white matter)
1	Chronic subdural collections

the history provided on the patients' CT scan request forms to suggest any of the known causes of BGC, in those instances where a cause was suggested, the most frequent report was of 'idiopathic BGC'.

Discussion

The first 6 children with AIDS encephalopathy and CT-demonstrated BGC were reported by Belman *et al.*¹ in 1985. They were followed up for a period of 14 months using CT imaging.¹ CT examinations showed progressive cortical atrophy with ventricular dilatation and BGC. Postmortems were done on 3 of the children. All showed a calcific vasculopathy of the basal ganglia in addition to other degenerative changes. One case in addition was shown to have cytomegalovirus encephalitis.

Later in 1985 Belman *et al.*² reported BGC in 3 children and 2 adults with HIV. The paediatric cases all showed progressive calcification on serial CT examination. None of the cases had evidence of endocrinopathy or mitochondrial cytopathy. Postmortem studies on 1 child and 1 adult showed calcification of small and large vessels of the basal ganglia, with no evidence of inflammatory change.

In 1986 Belman *et al.*³ reported 8 and then 9 paediatric cases of CT-demonstrated BGC where none of these cases had any evidence of opportunistic brain infection. Postmortem studies on 4 of the cases showed variable degrees of calcification of vessels of the basal ganglia. Punctate capillary changes with focal deposits in the walls of small vessels were the most frequent form of calcification although larger vessels were occasionally involved. MRI studies done at the same time as CT imaging on these cases, when the BGC was still mild, showed features of oedema or inflammation consistent with disruption of the blood-brain barrier within the basal ganglia. The authors postulated, on the basis of the CT and MRI imaging and subsequent postmortem findings, that

there was an acquired vascular insult with calcium deposition as an end-stage phenomenon. Serial studies showed a progression of the calcification as well as the atrophy.³

In 1998 Melzer *et al.*⁵ published a retrospective review of MRI studies on 9 adult HIV cases with neurological complications. The MRI studies showed symmetrical bilateral caudate nuclei punctuate hyperintensities on T2-weighted imaging. All the above patients presented with new onset seizures or a change in mental state. Postmortem studies on 2 of these patients showed neuro-infarcts in a distribution similar to the MR abnormalities. The proposal was that the hyperintensities represented ischaemic tissue injury. It was noted however that 7 of the 9 patients were drug abusers, and it was unclear what contribution this made to the findings.

In 2000 Berger *et al.*⁶ studied early and late enhancement patterns of the basal ganglia in adult AIDS demented and non-demented patients using MRI. They found increased early enhancement as well as an increase in late enhancement in the basal ganglia in the demented as compared with the non-demented group. They concluded that the increased early enhancement shown in the demented group indicated increased regional cerebral blood flow, and an increase in late enhancement in the same group suggested disruption of the blood-brain barrier.

There is no doubt as to the importance of the basal ganglia in HIV/AIDS encephalopathy in both adults and children. It is known that the HIV virus enters the CNS early in the course of infection and that the virus shows a preference for the basal ganglia.^{5,7} Basal ganglion dysfunction is thought to be a major contributing factor in the development of HIV dementia.^{6,9} The exact pathology remains obscure. A type of inflammation with increased vascularity and disruption of the blood-brain barrier has been postulated.^{6,9} It is thought that the BGC is an end stage of a vasculopathic process which itself is not due to other infections or a true vasculitis. In those paediatric cases that were followed up, the calcifications were progressive, as was the encephalopathy, ending with the patients' eventual demise.¹⁻³ Since only 2 adult HIV-positive cases of BGC have been reported, it was suggested that the reason for BGC being more common in paediatric encephalopathic AIDS patients was the greater vulnerability of the immature neural system and blood-brain barrier. Furthermore the 2 adult BGC cases reported were drug abusers, raising the possibility that the drugs may have been responsible for disrupting the blood-brain barrier and causing the BGC.

Patients with BGC in group 1 of our study, sent for investigation of stroke or dementia, were aged between 57 and 92, with average age of 72. There was no evidence to suggest HIV pathology in the group, and the BGC was most likely to be age related.

The patients in group 2 had an age variation between 35 and 60, with average age of 43. Of these 1 was an alcoholic patient, 1 was a drug addict, 2 suffered renal failure and 2 sustained a head injury. The remaining 14 cases were thought to be HIV positive, but this was not proven. Their main presenting symptom and reason for the CT request was confusion. It is unlikely that the BGC in this group was age related. Renal failure and drug-abuse-induced vasculitis could account for the

BGC in 3 of the patients in this group.

In our study group (group 3), the average age was 38, varying between 20 and 59. There were no drug abuse cases and only 3 cases showed clinical evidence of meningitis (without radiological correlation). All our cases showed BGC and atrophy, associated with encephalopathy of variable degree. The previous studies of HIV-positive paediatric cases with the same clinical and radiological findings have been evaluated as being due to a vasculopathy associated with disruption of the blood-brain barrier, with the calcifications being an end-stage phenomenon and a poor prognostic indicator. We propose that the pathological process in adults is the same.

Conclusion

There have been only 2 reported cases of BGC in encephalopathic adult AIDS patients in the literature. We have reported on 38 cases of adult AIDS patients with encephalopathic symptoms, who have CT-demonstrated BGC and atrophy – the same findings as have been reported in children. In view of our results, the absence of reports of BGC in adult encephalopathic AIDS patients is puzzling. Possibly fine punctate calcifications have been missed, or are disregarded as 'idiopathic'. Additionally, our assumption is that the pathology in adults is the same as that seen in children (with AIDS encephalopathy and BGC), and that BGC in encephalopathic adult AIDS patients represents the end stages of an acquired vasculopathy. In children, BGC is regarded as an indicator of poor prognosis. Further studies would be required to confirm this in adults.

Addendum note

Since the date of completion of our review, we have seen 24 more cases of HIV patients with encephalopathic symptoms showing BGC on CT examination. Eleven of these patients showed BGC with atrophic changes only. In addition to the BGC and atrophy, 13 patients had various other findings including hydrocephalus, old infarctions and ring-enhancing lesions.

1. Belman AL, Ultmann MH, Haroupian D *et al.* Neurological complications in infants and children with acquired immune deficiency syndrome. *Ann Neurol* 1985; 18: 560-566.
2. Belman AL, Lantos G, Horoupian D, *et al.* Basal ganglia calcification in patients with AIDS. *Neurology* 1985; 35(suppl 1), 308.
3. Belman AL, Lantos G, Horoupian D, *et al.* AIDS: Calcification of the basal ganglia in infants and children. *Neurology* 1986; 36: 1192-1199.
4. Lantos G, Schonberger ER, Leeds NE, *et al.* Head CT in patients with acquired immune deficiency syndrome. *AJNR* 1985; 6: 470.
5. Meltzer CC, Wells SW, Becher MW, *et al.* AIDS related hyperintensity of the basal ganglia. *AJNR* 1998; 19: 83-89.
6. Berger JR, Nath A, Greenberg R, *et al.* Cerebrovascular changes in the basal ganglia with HIV dementia. *Neurology* 2000; 54: 921-926.
7. Jreismana GJ, Kaplina AI. Depression cognitive impairment: neurological and psychological complications in HIV and anti-retroviral drugs. *AIDS* 2002; 16: 1201-1215.
8. Ghafouri M, Athius S, Khalili K, Sawaya B. HIV-1 associated dementia: symptoms and causes. *Retrovirology* 2006; 3: 28.
9. Hanna L (associate editor BETA). HIV/AIDS in children: overview and guidelines for disease management. *Bulletin of Experimental Treatment for AIDS*, June 1996; no.29 [http://www.oegis.com/pub/beta/1996/BE962905.html] Date last accessed: 20 October 2007.