

Comparison of barium and gastrograffin swallow for radiation therapy planning in carcinoma of the oesophagus

V Sharma, MD, PhD

D N Gumbi, Dip (RD), B Tech (RT)

M Mbhele, NDip (RD), NDip (RT)

B Donde, MMed Rad (T)

Department of Radiation Oncology, Johannesburg Hospital and University of the Witwatersrand, Johannesburg

Abstract

Background. Simulation of patients with carcinoma of the oesophagus using radio-opaque contrast is a standard step in treatment planning prior to delivering radiation therapy. Various contrast mediums such as barium, gastrograffin and hexabrix have been used for simulation at different centres.

Objective. The purpose of the study was to compare barium and gastrograffin as a useful and cost-effective contrast medium in simulation for delineation of site and length of the lesion.

Materials and methods. Fifteen patients accepted for radiation therapy underwent simulation using oral barium and gastrograffin swallows prior to treatment. The amount of contrast material used was recorded for both the procedures. The X-rays were taken with both contrast agents keeping the same exposure factors.

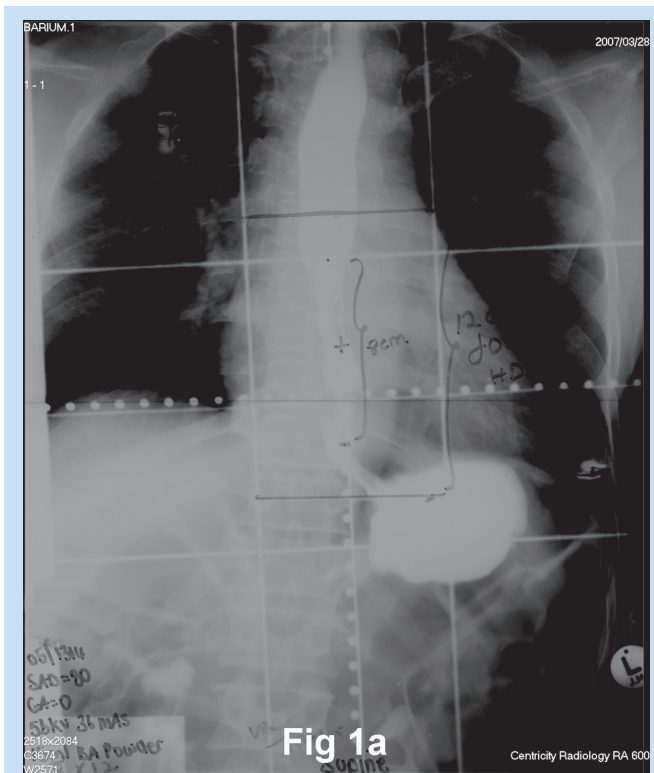


Fig. 1a. Simulator film with barium as a contrast.

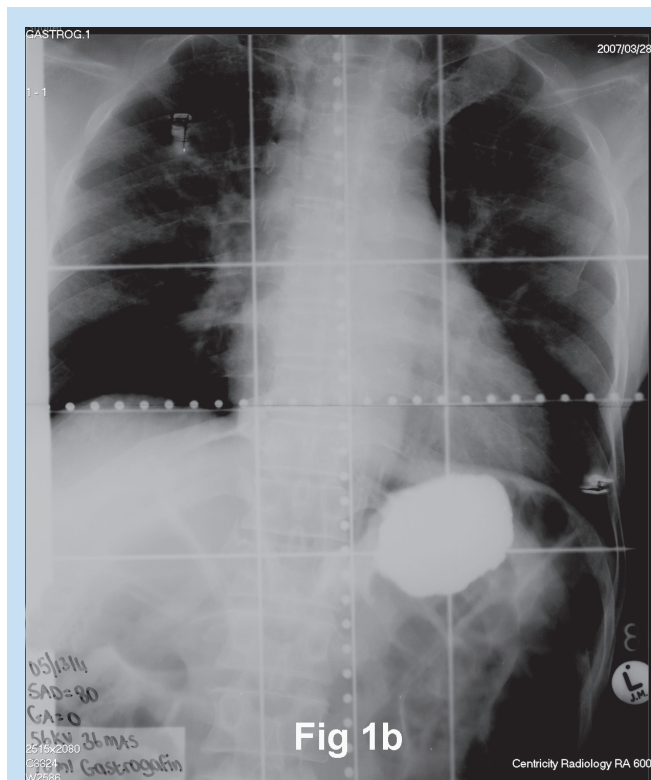


Fig. 1b. Simulator film with gastrograffin as a contrast.

Results. The mean amount of barium used was 14 ml (range 10 - 20 ml) as compared to 27.66 ml of gastrograffin (range 10 - 70 ml). The mean cost per patient was R4.40 for barium as against R70.80 for gastrograffin. No aspiration of contrast was noted in any patient. The opacification and delineation of the lesion on the X-ray films was much better with barium.

Conclusion. Barium is a better contrast medium in simulation for delineation of lesion length and treatment planning compared with gastrograffin. It is also cost effective. This comparison has changed the practice in our department, and it is recommended that it be evaluated by other centres.

Introduction

Patients with carcinoma of the oesophagus are commonly treated with radiation therapy with or without chemotherapy (curative treatment), and with external beam radiation (palliative treatment).¹ Intraluminal radiation is used for palliation as well as in combination with external beam radiation for radical treatments.^{2,3} Patients are planned for treatment on a simulator using radio-opaque contrast to delineate the exact site and length of the lesion for accurate field placement during external beam radiation, as well as to delineate the placement of brachytherapy

sources during intraluminal radiation therapy.⁴ This forms an essential part of the treatment planning so that high dose can be delivered to the tumour and the critical surrounding structures can be spared. Approximately 150 - 175 patients with carcinoma of the oesophagus receive radiation therapy in our department every year. The standard contrast medium used in our department for the simulation procedure is gastrograffin. The purpose of this prospective study was to compare barium sulphate and gastrograffin as two contrast mediums in simulation for delineation of exact site and length of lesion and to analyse the cost of the materials used.

Materials and methods

Fifteen patients with carcinoma of the oesophagus accepted for radiation therapy at the Department of Radiation Oncology, Johannesburg Hospital were included in this study. The radiographer explained the procedure to the patients prior to the simulation, and informed consent was obtained. Barium sulphate is available in powder and liquid forms, and gastrograffin is available as a solution. Their constituents and characteristics are shown in Table I.

A solution of the barium sulphate was reconstituted at the time of the procedure by mixing the powder with water. Gastrograffin was used in the available solution form. Patients were given gastrograffin to swallow, and if on screening the physician was unable to delineate the lesion accurately, more contrast was given. Once satisfied, an X-ray was taken. This procedure was then repeated with barium. The exposure factors of KV (kilovoltage) and MAS (milliamperes) were kept similar for both the barium and gastrograffin contrast (Figs 1a and b, Figs 2a and b) to limit bias due to different exposure factors. The amount of contrast medium used was recorded by the radiographer.

Results

The mean amounts of barium and gastrograffin used were 14 ml (10 - 20 ml) and 27.66 ml (10 - 70 ml) respectively. The paired sample *t*-test done showed a significant difference in favour of barium ($p = 0.00$). Ten of the 15 patients (67%) needed more gastrograffin, with the amount ranging from 10 ml to 55 ml. The cost per patient was R4.40 for barium versus R70.80 for gastrograffin as per the cost of the available packs (340 g barium powder container for R108, and 100 ml bottle of gastrograffin for R256). The projected cost calculated for 150 patients was R667 for barium and R1 0623 for gastrograffin for 1 year, leading to a cost saving of R9 956.

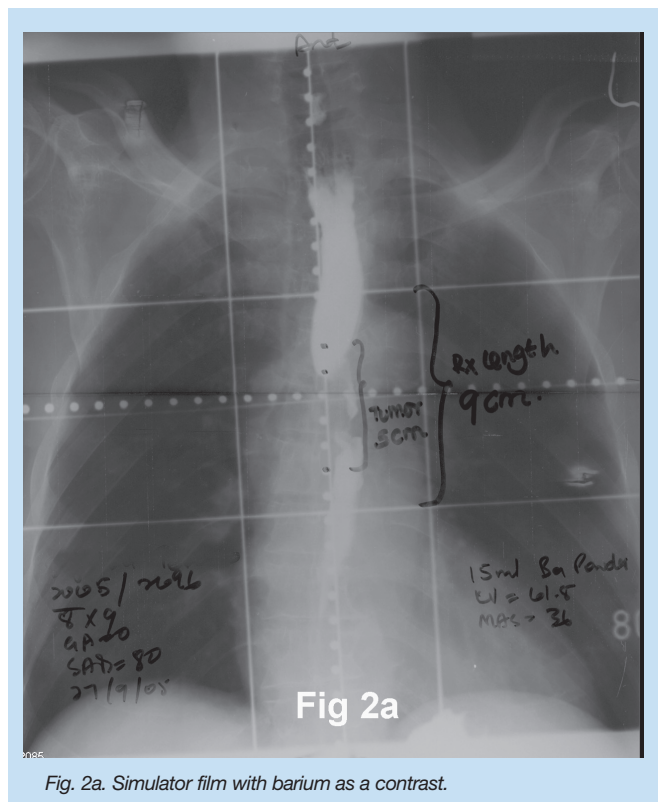


Fig. 2a. Simulator film with barium as a contrast.

Barium was more accurate in evaluating lesion length and site, demonstrating filling defects and greater opacification in 7 patients (47%) whereas results were similar to gastrograffin in 8 patients.

Discussion

Patients with carcinoma of the oesophagus receive radiation therapy either with external beam or with intra-luminal brachytherapy.^{2,3} The treatment planning with simulation using contrast forms an essential component of the radiation therapy treatment. Gastrograffin has been used for diagnosis of dissecting intramural haematoma in patients with carcinoma of the oesophagus following chemotherapy⁵ as well as to rule out the leaks following surgery.⁶ Levine *et al.*⁷ reported 96% accuracy in diagnosing or suspecting a diagnosis of carcinoma of the oesophagus using barium as contrast medium.

Ginsberg and Fleischer⁸ suggest that barium is the preferred con-

Table I. Comparison of characteristics of contrast agents used

Contrast	Barium	Gastrograffin
Composition	100 g contains 98 g barium sulphate	Mixture of sodium and meglumine amidotrizoate 100 ml contains 76 g contrast Iodine content: 37 g/100 ml
Action	Insoluble, eliminated unchanged	Only 3% absorbed, eliminated mainly via kidneys
Indications	Double contrast radiography of GIT	Visualisation of GIT fistulae/tumour prior to endoscopy
Side-effects	Granuloma formation or pneumonitis	Pulmonary oedema
Cost	R108 for 340 g	R256 for 100 ml

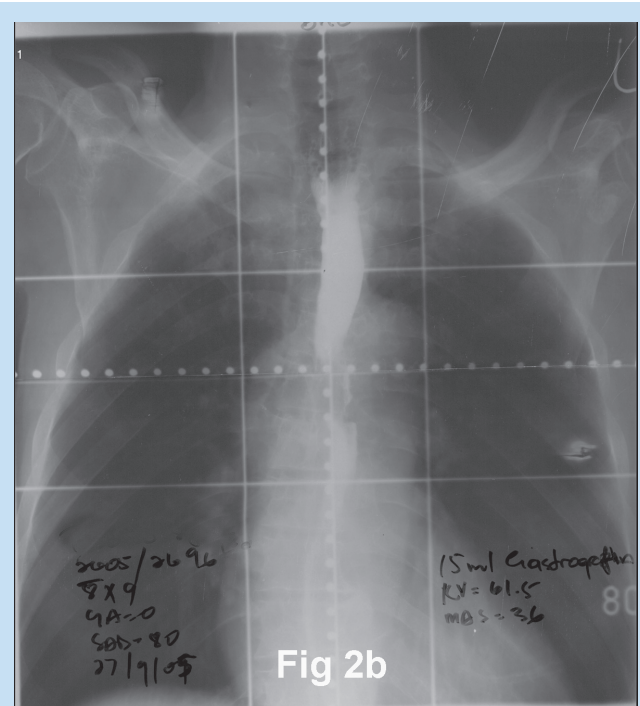


Fig. 2b. Simulator film with gastrograffin as a contrast.

trast agent for carcinoma of the oesophagus as opposed to gastrograffin which may cause pulmonary inflammation or oedema if it enters the airway via aspiration or a fistula. The main complication of barium aspiration is granuloma formation. In the present study, barium was more accurate in evaluating lesion length and site, demonstrating filling defects as well as greater opacification in 7 patients (47%) whereas results were similar in 8 patients. This was measured by comparing the contrast on the X-ray films. It was not possible to outline the lesion in

1 patient with gastrograffin, and a longer length was used in 1 patient for treatment due to poor opacification by the treating physician. More gastrograffin was required compared with barium, probably because the liquid passes more quickly through the oesophagus during fluoroscopy and X-rays. Frequently additional films need to be taken when using gastrograffin. In addition gastrograffin is less radio-opaque, making accurate definition of the lesion more difficult. There was no evidence of aspiration in any patient with either contrast agent.

It was not possible to find any articles analysing the cost effectiveness of the contrast materials such as barium and gastrograffin during the review of the literature. This study indicates that barium was a more cost-effective contrast medium than gastrograffin for the evaluation of carcinoma of the oesophagus.

Conclusion

Compared with gastrograffin, barium proved to be a useful and cost-effective contrast in treatment planning for carcinoma of the oesophagus patients prior to radiation therapy.

1. Cooper SJ, Guo DM, Herskovic A, *et al*. Chemo-radiotherapy of locally advanced esophageal cancer – Long-term follow-up of a prospective randomized trial (RTOG 85-01). *JAMA* 1999; 281:1623-1627.
2. Sharma V, Agarwal JP, Dinshaw KA, *et al*. Late oesophageal toxicity using a combination of external beam radiation, intraluminal brachytherapy and 5-fluorouracil infusion in carcinoma of the oesophagus. *Dis Esophagus* 2000; 13: 219-225.
3. Sharma V, Mahantshetty U, Dinshaw KA, *et al*. Palliation of advanced / recurrent oesophageal carcinoma with high dose rate brachytherapy. *Int J Radiat Oncol Biol Phys* 2002; 52: 310-315.
4. Sharma V, Donde B, Mohiuddin M, *et al*. Vertebral height as measurement for lesion length in carcinoma of the oesophagus – is it accurate? *South African Journal of Radiology* 2004; 8(1): 31-33.
5. George R, Govindraj R, Das SK, *et al*. Dissecting intramural haematoma in oesophageal carcinoma. *Indian J Gastroenterol* 2004; 23: 221-222.
6. Nishihira T, Watanabe T, Ohm N, *et al*. Long term evaluation of patients treated by radical operation for carcinoma of thoracic oesophagus. *World J Surg* 1984; 8:778-785.
7. Levine MS, Chu P, Furth EE, *et al*. Carcinoma of the oesophagus and esophago-gastric junction – sensitivity of radiographic diagnosis. *Am J Roentgenol* 1997; 168:1423-1426.
8. Ginsberg GG, Fleischer DE. Tumours of the oesophagus: In: Feldman M, Friedman Land Brandt L, eds. *Gastrointestinal and Liver Disease*. Vol 1. Philadelphia: Elsevier, Saunders; 2006: 949-978.