

## Botryomycosis

**J Z Makama, MB ChB**  
**N Khan, MB BS, FCRad (D) SA**  
**N Z Makhanya, MB ChB**

Department of Diagnostic Radiology, University of Limpopo, Medunsa Campus

**H Motswaledi, MB ChB, MMed (Derm), FCDerm**

Department of Dermatology, University of Limpopo, Medunsa Campus

Botryomycosis is a rare condition that involves the skin and viscera. It is multifactorial in its development, characterised by granulomatous bacterial infection. The organisms form granules composed of bacterial masses that are adhered to each other. We present a case of botryomycosis with calvarial destruction.

### Case report

A 53-year-old woman presented with a slow-growing mass lesion on the right temporal area. The lesion had started about 14 years previously as a small nodule. There were no other associated complaints at that time. There was a history of being assaulted on the head 17 years prior to the presentation, for which the patient underwent craniotomy.

On examination, there was a nodular fungating mass overlying the right temporal area with draining sinuses. Vital signs were normal. Systemic examination did not reveal anything of note.

### Investigations

Full blood count showed normochromic, normocytic anaemia. The patient had a haemoglobin level of 10.8 g/dl and was HIV-negative. Blood cultures were also negative. On tissue culture, there were coagulase-negative staphylococci, *Klebsiella pneumoniae*, and staphylococci group D.

Chest X-ray was normal. A skull X-ray was performed (Fig. 1), which showed a right frontal bone defect. An axial computed tomography (CT) scan of the brain performed with contrast (Figs 2 and 3) revealed an obvious right frontal bone defect with irregular margins. An associated soft-tissue mass was noted involving the right fronto-parietal area with an associated intracranial component. The mass had a sinus containing air running across it. There was post-contrast dense homogeneous enhancement of both the extra- and intracranial components of the mass. There was an area of hypodensity in the right frontal lobe in keeping with gliosis secondary to the old insult.

An assessment of botryomycosis was made. Actinomycosis was also a considered differential diagnosis. The patient was further sent to plastic surgeons for incisional biopsy. Results came back as botryomycosis.

### Discussion

Botryomycosis was first reported in 1870. It occurred in a horse as a result of post-castration complications which later spread to the lungs. *Les formes actinomycotiques du staphylocoque*, the first paper published on botryomycosis involvement in humans, appeared in 1914 - 1919.<sup>1,2</sup> It stated that the causal agent was *Staphylococcus aureus*. Contrary to initial

thoughts on the subject, the granules were not composed of mycotic masses, but were composed of bacteria that adhered to each other.

Despite the fact that the term botryomycosis is not appropriate as it implies a fungal and not a bacterial infection, it is the term most accepted in the literature. Botryomycosis is caused by multiple bacteria, with *S. aureus* usually the major causal agent (approximately 40%) and *Pseudomonas aeruginosa* ranking second in frequency (approximately 20%) (Table I).<sup>1</sup>

The pathogenesis of botryomycosis is not well known. It is associated with defects of cellular immunity, particularly with low lymphocyte counts.<sup>1,3</sup> Botryomycosis requires a delicate balance between the number of microorganisms inoculated, their low virulence and the host's tissue response, for it to occur.<sup>1-3</sup>

With a relative impairment of cellular immunity, all of these conditions result in a sort of 'symbiosis' between the two. The major predisposing factors are skin trauma, postoperative complications, diabetes mellitus, liver disorders, treatment with steroids,<sup>1,4</sup> alcoholism and cystic fibrosis.<sup>1,3,5</sup> Less common factors are malnutrition, glomerulonephritis, AIDS, and bronchial asthma.<sup>1</sup>

The condition may present in cutaneous or visceral form. In the cutaneous form, patients present with a suppurative, granulomatous and usually chronic condition, as in our patient. It may be initiated by trauma.<sup>1</sup> Most cases present with nodules, sinuses (also similar to our patient), fistulae, abscesses and ulcers with purulent secretions. In the visceral variety, it occurs in surgical patients, in those undergoing prolonged hospital stay, or in immunosuppressed patients. It is mostly localised in the lungs.

### Differential diagnosis

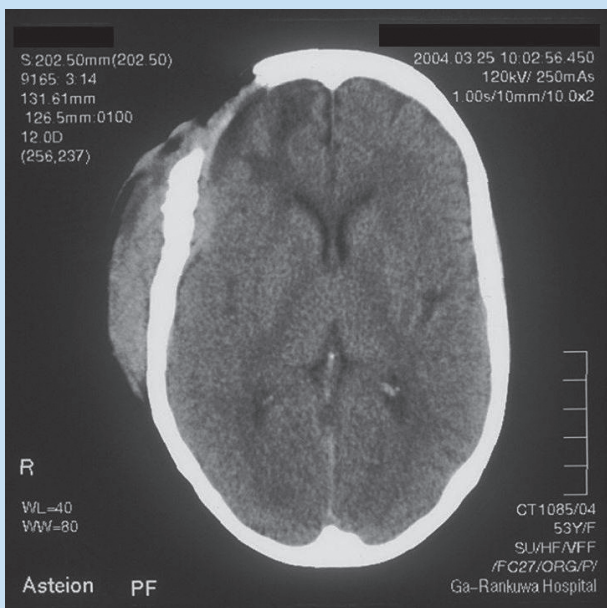
Botryomycosis of the skin should be differentiated from mycetoma, actinomycosis, abscesses, and tuberculosis. It also depends on the site of infection. Treatment depends on the causal microorganism isolated.

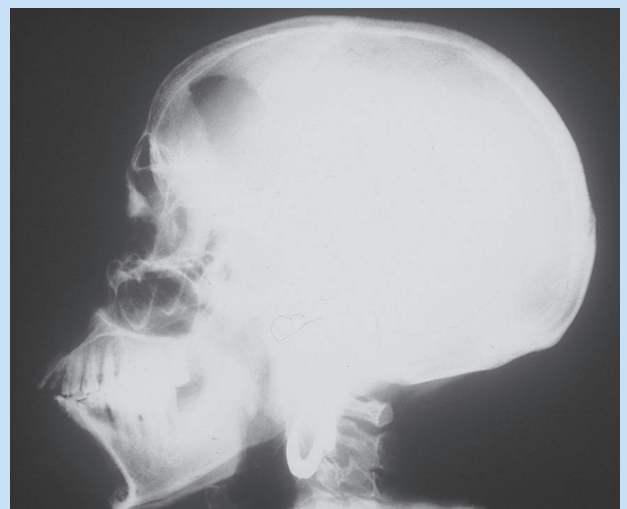

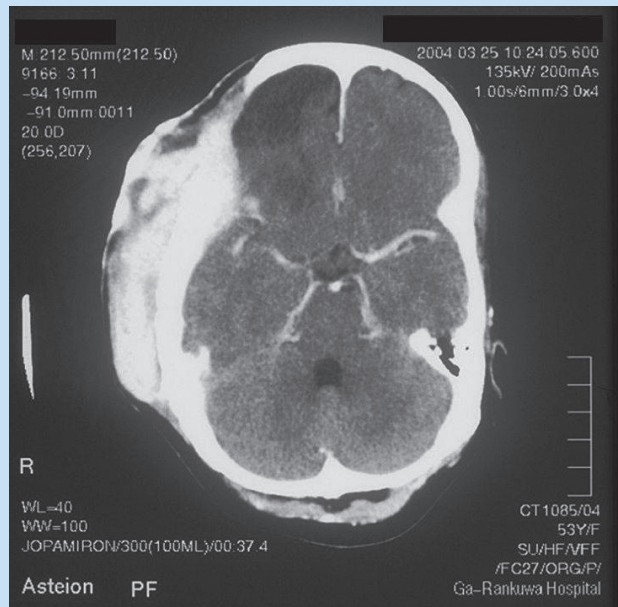
Fig. 1. Lateral skull X-ray: a right frontal bone defect.

**Table I. Incidence of causal organisms**

Aetiology	%
<i>Staphylococcus aureus</i>	42.9
<i>Pseudomonas aeruginosa</i>	19.9
<i>Micrococcus pyogenes</i>	7.2
<i>Streptococcus</i> spp.	4.8
<i>Escherichia coli</i>	3.6
<i>Staphylococcus epidermidis</i>	2.4
<i>Proteus vulgaris</i>	2.4
<i>Propionibacterium acnes</i>	2.4
<i>Pseudomonas cepacia</i>	1.1
<i>Neisseria</i> spp.	1.1
<i>Neisseria mucosa</i>	1.1



**Fig. 2. Non-contrast axial CT scan: right fronto-parietal soft-tissue mass, with an intracranial component. The scan also confirmed the bone defect.**



**Fig. 3. Post-contrast axial CT scan: dense homogeneous enhancement of both the extra- and intracranial components of the mass.**

## Conclusion

Botryomycosis is a rare condition, but the infection rate appears to be increasing. Cases may still be missed or mistakenly identified, mainly confused with fungal infections. It is advised that when a patient presents, all investigations be correlated to reach the proper diagnosis.

1. Bonifaz A, Carrasco E, Botryomycosis. *Int J Dermatol* 1996; **35**: 381-388.
2. Findlay GH, Vismar HF. Botryomycosis, some African cases. *Int J Dermatol* 1990; **29**: 340-344.
3. Brunken CR, Lichon-Chao N, van der Broek H. Immunologic abnormalities in botryomycosis. *J Am Acad Dermatol* 1983; **9**: 428-434.
4. Schlossberg D, Kerney GE, Lifton LJ, Azizhkan RG. Anaerobic botryomycosis. *J Clin Microbiol* 1980; **11**: 184-185.
5. Wu WQ, Cattaneo EA, Lapi A, Halde C. Botryomycosis: First report of human brain involvement. *South Med J* 1978; **71**: 1530-1533.