

Diabetic mastopathy – clinical and mammographic findings

I J Movson

MB ChB, DMRD (UK)

*Department of Radiology
Addington Hospital,
Durban*

I Buccimazza

MB ChB, FCS (SA)

*Department General Surgery
Addington Hospital,
Durban*

Abstract

Fibrous mastopathy is a condition seen mainly in premenopausal, insulin-dependent diabetics. The condition simulates breast cancer and is often poorly recognised. One of the main reasons for reporting this well-described entity is to make radiologists and surgeons more aware of this condition, thereby reducing unnecessary morbidity by establishing a correct diagnosis more efficiently, and differentiating it from breast carcinoma.

Case report

Case 1

A premenopausal 49-year-old woman with no risks for breast cancer, no history of trauma, and with a history of previous biopsies of both breasts presented with a 6-month history of a lump in the left breast.

The patient had been diabetic for more than 25 years, on insulin and oral hypoglycaemic agents (OHAs). There was a history of poor glycaemic control, with end-organ involvement, and renal impairment.

Clinically rock-hard solid lesions were palpated in the lateral aspect of the left breast.

The mammogram showed an increased ill-defined density in the left upper outer

quadrant (Figs 1a,b). No focal lesion was identified at ultrasound. Fine needle aspiration cytology (FNAC), core needle biopsy (CNB), could not be undertaken because

the tissue was too fibrotic to biopsy. The incision biopsy revealed diabetic mastopathy.

Case 2

A 53-year-old nulliparous patient with no history of trauma who had been post-menopausal for 4 years presented with a history of a lump in the right breast for a period of 8 months.

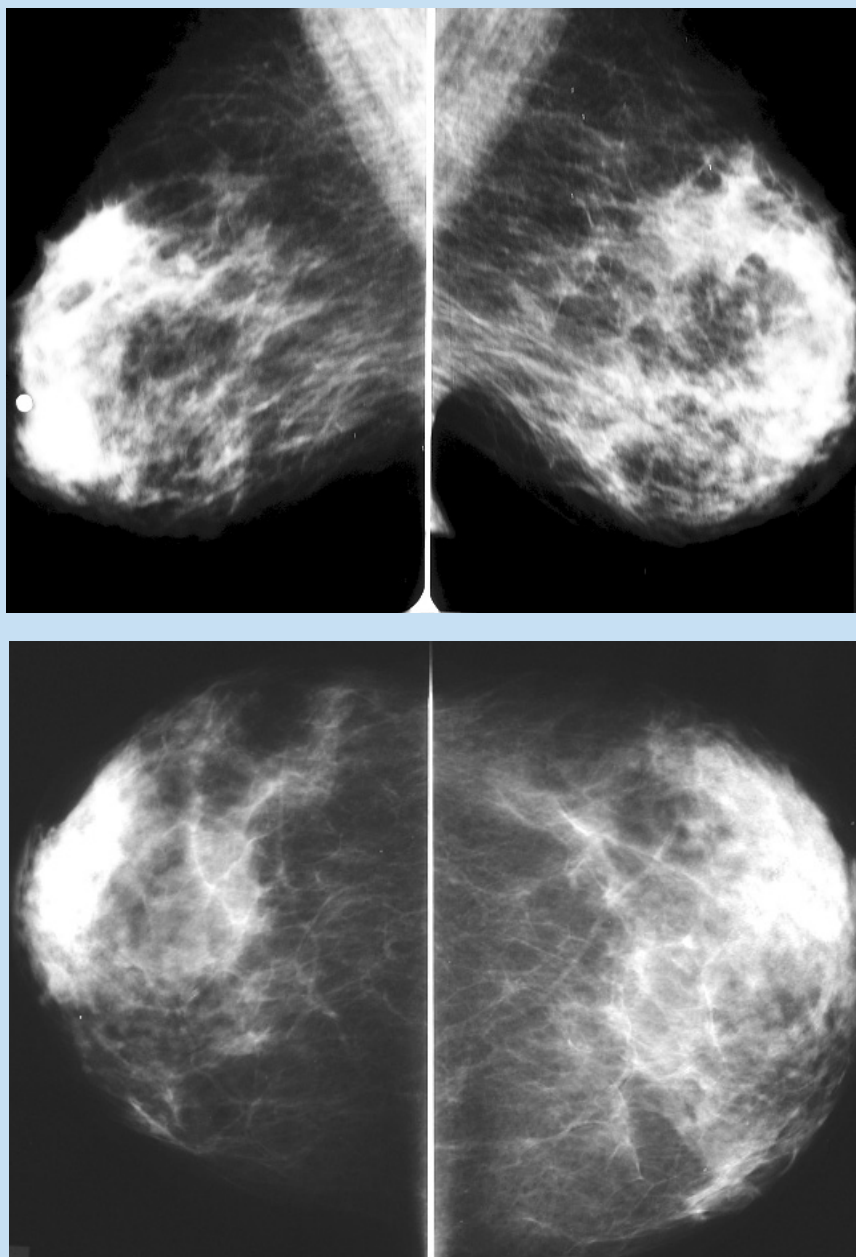


Fig. 1a,b. Mediolateral and craniocaudal mammograms of case 1 demonstrate nonspecific increased density in the upper outer quadrant of the left breast.

The patient had been diabetic for more than 10 years on OHA and insulin. Clinically both breasts had a very dense fibroglandular pattern, making it difficult to identify the palpable lesion on the mammogram, although the right breast was denser than the left (Figs 2a,b). The patient had also had a breast abscess drained on the left side 4 years previously.

The ultrasound examination revealed 2 poorly defined hypo-echoic masses 4.3 cm x 3.2 cm and 3 x 3 cm on the right side and similar masses at 5 o'clock and 12 o'clock on the left side (Fig. 2c). The incision biopsy of both breasts revealed diabetic mastopathy.

Case 3

A 60-year-old nulliparous, post-menopausal woman with no previous history of breast problems presented with a lump in the right breast. The patient was also being treated with insulin and OHA.

Clinically a 5 x 6 cm diameter lump was palpated at 12 o'clock on the right side, and a 2.7 cm x 2.7 cm diameter lump was palpated in the left upper outer quadrant.

The mammogram demonstrated areas of increased density in both breasts requiring biopsy to exclude malignancy.

The ultrasound examination revealed ill-defined lesions in both breasts with irregular margins and posterior acoustic shadowing suggesting non-benign lesions (Fig. 3).

A Sestamibi scan was undertaken and there were no focal areas of increased uptake bilaterally. FNAC revealed fat necrosis on both sides. CNB revealed fat necrosis on the right side and hyalinised fibro-fatty connective tissue with no evidence of malignancy.

Incision biopsies of both breasts revealed fat necrosis and extensive hyalinised fibrosis.

Discussion

According to the breast pathology textbook by Paul Peter Rosen¹ most of all reported examples, with two exceptions of diabetic mastopathy, have been in females, and most patients were younger than 30 years of age. All the cases were type I

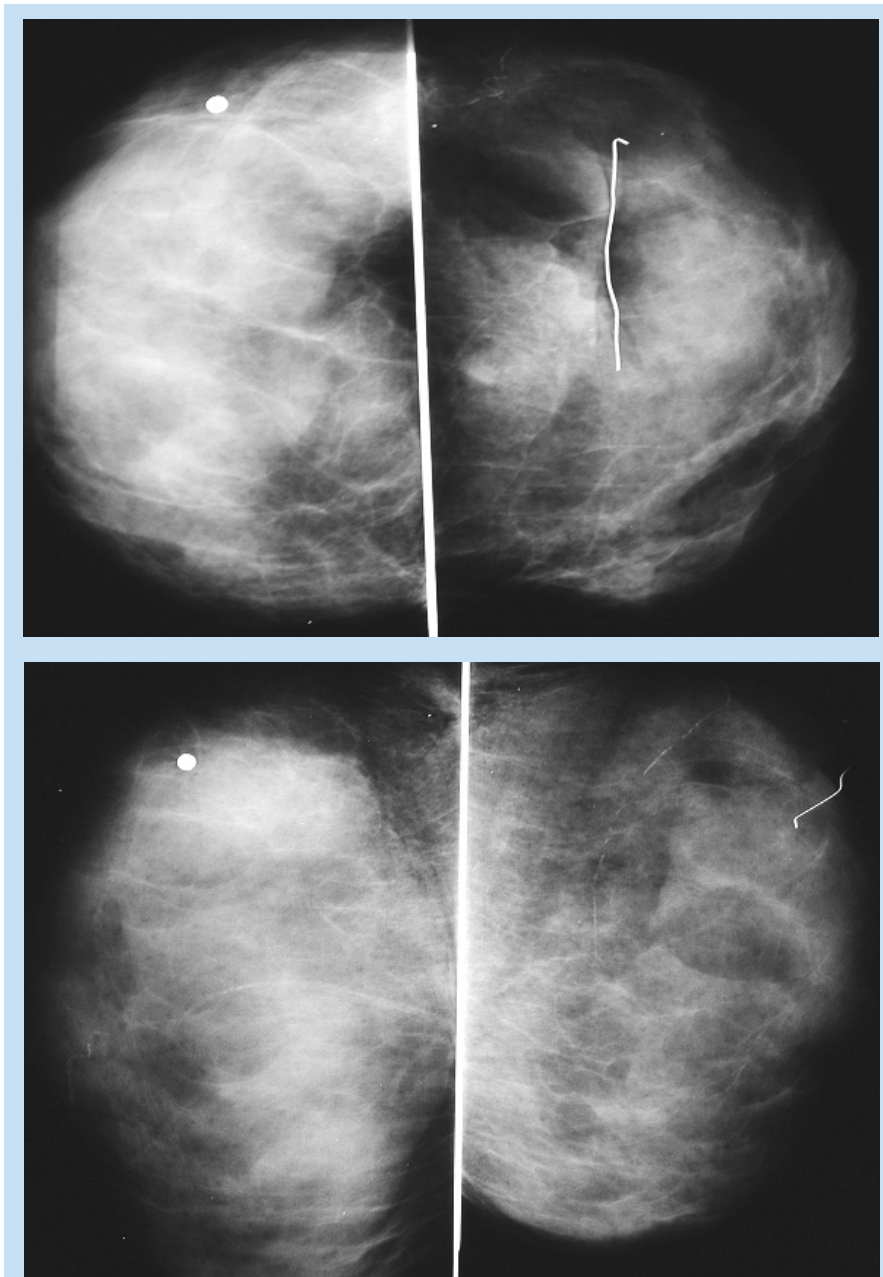


Fig. 2a,b. Craniocaudal and mediolateral mammograms of case 2 demonstrate diffusely dense breasts. The left marker outlines the scar from the abscess drainage site.

insulin-dependent diabetics.¹

Our 3 patients were aged 49, 53 and 60 years.

There is no evidence to suggest that this condition predisposes to the development of breast cancer. Most patients with diabetic mastopathy also have complications such as retinopathy, neuropathy and nephropathy.^{2,4}

According to Camuto *et al.*⁵ approximately 60% of diabetic mastopathy tends

to be bilateral or to recur after surgical excision. According to them recurrence tends to be in the same location and involves more breast tissue than the preceding lesion. They suggest that surgical biopsy should not be considered.

CNB under ultrasound guidance avoids unnecessary surgical procedures.

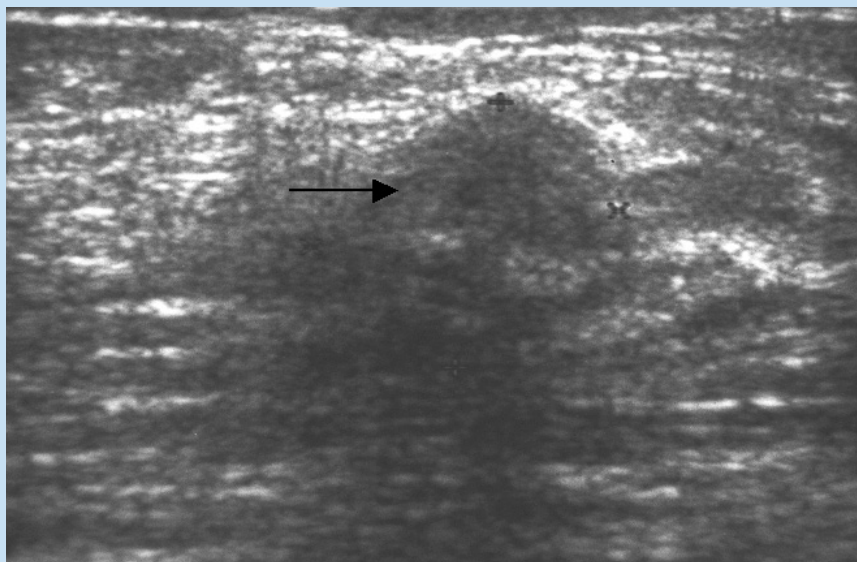


Fig. 2c. Ultrasound of the left breast demonstrates a 3 cm diameter hyperechoic mass (arrow) that was confirmed to be fibrous mastopathy on biopsy.

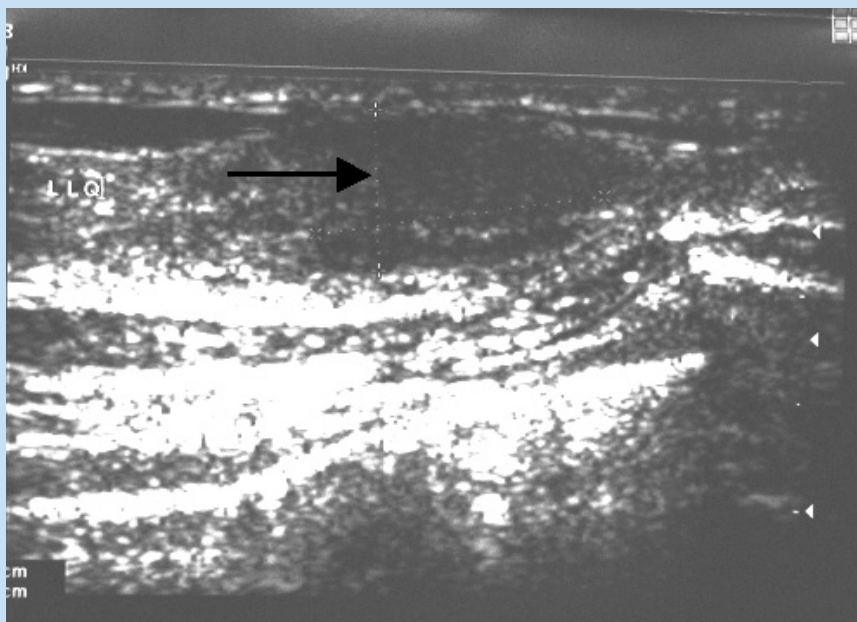


Fig. 3. Ultrasound of the left breast demonstrates an ill-defined irregular hyperechoic lesion suggesting malignancy (arrow).

Summary of main points in relation to this relatively rare entity

1. This condition is seen mainly in premenopausal longstanding insulin-dependent female diabetics.

2. The condition presents as hard masses in one or both breasts simulating carcinoma of the breast.

3. The mammogram demonstrates areas of ill-defined increased density, difficult to differentiate from carcinoma.

4. Sonography demonstrates a hyperechoic solid mass with poor margins and well-marked acoustic shadowing.

5. MRI was seldom used in most reported cases of diabetic mastopathy. Wong and associates⁶ reported early and strong enhancement of contrast medium at the area of the palpable mass in a few cases when MRI was used. Yet others reported poor enhancement in the early phase. MR spectroscopy has been used to confirm benignity of lesions in recent cases reports.⁷

6. FNA is usually unsuccessful in diagnosing the condition as resistance of the mass to the needle motion is very high. CNB can be useful in the diagnosis of recurrent lesions on follow-up, but the hard tissue often makes this procedure unsuccessful. A definite diagnosis was achieved in most cases by open surgical biopsy.

The authors thank Cornelia Harmse for typing and setting out this manuscript.

References

1. Rosen PP. *Textbook of Breast Pathology*. Lippincott, 1999: 347.
2. Soler NG, Khardori R. Fibrous disease of the breast, thyroiditis, and cheiroarthropathy in type I diabetes mellitus. *Lancet* 1984; 1: 193-195.
3. Ely KA, Tse G, Simpson JF, Clarefeld R, Page DL. Diabetic mastopathy, a clinicopathologic review. *Am J Clin Pathol* 2000; 113: 541-545.
4. Morgan MC, Weaver MG, Crowe JP, Abdul-Karim FW. Diabetic mastopathy; a clinicopathologic study in palpable and nonpalpable breast lesions. *Mod Pathol* 1995; 8: 349-354.
5. Camuto PM, Zetrenne B, Ponn T. Diabetic mastopathy; a report of 5 cases and a review of the literature. *Arch Surg* 2000; 135: 1190-1193.
6. Wong KT, Tse, G MK, Yang WT. Ultrasound and MR imaging of diabetic mastopathy. *Clin Radiol*, 2002; 57: 730-735.
7. Balan P, Turnbull IW. Dynamic contrast enhanced magnetic resonance imaging and magnetic resonance spectroscopy in diabetic mastopathy. *Beast* 2005; 14: 68-70.