

Bronchiolitis obliterans organising pneumonia (BOOP) or cryptogenic organising pneumonia (COP)

V K Bhagwandas

MB BCh, FCRad (D) (SA)

*X-ray Department
Lenmed Clinic
Lenasia
Johannesburg*

R Morar

MB ChB, MMed, FCP (SA), FCCP

*Department of Pulmonology
University of the Witwatersrand
Johannesburg Hospital*

H D Bhula

BSc (Micro), MB BS (Bombay), FCP (SA)

*Lenmed Clinic
Lenasia
Johannesburg*

Introduction

Bronchiolitis obliterans organising pneumonia (BOOP) is a distinct entity with various clinical, radiographic and prognostic features. Pathologically it is characterised by the presence of granulation tissue polyps within the lumina of bronchioles and alveolar ducts with patchy areas of organising pneumonia. Chronic inflammation is noted in the walls of the surrounding alveoli with preserved lung architecture. The preferred term is cryptogenic organising pneumonia (COP) when no aetiology

is found.¹⁻³ We report on a patient recently seen with this condition.

Case report

A 36-year-old woman presented with a history of persistent non-productive cough for 4 weeks. She complained of pleuritic chest pain, night sweats and progressive shortness of breath with decreased effort tolerance, and she remained symptomatic despite numerous antibiotics. There were no contributing factors in the history to elucidate the aetiology of her symptoms. There was no history of previous allergies, drug use, recent upper respiratory tract infection, significant dust exposure, radiation therapy, transplantation or autoimmune disease.

Systematic examination revealed a young female in respiratory distress, with decreased breath sounds and fine inspiratory crackles at both bases. The cardiovascular system and the rest of the examination were normal.

The blood results revealed mild microcytic hypochromic anaemia. The C-reactive protein and erythrocyte sedimentation rate (ESR) were within normal limits. The urea and electrolytes were normal. Liver func-

tion tests demonstrated a mildly elevated alanine transaminase (66 IU/l), aspartate transaminase (79 IU/l) and lactate dehydrogenase (284 IU/l).

The rheumatoid factor and anti-nuclear factor were negative. Serological tests for Legionnaire's disease, mycoplasma and chlamydia were negative. Sputum examination revealed no organisms on gram-stain and culture. Thoracentesis demonstrated a transudate.

The lung function test showed a moderate restrictive pattern.

The chest X-ray demonstrated bilateral basal infiltrates with blunting of both costophrenic angles suggesting pleural effusions (Fig. 1).

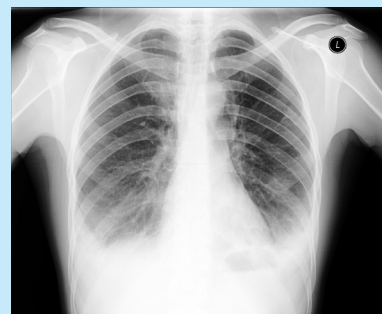


Fig. 1. Bibasal infiltrate with blunting of the costophrenic angles suggesting effusions.

Despite intravenous antibiotics there was no clinical response. High-resolution computerised tomography (HRCT) scan of the chest was then performed which demonstrated patchy bilateral air space consolidation involving predominately the lower lobes. This consolidation appeared to be subpleural and peribronchovascular in distribution. Small bilateral pleural effusions were also confirmed (Fig. 2). There was evidence of patchy ground-glass opacification in the lower lobes. The diagnosis of atypical pneumonia and BOOP was considered.

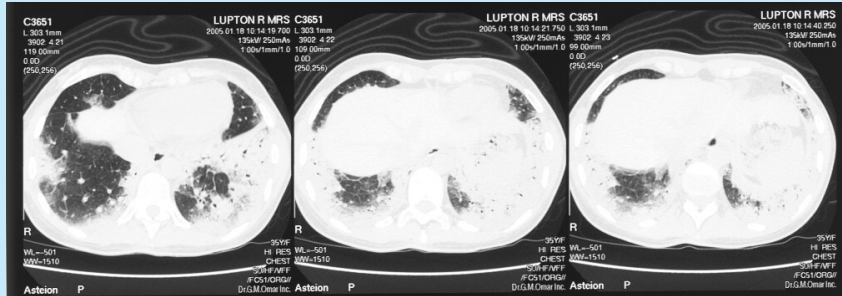

Fig. 2. Patchy bibasal consolidation with subpleural and peribronchovascular distribution.

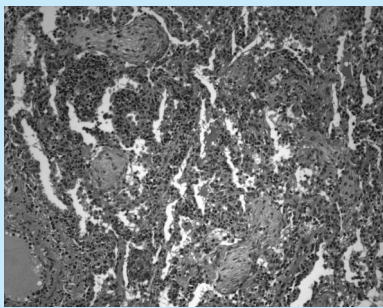
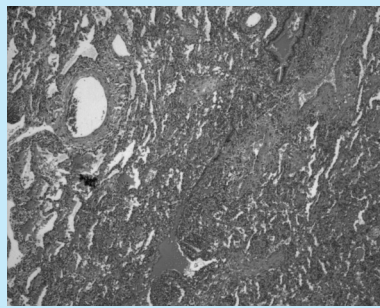


Fig. 3. Interstitial thickening with lymphocytes and plasma cells with granulation tissue type exudates and fibroblast proliferation filling the alveolar spaces.



Idiopathic BOOP

The clinical presentation of idiopathic BOOP, which is the most common type encountered, and the type present in our patient, is one of flu-like illness with fever, mild cough and dyspnoea. Haemoptysis is uncommon. Bilateral basal crackles are noted. Pulmonary function tests demonstrate a restrictive pattern and abnormal diffusing capacity. The ESR is usually raised.¹⁻³

Chest X-ray findings may include unilateral or bilateral patchy alveolar airspace consolidation which is subpleural and peribronchial in location, usually in the lower regions of each lung. The consolidation may be multifocal and non-segmental or unilateral and focal. Nodules 3 - 5 mm in size and other linear opacities may also be seen. Pleural thickening and/or effusions may also be noted.^{1,3}

HRCT scans may show bilateral areas of consolidation and ground-glass opacities are seen mainly in a peripheral location.⁴ Two types of linear opacities may be noted. The first extends in a radial manner along the line of the bronchi toward the pleura, and the second occurs in the subpleural location with no relation to bronchi. Both types usually occur in the lower lobes, frequently associated with multifocal areas of consolidation.⁵ Centrilobular nodules measuring 3 - 5 mm in diameter may be observed. Bronchial wall thickening and cylindrical bronchial dilation may also be noted. Small ill-defined nodular opacities of 1 - 10 mm in diameter may also be seen. Pleural effusions may be present.^{4,5} Cavitating lung masses are rare.⁶ The differential diagnosis includes eosinophilic pneumonia, pulmonary haemorrhage, multi-

An open lung biopsy of the lingula and left lower lobe segments revealed interstitial thickening with lymphocytes and plasma cells, with granulation tissue-type exudates and fibroblast proliferation filling the alveolar spaces (Fig. 3). There was no evidence of tuberculosis, sarcoidosis or malignancy. Multiple sections examined revealed features in keeping with BOOP.

Following confirmation of the diagnosis of idiopathic BOOP, treatment with corticosteroids was commenced at a dose of 0.5 mg/kg. A follow-up chest X-ray obtained 3 weeks post treatment (Fig. 4) showed significant resolution of the bilateral basal infiltrates.

Discussion

BOOP or COP is an inflammatory lung disease and thus is related to the inflammatory pathway rather than the fibrosing pathway that occurs

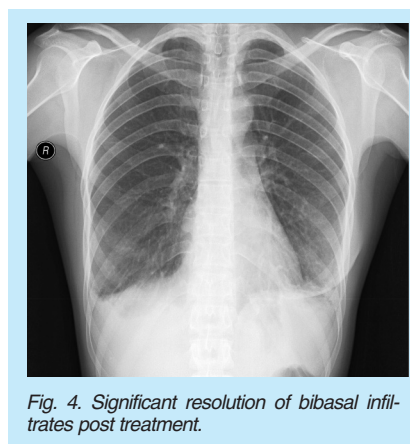


Fig. 4. Significant resolution of bibasal infiltrates post treatment.

with usual interstitial pneumonitis / idiopathic pulmonary fibrosis (UIP/IPF).² BOOP may be classified as follows¹⁻³: (i) idiopathic; (ii) rapidly progressive; (iii) focal nodular; (iv) multiple nodular; (v) post infection; (vi) drug related; (vii) autoimmune disease; (viii) bone marrow transplantation; (ix) lung transplantation; (x) renal transplantation (xi) radiotherapy; (xii) environment-related; (xiii) miscellaneous.

focal infection and diffuse alveolar damage.⁴⁻⁸

Magnetic resonance imaging (MRI) currently has no significant diagnostic role in BOOP, but may have a role to play in the follow-up of patients with BOOP. It may be used to assess the response to treatment and disease activity. Broncho-alveolar carcinoma may mimic BOOP. The white lung sign is an uncommon finding in pulmonary consolidation evaluated with heavily T2-weighted sequences. This sign is usually negative in patients with BOOP but positive in patients with broncho-alveolar carcinoma.⁹ Therefore MRI has a potential role to play in the exclusion of other conditions.

Ultrasound may assist in the characterisation of pleural effusions and for the guidance of pleurocentesis.

The gold standard for confirming the diagnosis is a lung biopsy either by video-assisted thoracoscopic surgery (VATS) or open lung biopsy. Histologically there is evidence of intraluminal organising and polypoid granulation tissue within small bronchioles, alveolar ducts and alveoli. There are also foamy macrophages, inflamed alveolar walls and evenly

spaced rounded balls of myxomatous connective tissue present.¹⁻³

The diagnosis of BOOP/COP is definite in a patient with a typical pathologic presentation on a lung biopsy of sufficient size. However, transbronchial lung biopsy (smaller samples) in a patient with typical clinico-radiological presentation may suggest the diagnosis of BOOP.

Conditions that mimic BOOP include pulmonary lymphoma, chronic eosinophilic pneumonia, broncho-alveolar carcinoma and pulmonary embolism.

It is important that the classified aetiological factors related to BOOP be excluded from the history, examination and investigations, especially infection, drug or radiation-induced pulmonary reaction, autoimmune diseases and systemic inflammatory disease. When no aetiology is found, as in our patient, the organising pneumonia may be called cryptogenic. This condition is a form of idiopathic interstitial pneumonitis.

Finally, treatment for this condition is usually prolonged corticosteroid administration for approximately 6 - 12 months in tapering doses depending on clinical response.

The prognosis is usually good, except in a rapidly progressive form of this condition.^{1,3}

References

1. Cordier JF. Cryptogenic organizing pneumonia. *Clin Chest Med* 2004; **25**: 727-738, vi-vii.
2. American Thoracic Society; European Respiratory Society. American Thoracic Society/European Respiratory Society International Multidisciplinary Consensus Classification of the Idiopathic Interstitial Pneumonias. This joint statement of the American Thoracic Society (ATS), and the European Respiratory Society (ERS) was adopted by the ATS board of directors, June 2001 and by the ERS Executive Committee, June 2001. *Am J Respir Crit Care Med* 2002; **165**: 277-304.
3. Epler GR. Bronchiolitis obliterans organising pneumonia. *Arch Intern Med* 2001; **161**: 158-164.
4. Webb WR, Muller NL, Naidich DP. *High-Resolution CT of the Lung*. 3rd ed. Philadelphia: Lippincott-Raven, 2001: 373-378, 529-537.
5. Murphy JM, Schnyder P, Verschakelen J, Leuenberger P, Flower CD. Linear opacities on HRCT in bronchiolitis obliterans organising pneumonia. *Eur Radiol* 1999; **9**: 1813-1817.
6. Akira M, Yamamoto S, Sakatari M. Bronchiolitis obliterans organising pneumonia manifesting as multiple large nodules or masses. *Am J Roentgenol* 1998; **170**: 291-295.
7. Muller N, Staples C, Miller R. Bronchiolitis obliterans organising pneumonia: CT features in 14 patients. *Am J Roentgenol* 1990; **154**: 983-987.
8. Nishimura K, Itoh H. High-resolution computed tomographic features of bronchiolitis obliterans organising pneumonia. *Chest* 1992; **102**: 26S-31S.
9. Murphy J, Schnyder P, Herold C, Flower C. Bronchiolitis obliterans organising pneumonia simulating bronchial carcinoma. *Eur Radiol* 1998; **8**: 1165-1169.