

## CALCIFICATION IN GASTRIC MALIGNANCY

A. BEREZOWSKI, M.B., CH.B., D.M.R.D., *Johannesburg*

The occurrence of calcification in malignant disease of the stomach is rare. Following is a case where calcification within the gastric outline was observed, and on this and other radiological evidence, a diagnosis of a mucinous adenocarcinoma of the stomach was suggested.

## CASE HISTORY

The patient was a 67-year-old male. His complaint was one of flatulence and occasional regurgitation of acid material. His appetite had remained good, but he had lost approximately 12 lb. in weight. There was no abdominal pain or vomiting. He had become constipated, but had not noticed blood in his stools. The symptoms began approximately 4 months before the time of the examination.

On physical examination a hard mass, measuring approximately 4 in. in diameter, was present in the left hypochondrium. It moved on respiration and disappeared beneath the left costal margin. Hepatic, splenic or glandular enlargement was not in evidence.

## Radiology

The control film of the abdomen showed extensive punctate and linear calcification in the left hypochondrium with evidence of a soft-tissue mass encroaching on the gas-filled fundus of the stomach.

On barium-meal examination there was evidence of an irregular, almost hour-glass, deformity of the body of the stomach conforming to the clinically palpable mass in the abdomen (Figs. 1 and 2). A normal mucosal pattern was only present in the fundus of the stomach and peristalsis was absent in the affected region. Supine and lateral studies of the abdomen showed the calcification to be intimately related to the deformity of the body of the stomach with some extension antero-superiorly towards the fundus.

## Operative Findings

'An enormous carcinoma was found involving the whole of the stomach, penetrating through to all coats. All glands draining the stomach were involved, and there were nodules present in the omentum. A total gastrectomy, including removal of the omentum, was performed and a retrocolic oesophago-jejunostomy was established' (Mr. J. Wolfowitz).

## Pathology

'The specimen of stomach and attached omentum constituted one of the most remarkable specimens which we have en-

countered. It consisted of a large stomach whose serosal surface was almost completely obscured by lobulated papillary masses of obvious carcinoma. The surface was grey-white and glistening. On opening the viscus, the wall was found to be diffusely thickened and infiltrated by tumour, and almost the entire mucosal surface consisted of neoplastic ulceration. Very little of the serosal surface remained which was not covered by papillary masses of the tumour. At several points in the omentum, up to about 4 in. from the greater curvature, nodules of tumour were also found. Sections were prepared from appropriate regions.

'Microscopic examination revealed the typical histological appearance of a mucoid adenocarcinoma of the stomach which had penetrated from the mucosal surface through the serosa. Islands of cells were present in pools of mucous. A majority of the cells were of the signet-ring type, thus compelling the classification of the lesion to grade IV of Broder's classification. Examination of the nodules in the omentum revealed secondary deposits of tumour with characters as described above' (Dr. J. Gluckman). A radiograph of the specimen is shown in Fig. 3.

## DISCUSSION

Batlan<sup>1</sup> reported a case of calcification within the stomach wall in gastric malignancy and reviewed the literature. He found no report of a previous case in the American literature, and only 7 (5 of which had been proved) in foreign literature. In reviewing the case histories, he noted that all the neoplasms were characterized by mucinous degeneration and that the calcification only occurred in such areas. He postulated that the presence of mucin may be the determining factor in the pathogenesis of calcium deposition.

Kendig *et al.*<sup>2</sup> reported a case of calcification in gastric carcinoma. The pathological diagnosis was a mucoid carcinoma simplex of the stomach. A recurrence of the neoplasm occurred in the patient, and calcification was noted in the recurrent tumour. This was, according to Kendig, the second proven case in America and probably the ninth in the world literature.

Petersen<sup>3</sup> similarly reported a case of calcification in



Fig. 1. See text.

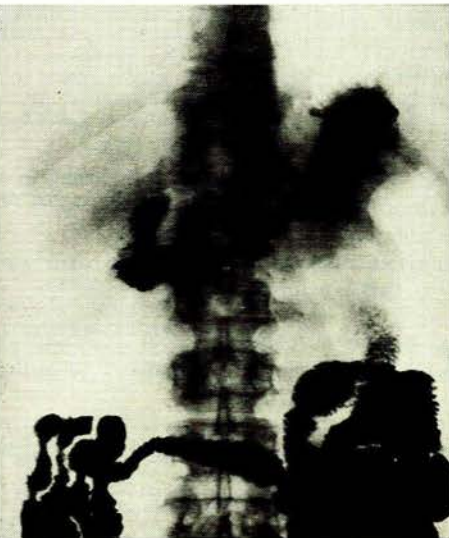


Fig. 2. See text.

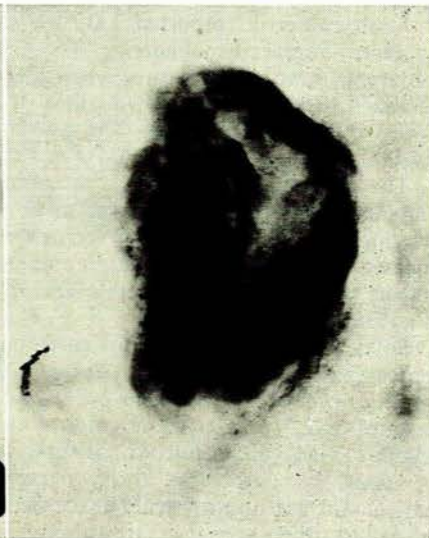

Fig. 3. See text.