

# Oropharyngeal fetus-in fetu in Ilero Nigeria: A case report

ADEBIYI AO, SHORUNMU TO<sup>1</sup>, OWOEYE T<sup>2</sup>, AMORAN OE, OJELEKE AA<sup>3</sup>

Department of Community Medicine, University College Hospital, Ibadan, <sup>1</sup>Department of Obstetrics and Gynaecology, Olabisi Onabanjo University Teaching Hospital, Sagamu, <sup>2</sup>Department of Anatomy, College of Medicine, University of Ibadan, <sup>3</sup>Department of Primary Health Care, Kajola Local Government, Okeho, Nigeria

## ABSTRACT

Fetus-in-fetu is a rare congenital condition in which a malformed parasitic twin is found within the body of its partner. Although a few had been documented worldwide, none has been reported in Nigeria. In this report, we document the history of a concoction of drugs of an indeterminate nature taken in pregnancy, the wrong diagnosis by the rural based sonographer and the presence of polyhydramnios. Our finding of a previously misdiagnosed oropharyngeal fetus-in fetu with dichorionic and cardiac features calls for a revision of the current definition of fetus-in fetu. It also raises an important hypothesis of the likely associations between drugs, infections, pregnancy induced hypertension and fetus-in-fetu.

**Key words:** Fetal abnormality; oropharyngeal fetus-in fetu; pregnancy.

## Introduction

Fetus-in-fetu is a rare congenital condition in which a malformed parasitic twin is found within the body of its partner.<sup>[1]</sup> It is said to represent a malformed monozygotic, monochorionic-diamniotic parasitic twin included in a host (or autosite) twin of which the presence of a rudimentary spinal architecture is diagnostic criterion.<sup>[2]</sup> According to Taori and co-workers, approximately 87 reports have been documented,<sup>[3]</sup> but a detailed literature search showed none has been documented in Nigeria. In addition, literature has only documented one oropharyngeal fetus-in-fetu.<sup>[4]</sup>

In this report, we describe an oropharyngeal fetus-in fetu with dichorionic and cardiac features that is unique and perhaps is the first reported case of fetus-in-fetu in Nigeria.

## Case Report


A 30-year-old unbooked gravida 2 para 1 (1 alive) lady presented at the rural comprehensive health center in Ilero

(about 150 km from a specialist center). The chief complaint was persistent headache. There was associated hotness of the body, sore throat that has cleared, swelling of the legs, severe insomnia, and difficulty with breathing.

Her menarche was at 20 years and her last confinement was in year 2003. In her last pregnancy, she had vomiting and severe headache, which started at 1 month of gestation and got worse gradually. She attributed this to the fact that she was poisoned. She later claimed to have received treatment from a syncretic church after which she got well. Labor was however uneventful.

Her last menstrual period was 36 weeks from presentation. Antenatal care was started at 1 month in an unidentifiable unlicensed health care facility in Lagos State. Drug history

**Address for correspondence:** Dr. Adebisi AO, Department of Community Medicine, University College Hospital, Ibadan, Nigeria.  
E-mail: adebiyi20012002@yahoo.com

Access this article online	
<b>Website:</b> www.tjgonline.com	<b>Quick Response Code</b> 
<b>DOI:</b> 10.4103/TJOG.TJOG_20_17	

This is an open access article distributed under the terms of the Creative Commons Attribution-NonCommercial-ShareAlike 3.0 License, which allows others to remix, tweak, and build upon the work non-commercially, as long as the author is credited and the new creations are licensed under the identical terms.

**For reprints contact:** reprints@medknow.com

**How to cite this article:** Adebisi AO, Shorunmu TO, Owuoye T, Amoran OE, Ojeleke AA. Oropharyngeal fetus-in fetu in Ilero Nigeria: A case report. Trop J Obstet Gynaecol 2017;34:65-8.

revealed various drugs taken from different untrained and informal health practitioners. This included the following:

1. Daraprim, which she claimed, gives her abdominal distension and discomfort
2. Ferrous gluconate, vitamin b complex and vitamin c
3. Unidentified injections during the 6<sup>th</sup> month for 8 days
4. Unidentified injections between the 7<sup>th</sup> month and 8<sup>th</sup> month for 2 days and 6 days respectively.

She had no known history of hypertension, diabetes, or epilepsy but the history of the last pregnancy suggests a mild case of preeclampsia. There was a positive history of twinning in both the woman and husbands' family. The husband age was 32 years.

Physical examination revealed a young woman in obvious distress with bilateral pitting edema up to the proximal two-third of the leg. The abdomen was grossly distended and tense. The fetus was presenting cephalic with a doughy mass in the mid transverse position. The fetal heart sound was distant and diffuse. The cervix was 3 cm dilated and firm.

The blood pressure was 160/110 mmHG; heart rate was 88 beats/minute while respiratory rate was 32 cycles/minute.

An ultrasound scan done by a rural sonographer a day before presentation reported a single active fetus with a right ovarian cyst.

Urinalysis showed protein of 100 mg and nil glucose while the hematocrit was 36%.

A provisional diagnosis of preeclampsia with polyhydramnios and a co-existing uterine mass in pregnancy was made.

The patient was given methyldopa, diazepam, and phenobarbitone. Thereafter, a decision to do a cesarean section was made after an informed consent was obtained.

At surgery, there was excessive amniotic fluid and a live baby with a mass projecting from within the buccal cavity was delivered.

Gross examination of the delivered baby and mass revealed a well-formed male fetus with a mass that has a beating heart, a rudimentary skeletal framework with attached lower limb buds, a blood mass that is undoubtedly the second placenta and a rudimentary face structure with placodes. All these features are indicated in the picture plates in Figures 1-4. The fetuses died about 5 minutes after birth.

The patient was subsequently managed as a case of pregnancy induced hypertension and discharged home

on the 10<sup>th</sup> post-operative day with a blood pressure of 130/80 mmHG.

## Discussion

Preeclampsia happens more frequently in multiple pregnancies and is in fact 3–5 times more common in twins.<sup>[5]</sup> While monozygotic twinning may be induced experimentally following the exposure to a variety of agents, the mechanisms of spontaneous twinning in humans remains unknown, but it has been suggested that all agents that are capable of acting as twinning stimulus are teratogenic, and probably act by interfering with the spindle apparatus.<sup>[6]</sup> In addition, Spencer has linked the association of conjoined twins and their parasites with fetuses-in-fetu, acardiacs, and teratomas.<sup>[7]</sup> However, while the birth rate of twins in the Yoruba's of Western Nigeria is 45/1000 live births with approximately 90% of these being dizygotic,<sup>[8]</sup> the incidence of conjoined twins in Nigeria remains undocumented. We are also not aware of any documented case of fetus-in-fetu in Nigeria. Spencer while reviewing the common patterns of these fetuses-in-fetu listed family history of twinning, predominance of females, and the frequent presence of a twin or triplet accompanying the malformation.<sup>[7]</sup> Although in this case, a positive family history of twinning was elicited, the presence of a female fetus could not be demonstrated. Spencer in addition posited that rarely if ever is either a functional heart or a competent brain found in any of the abnormal fetuses and this was also supported by the statement that the commonest visceral organ within the fetus was the gut and if a heart is present at all it would be rudimentary.<sup>[3,7,9]</sup> But we found a beating heart in the abnormal fetus which contrasts the hypothesis of Spencer that a primary cardiac malformation with secondary disruption in the development of the brain is the likely etiology.<sup>[7]</sup>

It has been suggested that the presence of a rudimentary spinal architecture be used to differentiate a fetus-in-fetu from a teratoma since teratomas are not supposed to develop beyond the primitive streak stage (12–15 days).<sup>[2]</sup> Although a clearly defined spinal architecture is not obvious in this case, there is a rudimentary structure with an obvious segmentation with body coelom and cranio-caudal differentiation. This agrees with the position that many authors regard a rudimentary body architecture (metameric segmentation, cranio-caudal and lateral differentiation, body coelom, "gestational sac") or the presence of an associated fetus-in-fetu as equivalent criteria and this was based on the fact that although teratomas can achieve the inductive effect of adjacent tissues on one another, they do not present the criteria previously stated.<sup>[2]</sup> Recent reports have also stated that fetus-in-fetu is a rare variant of teratoma itself and they

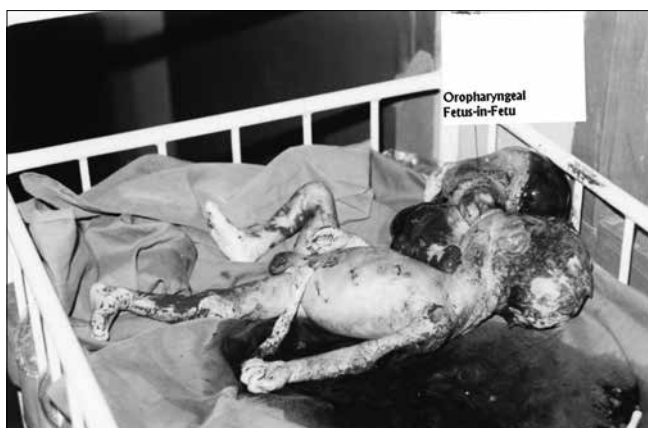

Figure 1: Oropharyngeal fetus-in fetu

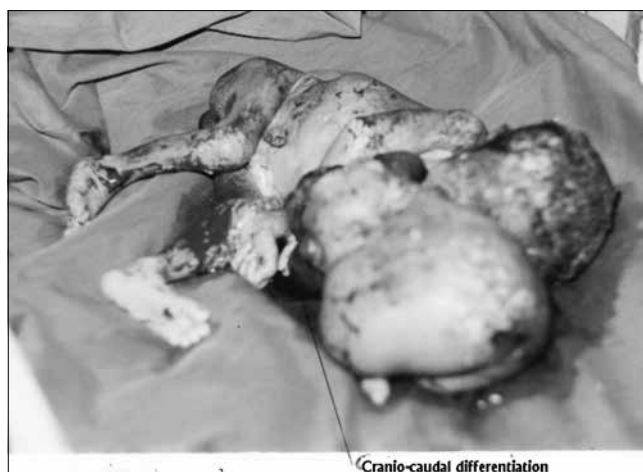

Figure 2: Fetus-in fetu with cranio-caudal differentiation

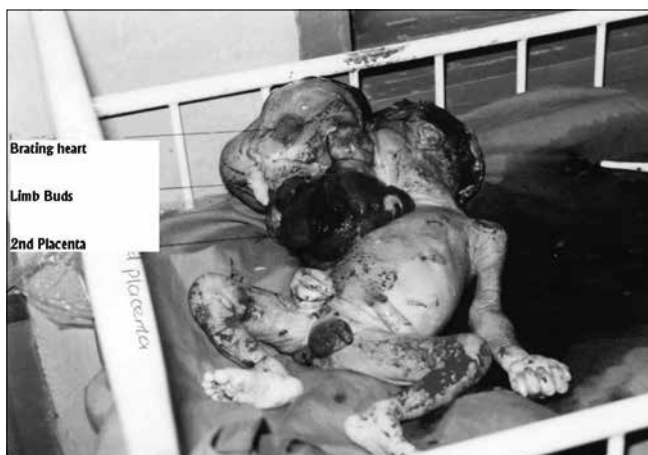

Figure 3: Fetus-in Fetu with differentiated beating heart, limbs and placenta mass

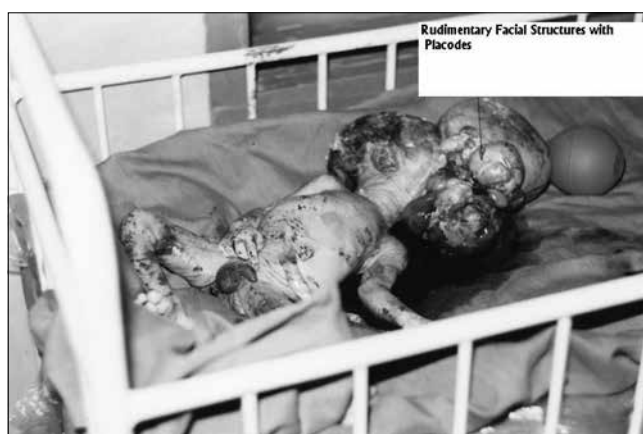

Figure 4: Fetus-in fetu with placodes and rudimentary facial structures

are related entities, because they possibly have the same developmental malformation.<sup>[9]</sup> In fact, in a large review of intracranial tumors, it was found that there are some transitions between certain teratomas and fetus-in-fetu.<sup>[10]</sup>

The finding of polyhydramnios is not unusual as central nervous system, gastrointestinal, and musculoskeletal disorders are the main fetal anomalies associated with it.<sup>[11,12]</sup> While twinning is associated with pregnancy induced hypertension, which is about 3–5 times, more than in the normal pregnancy,<sup>[13]</sup> the extent to which it contributes to the etiology of fetus-in-fetu or being a complication of it needs further studies. Although some drugs have been known to be teratogenic, the concoction of drugs of an indeterminate nature taken by this woman makes it difficult to suggest any likely pathway. This brings to light once more the dangers posed to the health of people by the untrained informal health care providers in Nigeria. It is important to note that obstetric ultrasound has made prenatal diagnosis of this condition possible in other settings.<sup>[3,4]</sup> So, the sonograph reporting of the oropharyngeal mass as an ovarian mass is a dilemma

that may be faced especially in rural practices using obsolete scanning machines and should call for a second opinion in cases of funny looking masses. The finding of delayed menarche in this woman is most probably environmental as there are no other overt secondary defects in reproductive maturation. In this environment, it may be due to factors like poor general health, nutrition, and/hygiene. This case also highlights the importance of having at least one center in each rural area with a medical officer of health that can provide emergency obstetric service.

In conclusion, an unbooked pregnant woman with preeclampsia was delivered of an oropharyngeal fetus-in-fetu, which subsequently died 5 minutes later. We do believe this is the first reported fetus-in-fetu in Nigeria and probably the second reported oropharyngeal fetus-in-fetu worldwide.

This case raises some unanswered questions as to the likely associations between drugs, infections, pregnancy induced hypertension, and fetus-in-fetu. It also raises the dilemma of a rural developing nation sonographer in prenatal diagnosis

and the need for scaling up emergency obstetric services. Lastly, it calls for a modification of the current views on fetus-in-fetu because of the cardiac and dichorionic features seen in this case.

#### Financial support and sponsorship

Nil.

#### Conflicts of interest

There are no conflicts of interest.

#### References

1. Mohta A, Shrivastava UK, Sodhi P, Upreti L. Fetus-in-Fetu. *Pediatr Surg Int* 2003;19:499-500.
2. Jeanty P, Goncalves L, Silva S. Available from: [www.thefetus.net](http://www.thefetus.net). [Last accessed on 2004 Dec 16]
3. Taori KB, Khurana SD, Dhohne SP, Rathi V. Fetus-in-fetu – A rare case. *Ind J Radiol Imag* 2003;13:85-7.
4. Kapoor V, Flom L, Fitz CR. Oropharyngeal fetus-in-fetu. *Pediatr Radiol* 2004;34:488-91.
5. Chism DM. *Twins, Triplets and More. The High-Risk Pregnancy Sourcebook* 1997. Illinois, USA: McGraw-Hill; 1997.
6. Kaufman MH. The embryology of conjoined twins. *Childs Nerv Syst* 2004;20:508-25.
7. Spencer R. Parasitic conjoined twins: External, internal (fetuses in fetu and teratomas), and detached (acardiacs). *Clin Anat* 2001;1496:428-44.
8. Zach T, Pramanik A, Ford SP. Multiple births. Available from: [eMedicine.com](http://eMedicine.com). [Last accessed on 2004 Dec 17].
9. Kazez A, Ozercan IH, Erol FS, Faik Ozveren M, Parmaksiz E. Sacrococcygeal heart: A very rare differentiation in teratoma. *Eur J Pediatr Surg* 2002;12:278-80.
10. Wakai S. On the origin of intracranial teratomas. *No To Shinkei* 1989;41:947-53.
11. Ben-Chetrit A, Hochner-Celnikier D, Ron M, Yagel S. Hydraminos in the third trimester of pregnancy: A change in the accompanying fetal anomalies as a result of early ultrasound diagnosis. *Am J Obstet Gynaecol* 1990;162:1344-5.
12. Queenan JT, Gadow EC. Polyhydraminos, chronic versus acute. *Am J Obstet Gynaecol* 1970;108:349-55.
13. Clinical Discussions. Twin pregnancy. Available from: [www.atlanta-mfm.com/clindisc/vol2no4.html](http://www.atlanta-mfm.com/clindisc/vol2no4.html). [Last accessed on 2004 Dec 16]