

Where's the line/tube?

Author:Aadil Ahmed¹**Affiliation:**¹RSSA, Radiologist at Visser, Erasmus, Vawda & Partners, Port Elizabeth, South Africa**Correspondence to:**

Aadil Ahmed

Email:

aadil.a@bayradiology.co.za

Postal address:PO Box 10517, Linton Grange
6015, Port Elizabeth,
South Africa**Dates:**

Received: 06 June 2015

Accepted: 11 Aug. 2015

Published: 27 Nov. 2015

How to cite this article:Ahmed A. Where's the line/
tube? S Afr J Rad. 2015;19(2):
Art. #888, 8 pages. [http://
dx.doi.org/10.4102/sajr.
v19i2.888](http://dx.doi.org/10.4102/sajr.v19i2.888)**Copyright:**

© 2015. The Authors.

Licensee: AOSIS

OpenJournals. This work is

licensed under the Creative

Commons Attribution

License.

Read online:Scan this QR
code with your
smart phone or
mobile device
to read online.

Radiologists are confronted with a spectrum of catheters placed in various locations in routine radiology practice and have to be familiar with the different catheters, their uses and acceptable positioning for suggested safe practice. The commonly used vascular and non-vascular catheters are described and discussed in this brief guide.

Introduction

The chest radiograph (CXR) plays an important role in assessing patients in intensive care units (ICU). It is the most common radiological investigation due to its value in diagnosing cardio-respiratory disease. An abdominal radiograph (AXR) commonly accompanies the CXR in evaluating the neonate in ICU. The CXR and AXR are also extremely useful and important for evaluating the position of various lines and tubes.

The American College of Radiology (ACR) recommends a CXR immediately following placement of indwelling tubes, catheters and other devices to check their positions and detect procedure-related complications.¹

Umbilical catheters

Umbilical venous catheter (UVC)

Uses: These are commonly used for vascular access during the neonatal period. The UVC allows for the infusion of hypertonic solutions, total parenteral nutrition and emergency access for fluids, drugs and blood products. It is directed into the umbilical vein.

A developmental foetal remnant – the ductus venosus – connects the umbilical vein to the inferior vena cava (IVC). The portal sinus connects the umbilical vein to the portal vein. This connection allows for anomalous positioning of the UVC within the portal vein. The normal neonatal anatomy is demonstrated in Figure 1.

There is a higher incidence of congenital defects associated with umbilical vein variations. If such a variation is detected, the neonate should be investigated for other congenital abnormalities.²

The objective is to place the UVC above the diaphragm, at the entrance to the right atrium. Despite their common use, UVCs are still frequently malpositioned.

Anomalous positions

Below the diaphragm: umbilical vein, portal vein, hepatic vein.

Above the diaphragm: through a patent foramen ovale or an atrial septal defect (ASD) into the left atrium, pulmonary vein, superior vena cava (SVC), internal jugular vein (Figure 2 and Figure 3).³

Complications

Below the diaphragm: Perforation of intrahepatic vascular wall – the formation of hepatic haematoma, and even abscess formation (Figure 4a and Figure 4b). The UVC positioned within the portal venous system predisposes the patient to thrombus formation.

Above the diaphragm: Perforating the atrial wall and entering the pericardial space may lead to cardiac tamponade.⁴ When the UVC passes through a patent foramen ovale or ASD or through the tricuspid valve into the right ventricle, this can lead to cardiac arrhythmias. Other complications include pulmonary infarction and thrombotic endocarditis.⁵

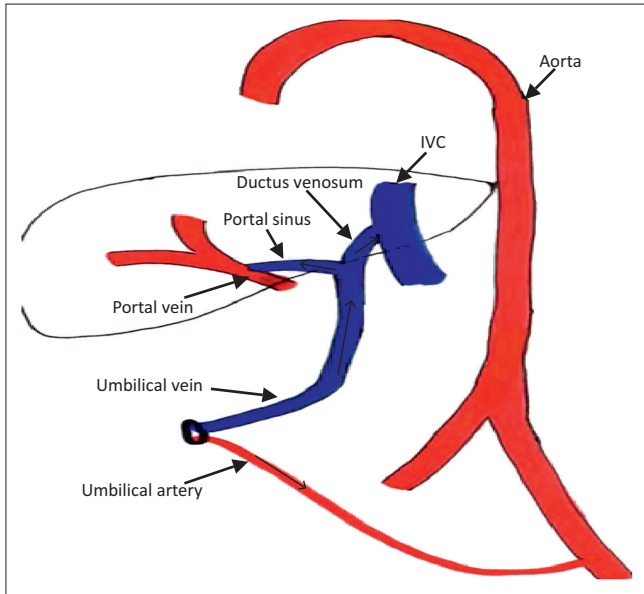


FIGURE 1: Schematic drawing demonstrating the umbilical vessels and their connections to the systemic circulation during the neonatal period.

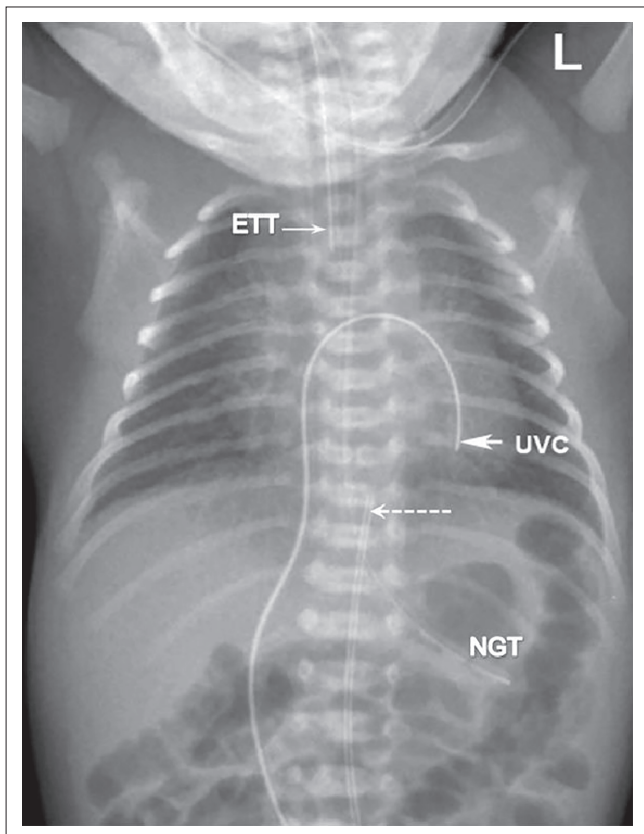


FIGURE 2: Umbilical venous catheter (UVC) (arrow) passing through a patent foramen ovale into the left atrium and ending in the left ventricle. Umbilical arterial catheter (UAC) (dotted arrow) in acceptable high position (T9). Satisfactorily positioned Endotracheal tube (ETT) and Nasogastric tube (NGT).

Umbilical arterial catheter (UAC)

Uses: A UAC is used in blood sampling, arterial blood gas sampling, the administration of intravenous fluids and drugs, checking blood pressure, and in exchange transfusions.

Umbilical arteries are the direct continuation of the internal iliac arteries. The UAC initially courses caudally, and then

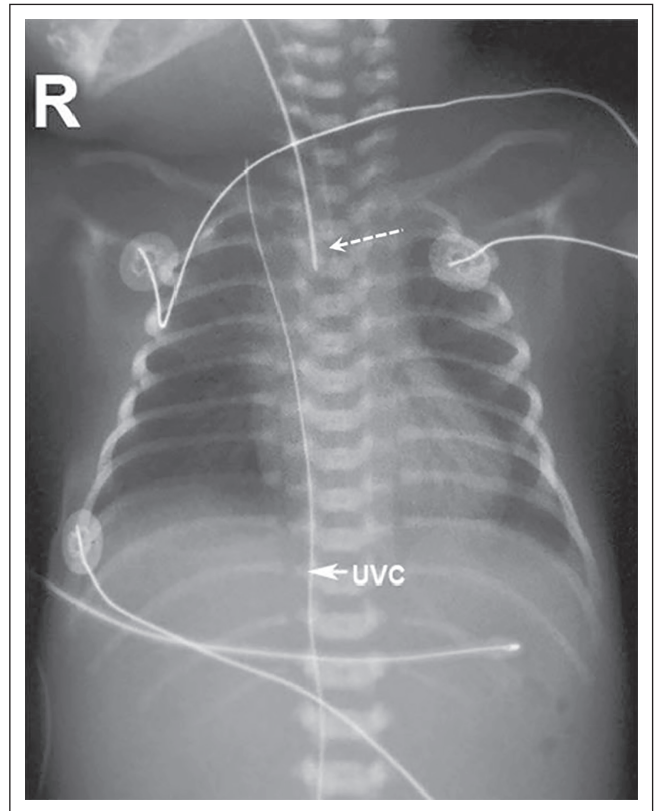


FIGURE 3: Umbilical venous catheter (UVC) advanced beyond the right atrium (RA), passing into the superior vena cava (SVC) and ending in the right internal jugular vein. Good Endotracheal tube (ETT) (dotted arrow) position.

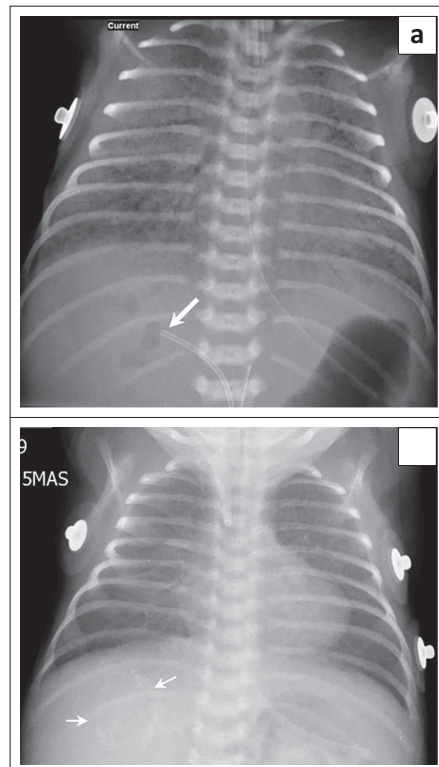


FIGURE 4: (a) Umbilical venous catheter (UVC) (arrow) incorrectly positioned within the right branch of the portal vein. Mottled gas shadows within the liver represent complications related to UVC infusate delivered into liver. This could represent liver parenchymal injury and/or liver abscess formation. It should be differentiated from bubbles of air that can be seen within the portal vein soon after catheterization. (b) Follow-up CXR of patient in image 4a. CXR done one month later shows rim calcified lesion (arrows) within the liver. The infusate within the liver has become encysted and, together with hepatic necrosis, has formed the calcified lesion.

b

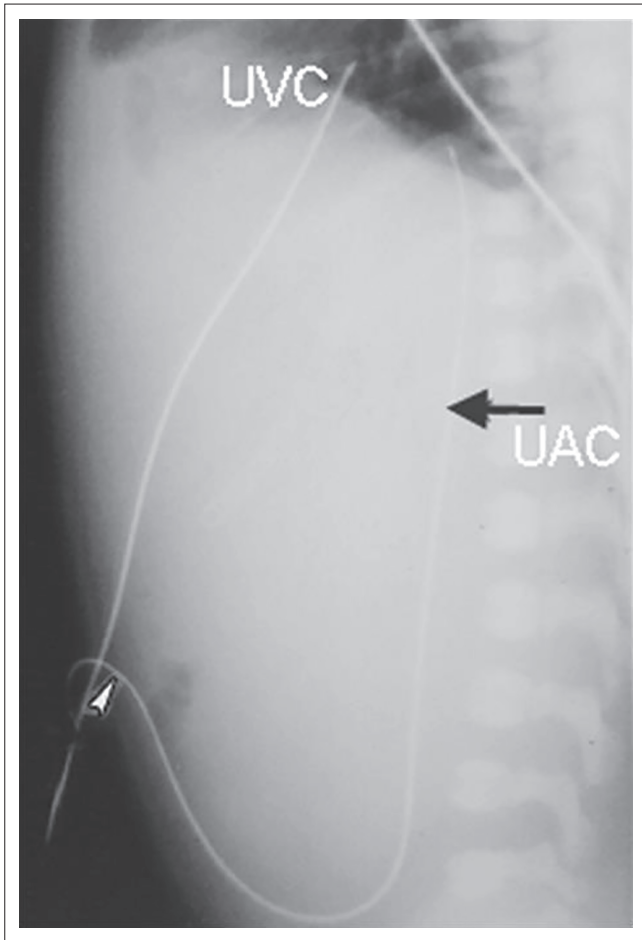


FIGURE 5: Lateral AXR demonstrating the initial caudal course of the umbilical arterial catheter (UAC). The UAC also has a more posterior course within the iliac arteries and the aorta. The umbilical venous catheter (UVC) passes more anteriorly.

passes cranially into the aorta via the internal and common iliac arteries. It has a posterior course compared to the more anterior location of the UVC (Figure 5).

The optimum position of the UAC is either above or below the visceral branches of the aorta.^{3,6} It should not be in a branch of the aorta as it can block the vessel. High lines have their tips positioned between T6–10 and low lines have their tips between L3–5.³

The high position is favoured since it leads to fewer vascular complications.

Anomalous positions: Occasionally, the UAC can pass into the femoral or gluteal arteries. It can also pass into a branch of the aortic arch, for instance the common carotid artery or subclavian artery (Figure 6).

Complications

Complications include infection, thrombosis, air embolism, perforation and bleeding.^{3,6}

Endotracheal tube (ETT)

Uses: The ETT is inserted for ventilatory support and it also prevents aspiration. The ETT should be placed halfway

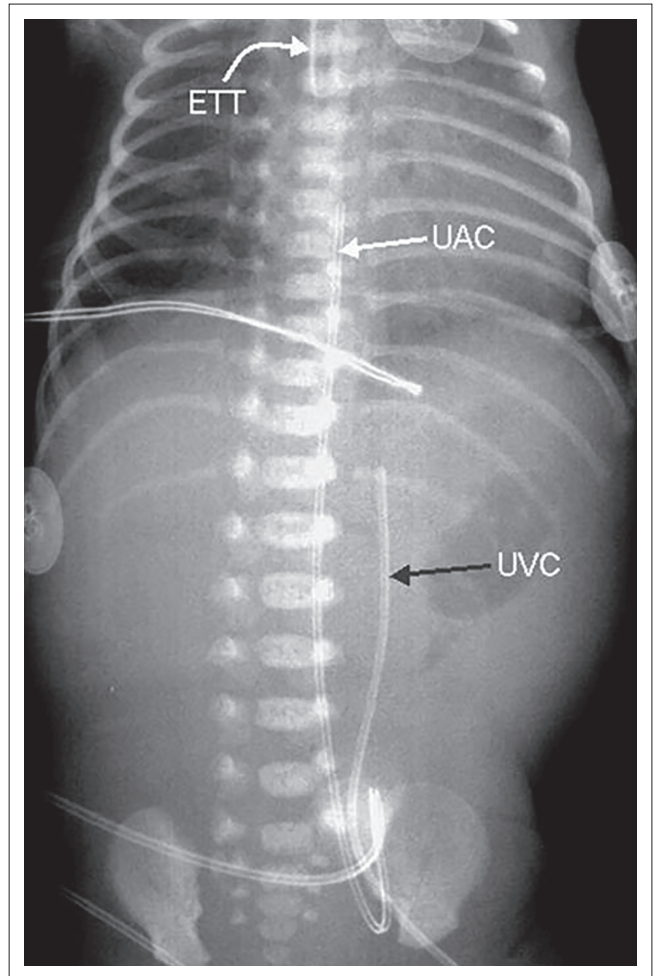


FIGURE 6: The umbilical arterial catheter (UAC) is positioned to the right of the umbilical venous catheter (UVC) in this X-ray. Is there an anomaly? No, this finding is due to poor technique, as the patient is rotated to the left. On a correctly positioned AP view, the UVC should lie to the right of the UAC, in keeping with the normal aorta–IVC relationship.

between the thoracic inlet and the carina or 1.5 vertebral bodies above the carina.⁶

Complications

The most common complication is selective intubation of the bronchus (Figure 8a and Figure 8b). This results in collapse/atelectasis of the contralateral lung. If the patient is on a ventilator, the ipsilateral lung can become hyperinflated, leading to pneumothorax or tension pneumothorax. Another serious complication is inadvertent oesophageal intubation (Figure 9).¹ This complication is mostly diagnosed clinically and can be detected radiographically by an air-filled esophagus, over distended stomach and no ETT in the trachea. There are also other complications related to long-term intubation.

Nasogastric tube (NGT)

Uses: The NGT is inserted for the aspiration of gastric contents, gastric decompression or feeding the patient. The tip should lie within the stomach.

Complications

The NGT can be misplaced in the tracheobronchial tree (Figure 10). Perforation of the oesophagus or stomach

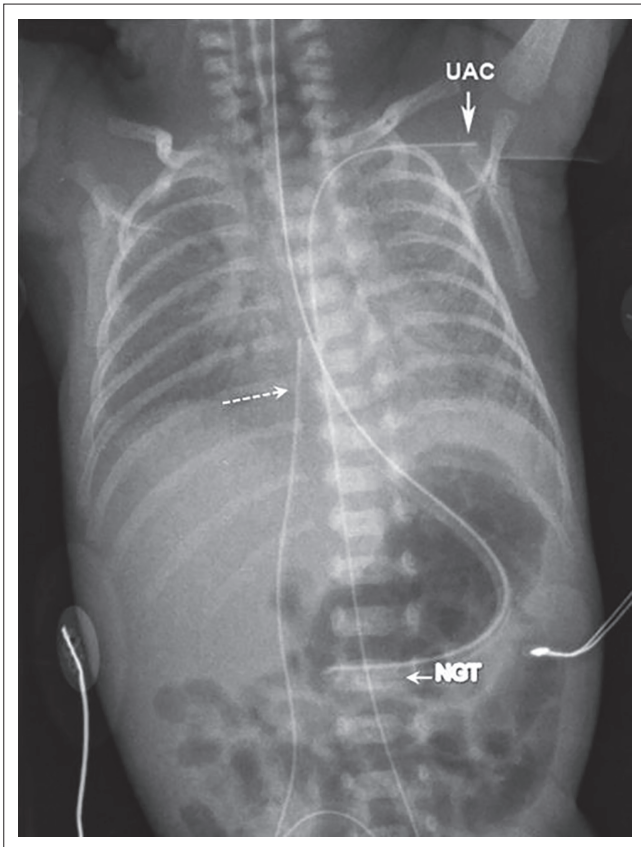


FIGURE 7: The umbilical arterial catheter (UAC) has been advanced too far. Its distal tip is in the left subclavian artery. The umbilical venous catheter (UVC) tip (dotted arrow) is located in the RA. The end of the nasogastric tube (NGT) is in the stomach.

is extremely uncommon, but can occur, particularly in premature infants.⁷ A coiled NGT in a proximal oesophageal pouch is important to recognise in oesophageal atresia.² In neonates with left-sided congenital diaphragmatic hernia, the NGT tip is most commonly positioned at the gastro-oesophageal junction or within the left hemithorax. An NGT deviating to the right is seen in a patient with heterotaxy syndrome and abdominal situs (Figure 11).

Ventriculo-peritoneal shunt (VPS)

Uses: VPS's are used to relieve hydrocephalus. The peritoneum is commonly used because it is an efficient site of absorption.⁸

Complications

Shunt malfunction/complications are common. The leading cause of shunt malfunction is mechanical failure. Other complications include infections and overdrainage.

Causes of mechanical failure: These include obstruction, migration, leakage, disconnection, improper placement and cerebrospinal fluid pseudocysts. An obstructed VP shunt will lead to increasing ventricular size, as diagnosed on a CT/MRI scan. Ultrasonography (US) or CT may be helpful in the diagnosis of abdominal CSF pseudocysts.

Occlusion accounted for about 50% of shunt complications in one paediatric series. It occurs more at the ventricular end than at the peritoneal end.⁸

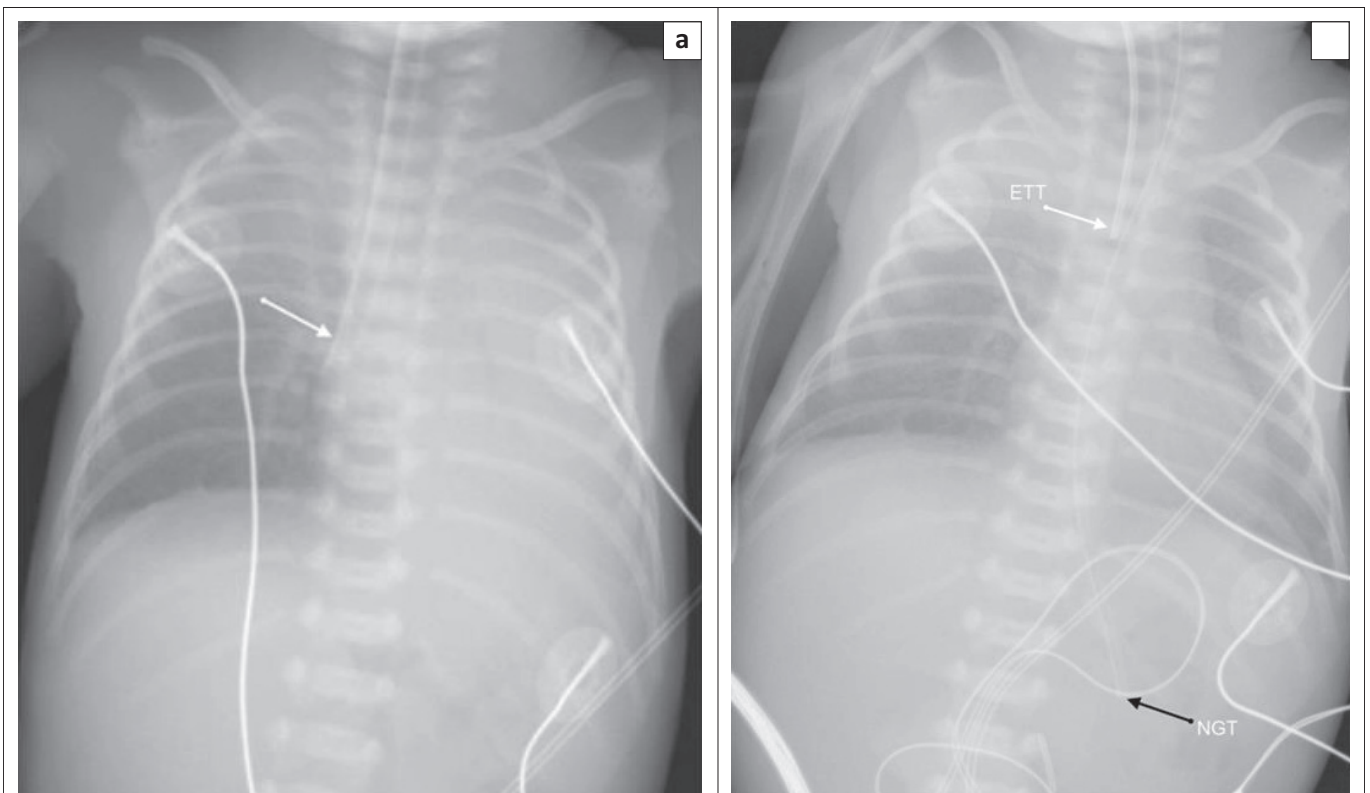


FIGURE 8: (a) The end of the endotracheal tube (ETT) (arrow) is lying within the right main bronchus. There is resultant left-sided atelectasis and mediastinal shift to the left. (b) The endotracheal tube (ETT) in Figure 8a has been withdrawn, and there has been re-expansion of the left lung. The NGT is within the stomach.

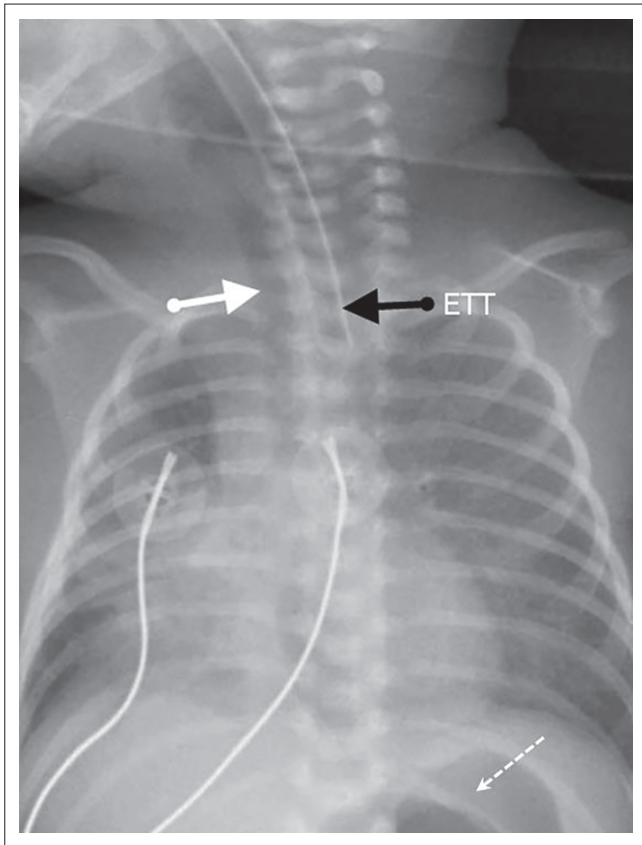


FIGURE 9: The ETT is positioned in the oesophagus. The trachea (white arrow) is visible to the right of the ETT. Secondary to oesophageal intubation there is dilatation of the stomach (dotted arrow) and distal oesophagus.

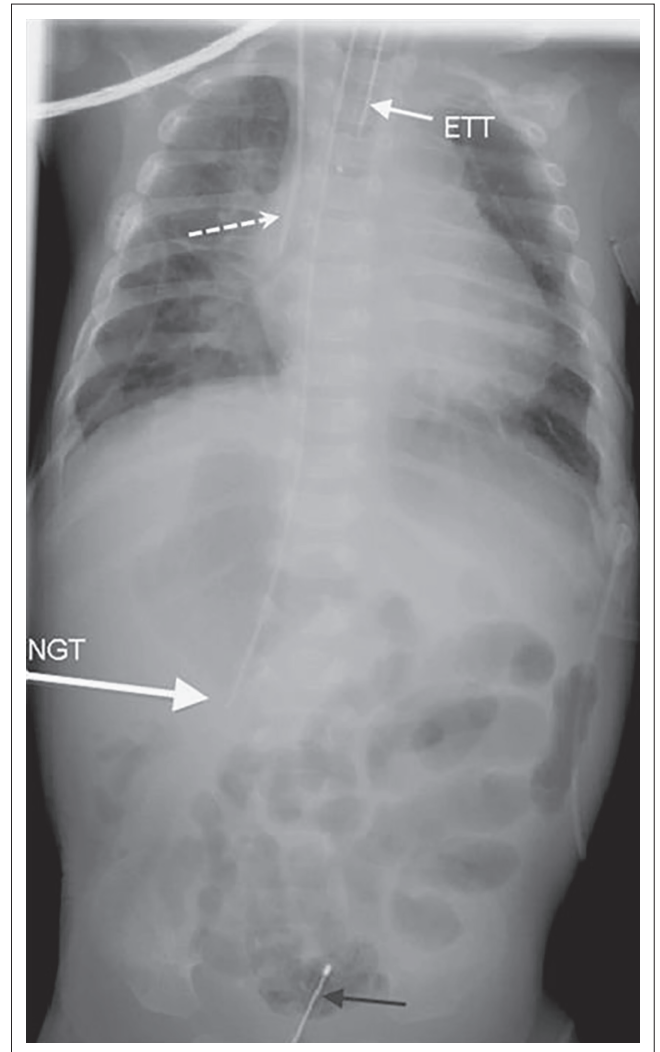


FIGURE 11: The nasogastric tube (NGT) end is within a right-sided stomach in a patient with abdominal situs inversus. There is a right-sided central venous catheter in situ with its end in the superior vena cava (SVC) (dotted arrow). A urinary catheter is in the bladder (black arrow).

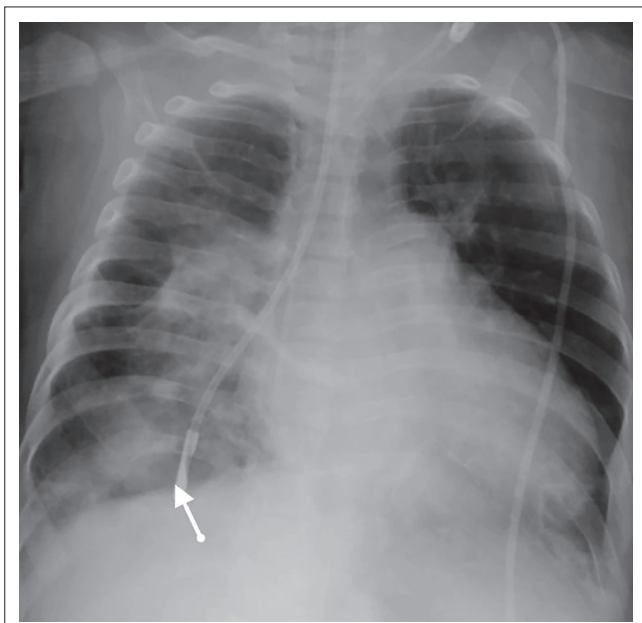


FIGURE 10: The nasogastric tube (NGT) (arrow) has entered the tracheobronchial tree, with the end lying within a terminal bronchiole of the right lower lobe. The surrounding lung changes are secondary to inadvertent administration of feeds into this NGT.

Disconnection/fracture is the second most common cause of mechanical shunt failure. The neck and scalp are common sites. An X-ray shunt series (skull AP and Lateral, Chest AP, Abdomen AP views) can be done to determine the location of the break.

Shunts can be improperly positioned at the level of the ventricles or within the peritoneum (Figure 12a and Figure 12b); similarly, shunt migration can occur at both ends. Within the abdomen, the viscera can also be perforated by the shunt.

Others

Intercostal drains: These are used for drainage of a pneumothorax or effusion. All the holes of the drain should be within the pleural space¹ (Figure 13). The tube should ideally be inserted in the midaxillary line via the 4th–6th intercostal spaces. It should be lying apico-anterior in patients with a pneumothorax.

The *peripherally inserted central catheter* (PICC) is inserted into peripheral limb veins, with the end lying in the distal SVC or at the cavo-atrial junction. Common complications are related to insertion and malpositioning (Figure 14). Correctly positioning it is important for the administration of certain intravenous medications.

Other venous catheters include *dialysis catheters* and *chemotherapy ports*. These can be malpositioned or become occluded by thrombus and fibrin sheaths (chemotherapy ports).

The *transpyloric tube* is similar to the NGT, except that it is longer and its end is sited distal to the pylorus (proximal to ligament of Treitz). It is used for feeding.

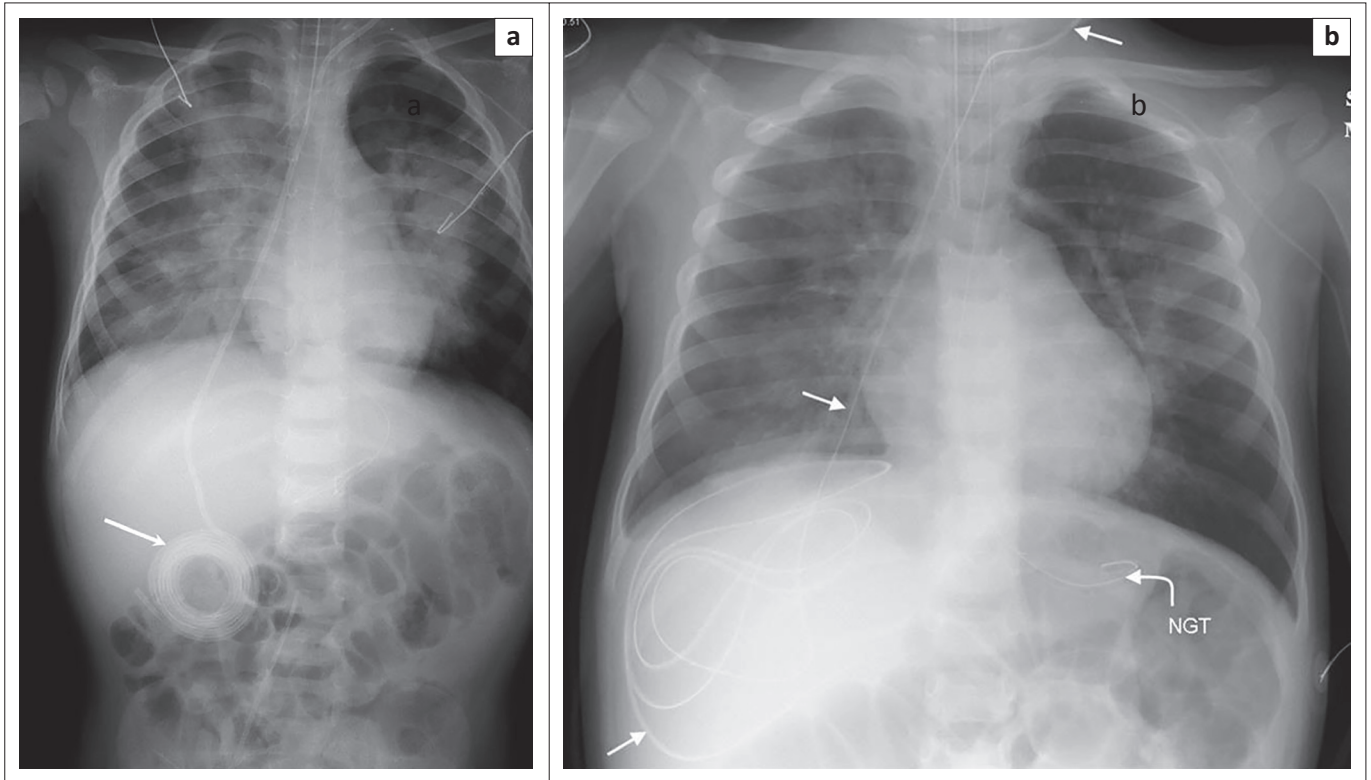


FIGURE 12: (a) The abdominal end of the ventriculo-peritoneal shunt (VPS) (arrow) is lying in an extraperitoneal location (between the anterior abdominal wall and the peritoneal cavity), unable to uncoil. Adequate CSF drainage was not possible and this resulted in raised intracranial pressure and neurogenic pulmonary oedema. (b) The ventriculo-peritoneal shunt (VPS) (arrows) in Figure 12a was repositioned and is now correctly positioned with the peritoneal cavity (freely lying). There has been a marked improvement in the pulmonary oedema changes as the raised intracranial pressure has been relieved.

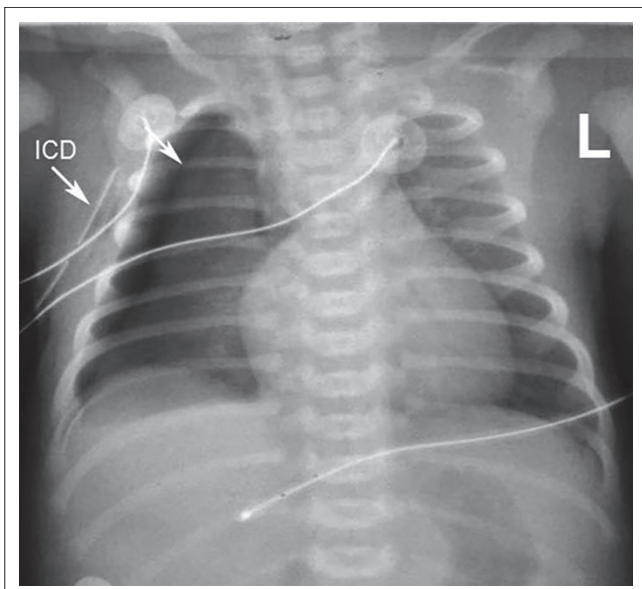


FIGURE 13: Patient with right-sided pneumothorax (arrow). The right ICD is, however, not lying within the pleural space. It is lying instead in the soft tissues outside the thoracic cavity, and thus the pneumothorax remains.

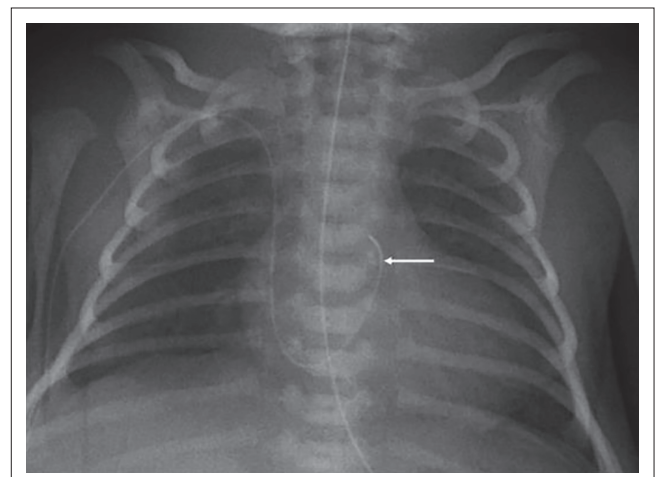


FIGURE 14: The left upper limb peripherally inserted central catheter (PICC) line (arrow) has been advanced too far and its end is within the right ventricle, close to the pulmonary outflow tract.

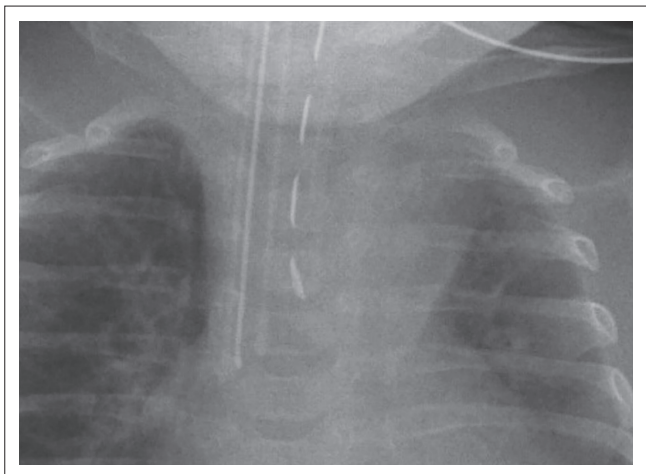


FIGURE 15: Reploggel tube with dashed line lying in the oesophageal pouch. ET tube lying to the right.

Reploggel suction catheters are used in patients with oesophageal atresia to remove saliva from the blind ending oesophageal pouch. The markings of a Reploggel tube form a dashed line, and help to differentiate it from the ETT (Figure 15).

Acknowledgements

Competing interests

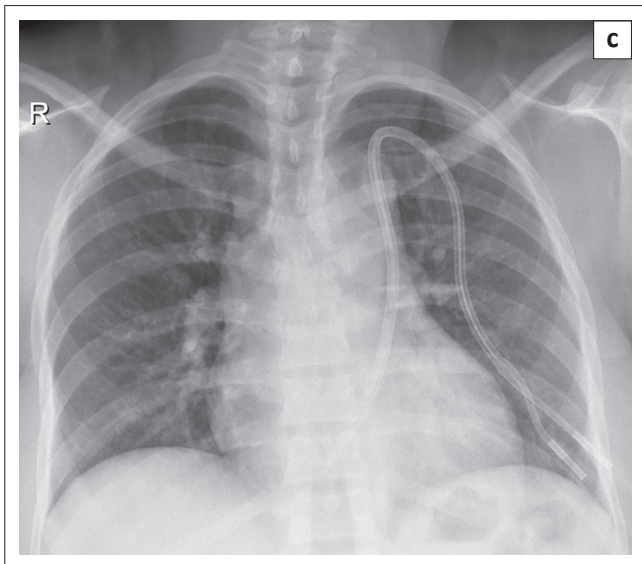
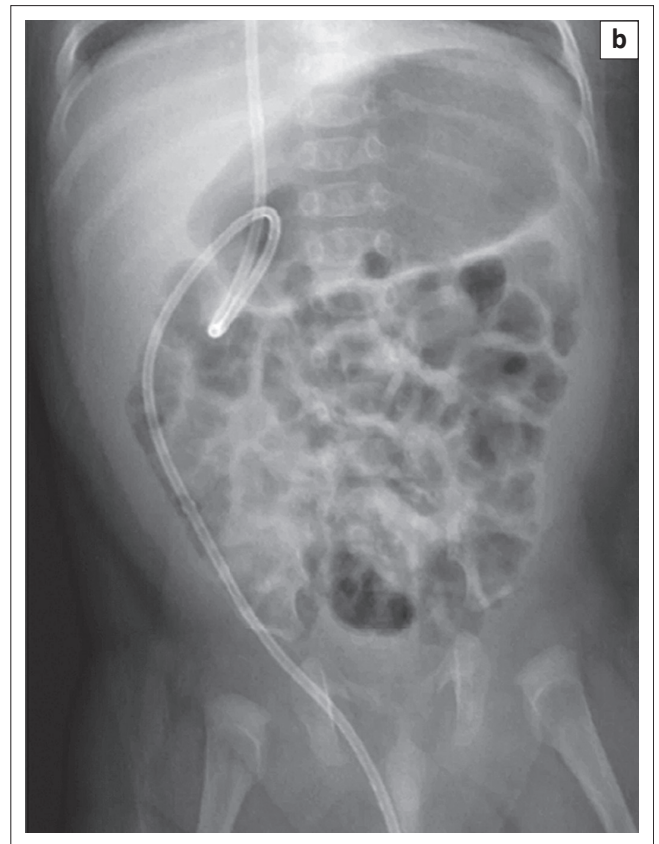
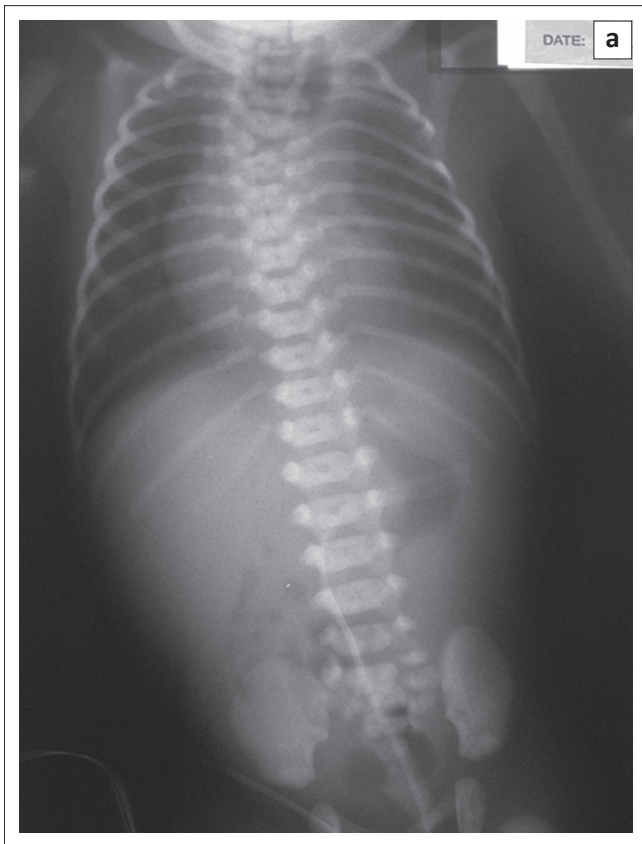
The authors declare that they have no financial or personal relationships which may have inappropriately influenced them in writing this article.

References

1. Jain SN. A pictorial essay: Radiology of lines and tubes in the intensive care unit. *Indian J Radiol Imaging.* 2011;21(3):182–190. PMID: 22013292, <http://dx.doi.org/10.4103/0971-3026.85365>
2. Ahmed A, Pitcher G. Umbilical vein variation – Case of an umbilical vein draining into the portal venous system. *S Afr J Radiol.* 2007;11:4. <http://dx.doi.org/10.4102/sajrv.11i2.49>
3. Narla LD, Hom M, Lofland GK, Moskowitz WB. Evaluation of umbilical catheter and tube placement in premature infants. *Radiographics.* 1991;11:849–863. PMID: 1947320, <http://dx.doi.org/10.1148/radiographics.11.5.1947320>
4. Van Niekerk M, Kalis NN, Van der Merwe PL. Cardiac tamponade following umbilical vein catheterization in a neonate. *S Afr Med J.* 1998;88(Suppl. 2):C87–90. PMID: 9595002.
5. Schlesinger AE, Braverman RM, DiPietro MA. Neonates and umbilical venous catheters: Normal appearance, anomalous positions, complications, and potential aid to diagnosis. *Am J Roentgenol.* 2003;180:1147–1153. PMID: 12646473, <http://dx.doi.org/10.2214/ajr.180.4.1801147>
6. Engelbrecht MR, Blickman JG. The acute pediatric chest. *Appl Radiol.* 2004;33:26.
7. Batra P. Radiology of monitoring devices. In *Syllabus for thoracic imaging 2001, the annual meeting of the Society of Thoracic Radiology.* 2001; p. 202–204.
8. Goeser CD, McLeary MS, Young LW. Diagnostic imaging of ventriculoperitoneal shunt malfunctions and complications. *Radiographics.* 1998;18:635–651. PMID: 9599388, <http://dx.doi.org/10.1148/radiographics.18.3.9599388>

Appendix 1: Self-test Questions

Where is the line/tube?



Answers self-test questions

- The NGT is coiled in the oesophageal pouch in a patient with oesophageal atresia and a tracheo-oesophageal fistula. There is an anomalous connection between the umbilical vein and the superior mesenteric vein (SMV). Surgery confirmed the absence of the ligamentum venosum. The UVC deviates to the left and is lying in the SMV. There are also thoracic and sacral vertebral body abnormalities, 13 ribs on the right and 12 on the left. This child also had cardiac, anorectal and radial abnormalities in keeping with a VACTERL association.
- A VPS is passing into the right scrotal sac via the patent processus vaginalis.
- This dialysis catheter was inserted into the left subclavian vein. The patient has a persistent left SVC which drains into the coronary sinus. The catheter has entered the right atrium via the coronary sinus. This was confirmed with an MRI of the chest.