

Head and neck imaging

Presentation

A 26-year old lady presented with a painful paramedian anterior neck mass. These are her ultrasound and CT scan images.

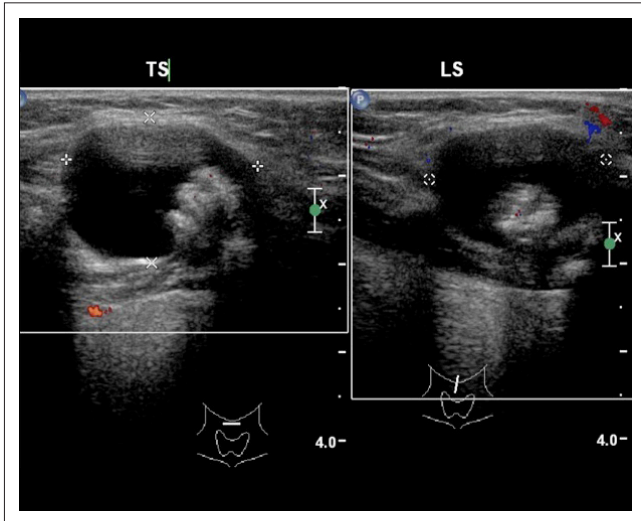


FIGURE 1: Sagittal B-mode sonar image.

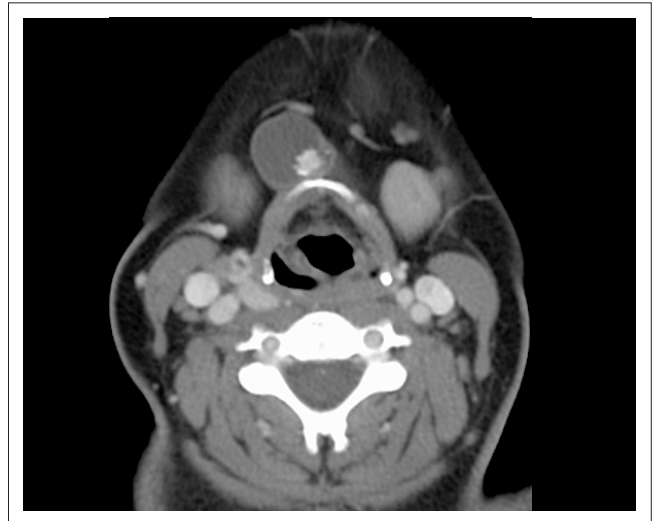

FIGURE 2: Axial CT scan image at level of hyoid bone.

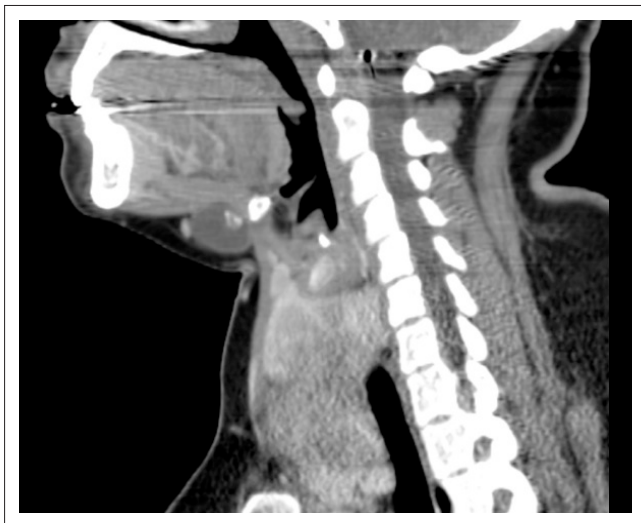


FIGURE 3: Sagittal paramidline CT scan image.

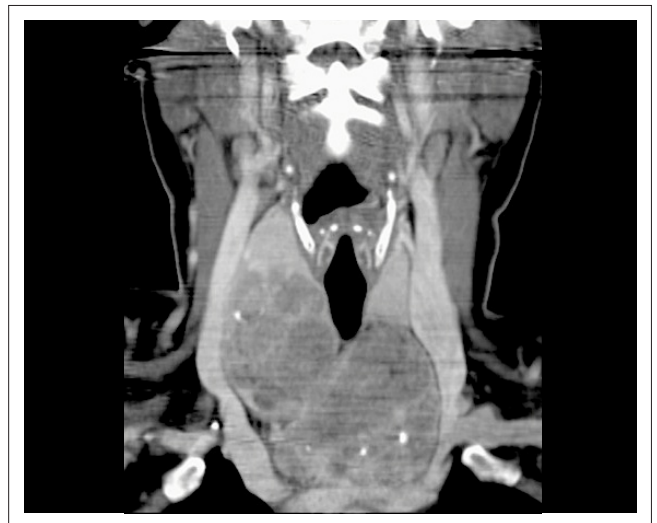

FIGURE 4: Coronal CT scan image of anterior neck triangles.

Describe the relevant findings and provide the most appropriate clinical diagnosis. Please submit your response to Dr Misser at missers@lakesmit.co.za not later than 11 July 2014. The winning respondent will receive a R1000 award from the RSSA. A detailed diagnosis and discussion will be presented later this year.

Read online:



Scan this QR code with your smart phone or mobile device to read online.

Author: Shalendra K. Misser¹

Affiliation: ¹Lake Smit and Partners Inc, Durban, South Africa

Correspondence to: Shalen Misser

Email: missers@lakesmit.co.za

Postal address: Private Bag X08, Overport 4067, Durban, KwaZulu-Natal, South Africa

How to cite this article: Misser SK. Head and neck imaging. *S Afr J Rad.* 2014;18(1); Art. #624, 1 page. <http://dx.doi.org/10.4102/sajrv18i1.624>

Copyright: © 2014. The Authors. Licensee: AOSIS OpenJournals. This work is licensed under the Creative Commons Attribution License.