

# Neovagina creation – laparoscopic Vecchietti-based approach with the new kit

M I Viola, J P van der Merwe, T I Siebert, T F Kruger

Department of Obstetrics and Gynaecology, Faculty of Health Sciences, Stellenbosch University and Tygerberg Academic Hospital, Parow, Cape Town

M I Viola, MB ChB, MMed (O&G), FCOG (Argentina)

J P van der Merwe, MB ChB, MMed (O&G), FCOG (SA)

T I Siebert, MB ChB, MMed O&G, FCOG (SA)

T F Kruger, MB ChB, MMed O&G, FRCOG, MD

**Corresponding author:** T F Kruger (tfk@sun.ac.za)

Mayer-Rokitansky-Kuster-Hauser (MRKH) syndrome is characterised by absence of the vagina and uterus and the presence of normal ovaries. It is a rare congenital anomaly of the female genital tract with a prevalence of 1 in 5 000 female newborns. There is no standard treatment, but a few techniques for creating a vagina, allowing a normal sex life, have been described.

We report on a new laparoscopic vaginoplasty procedure that will create a further option for patients with vaginal agenesis.

*S Afr J OG* 2013;19(1):14-16. DOI:10.7196/SAJOG.564

Mayer-Rokitansky-Kuster-Hauser (MRKH) syndrome is a congenital malformation that is characterised by failure of the Müllerian ducts to develop, resulting in rudimentary uterine horns and fallopian tubes and variable malformations of the vagina in the presence of a normal 46,XX karyotype.<sup>1</sup> This condition is a rare congenital anomaly of the female genital tract, with a prevalence of 1 in 5 000 female newborns.<sup>2</sup>

Type I MRKH syndrome is characterised by the absence of the proximal two-thirds of the vagina and the uterus, while type II affects additional parts of the body.<sup>3</sup>

There is no standard treatment, but a few techniques for creating a new vagina that allow a normal sex life have been described.<sup>4</sup>

## Case report

A 45-year-old woman with primary amenorrhoea presented with inability to have intercourse. No medical or familial history of note was reported.

The patient had had a bilateral inguinal hernia repaired at the age of 14 years. At the age of 27 years she had had a laparotomy, the findings at which were unknown. A laparoscopy was done at the age of 40, during which a pelvic kidney and absence of the uterus were diagnosed.

On physical examination, normal secondary female sexual characteristics were present. Gynaecological examination revealed a normal vulva. Speculum examination of the vagina was not possible owing to shortening of the vagina; instead a vaginal dimple was seen. An abdominal ultrasound scan confirmed the absence of a uterus. Both ovaries were present and a pelvic kidney was seen. At the time of consultation the patient's follicle-stimulating hormone and luteinising hormone levels were

53 mIU/ml and 126 mIU/ml, respectively. She had no interest in fertility treatment.

Laparoscopic creation of a new vagina was based on the Vecchietti method, stretching the vaginal dimple via controlled traction on a mould that was pulled by sub-peritoneal threads which emerged on the surface of the abdomen and were attached to a traction device.

The vaginal dimple was perforated without tunnelling of the vesicorectal space (Fig. 1), the direction of the perforation being checked by means of simultaneous laparoscopy and cystoscopy. The vaginal dimple was pushed towards the abdomen in the direction of the navel with controlled digital pressure. At the same time, the straight thread guide with the two threads attached to the dummy was inserted under the same finger, while the rectum was distanced dorsally with the left middle finger. During this step it is recommended that the surgeon draw the band of the rudimentary uterus upwards ventrally and cranially to ensure that the bladder is not lying over the point of perforation, as described by Brucker *et al.*<sup>5</sup>

The threads were detached from the thread guide and the guide was removed. The curved thread guide was inserted at previously marked points on the abdominal wall and advanced subperitoneally (Fig. 2). Each thread was hooked into the guide and drawn back subperitoneally through the abdominal surface. A suprapubic catheter was inserted under cystoscopic visualisation. The purpose of the suprapubic catheter was to avoid necrosis of the urethra due to pressure of the dummy on the urethra. Lesions of the bladder and rectum were excluded by cystoscopy and rectal examination. Traction from the dummy was applied as cranioventrally as possible (Fig. 3) and the traction device was attached to the abdominal wall surface (Fig. 4), ensuring tension via both threads.

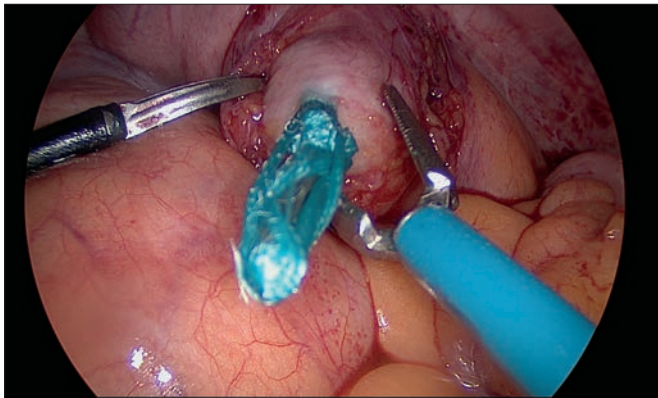


Fig. 1. Perforation of the blind vaginal dimple.

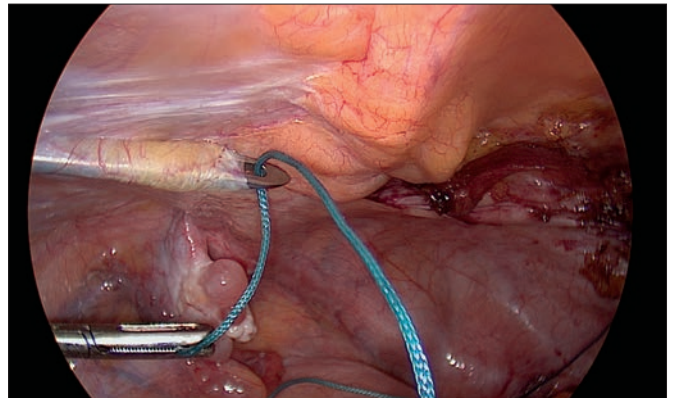


Fig. 2. Curved thread guide inserted sub-peritoneally.

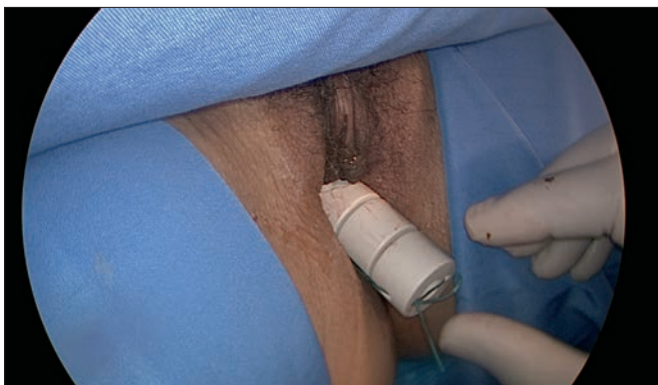

Fig. 3. The vaginal dummy.

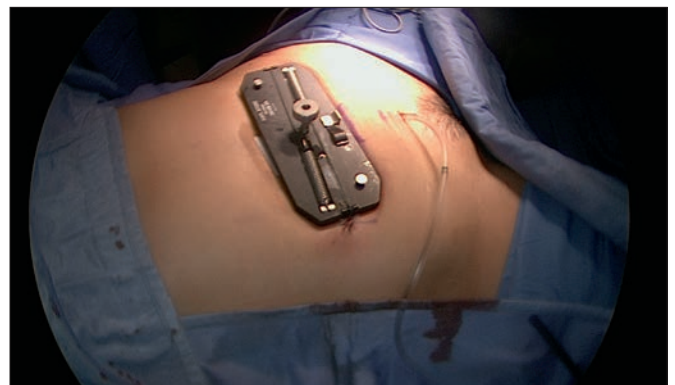

Fig. 4. The traction device.

Pain due to tightening of the traction threads was managed with epidural anaesthesia. Dilators were used for 6 months in combination with liberal application of oestrogen cream to treat oestrogen deficiency and for lubrication. After 3 months the patient started having intercourse. The vaginal size achieved was 7 cm length  $\times$  4 cm width. No surgical complications were described, but vaginitis was reported and treated at a follow-up visit.

## Discussion

Congenital uterovaginal agenesis is most common in women with MRKH syndrome. It can be associated with other rare conditions affecting the urinary and gastrointestinal tracts.

Women with MRKH syndrome have a 46,XX karyotype and normally functioning ovaries, but an absent or rudimentary uterus and a short vagina as a result of failed embryonic development of the Müllerian ducts.<sup>6</sup>

Fertility therapy using surrogacy and assisted reproductive techniques may be an option for these patients. The best treatment for sexual function is still controversial. Vaginal dilatation therapy has been recommended because it is minimally invasive and inexpensive. However, successful sexual function depends on patient compliance and it is recommended that a multidisciplinary team be involved.<sup>7</sup> Successful results with various vaginoplasty techniques have been also described, suggesting that there is no single superior surgical approach.

Successful use of the McIndoe skin graft has been reported by Klingele *et al.*,<sup>8</sup> and this seems to be a safe and effective procedure

with functional results as good as those of the modified Vecchiotti technique, particularly in the subgroup of patients with a pelvic kidney.<sup>8,9</sup> However, poor aesthetic results in the skin graft area have been reported, and together with higher cost due to involvement of a plastic surgical team, long hospitalisation and daily dressing of the graft are some disadvantages of the McIndoe procedure. An additional advantage of the modified Vecchiotti approach is the ability to accurately study the pelvic anatomy.<sup>2,7,9</sup>

Another successful technique is sigmoid vaginoplasty. It is a more complex procedure but when performed by a trained team seems to be a useful method with excellent long-term results. The main advantages are the avoidance of postoperative vaginal dilatation, adequate vaginal length, natural lubrication and satisfactory sexual function with a very low risk of stenosis. However, it is a major procedure involving risks of peritonitis, obstruction, prolapse, adenocarcinoma and colitis of the neovagina.<sup>10-13</sup>

The modified Vecchiotti technique has been described by Fedele and co-workers as simple, safe and effective,<sup>2,9,14</sup> and allows normal and satisfying sexual intercourse when compared with normal controls.<sup>14,15</sup> When the laparoscopic modified Vecchiotti technique is compared with the laparoscopic Davydov approach, anatomical and functional outcomes are comparable for the two procedures.

Vecchiotti's laparoscopic procedure is simpler and faster than the modified Davydov procedure, which also requires a perineal step. The only significant difference is the greater length of the neovagina obtained by the Davydov approach; however, the difference in length has not been reported to impact on sexual quality of life.<sup>16</sup> Davydov's

procedure<sup>17</sup> is particularly useful for patients with abnormalities of the external genitalia, such as female hypospadias, owing to the vaginal step of this approach. However, the presence of a pelvic kidney or previous pelvic surgery contraindicate this procedure.<sup>16,17</sup>

Because the Vecchietti technique leaves the anatomy of the intrapelvic structures unaltered,<sup>17</sup> the surgeon is able to use a second technique if outcome is poor. The original Vecchietti instrument has been improved with the introduction of a new design instrument set, simplifying the use of the dilator and tensioning of the threads.<sup>5,19</sup>

## Conclusion

The ideal technique for vaginal reconstruction should be one with the lowest morbidity and mortality. We report on a new laparoscopic vaginoplasty procedure that creates a further option for patients with vaginal agenesis.

**Acknowledgement.** We thank the High Care Unit at Vincent Pallotti Hospital, Cape Town, for their assistance.

1. Sultan C, Biason-Lauber A, Philibert P. Mayer-Rokitansky-Kuster-Hauser syndrome: Recent clinical and genetic findings. *Gynecol Endocrinol* 2009;25(1):8-11. [<http://dx.doi.org/10.1080/09513590802288291>]
2. Fedele L, Bianchi S, Zanconato G, Raffaelli R. Laparoscopic creation of a neovagina in patients with Rokitansky syndrome: Analysis of 52 cases. *Fertil Steril* 2000;74(2):384-389. [[http://dx.doi.org/10.1016/S0015-0282\(00\)00620-8](http://dx.doi.org/10.1016/S0015-0282(00)00620-8)]
3. Morcel K, Guerrier D, Watrin T, Pellerin I, Leveque J. The Mayer-Rokitansky-Kuster-Hauser (MRKH) syndrome: Clinical description and genetics. *J Gynecol Obstet Biol Reprod* 2008;37(6):539-546. [<http://dx.doi.org/10.1016/j.jgyn.2008.07.002>]
4. Kirsch A, Kaye JD, Carter SM. Mayer-Rokitansky syndrome. Medscape's continually updated clinical reference. Updated 9 March 2009. [www.medscape.com](http://www.medscape.com) (accessed 31 January 2012).

5. Brucker S, Gegusch M, Wolfgang Z, Rall K, Gauwerky J, Wallwiener D. Neovagina creation in vaginal agenesis: Development of a new laparoscopic Vecchietti-based procedure and optimized instruments in a prospective comparative interventional study in 101 patients. *Fertil Steril* 2008;90(5):1940-1952. [<http://dx.doi.org/10.1016/j.fertnstert.2007.08.070>]
6. Nakhil RS, Creighton SM. Management of vaginal agenesis. Mini-Review. *J Pediatr Adolesc Gynecol* 2011. Epub ahead of print. [<http://dx.doi.org/10.1016/j.jpag.2011.06.003>]
7. Ismail-Pratt IS, Bikoo M, Liao LM, Conway GS, Creighton SM. Normalization of the vagina by dilator treatment alone in complete androgen insensitivity syndrome and Mayer-Rokitansky-Kuster-Hauser syndrome. *Hum Reprod* 2007;22(7):2020-2024. [<http://dx.doi.org/10.1093/humrep/dem074>]
8. Klingele CJ, Gebhart JB, Croak AJ, DiMarco CS, Lesnick TG, Lee RA. McIndoe procedure for vaginal agenesis: Long-term outcome and effect on quality of life. *Am J Obstet Gynecol* 2003;186(6):1569-1572. [[http://dx.doi.org/10.1016/S0002-9378\(03\)00938-4](http://dx.doi.org/10.1016/S0002-9378(03)00938-4)]
9. Fedele L, Frontino G, Motta F, Restelli L, Candiani M. Creation of a neovagina in Rokitansky patients with a pelvic kidney: Comparison of long-term results of the modified Vecchietti and the McIndoe techniques. *Fertil Steril* 2010;93(4):1280-1285. [<http://dx.doi.org/10.1016/j.fertnstert.2008.12.020>]
10. Karateke A, Haliloglu B, Parlak O, Cam C, Coksuer H. Intestinal vaginoplasty: seven years' experience of a tertiary center. *Fertil Steril* 2010;94(6):2312-2315. [<http://dx.doi.org/10.1016/j.fertnstert.2010.01.004>]
11. Lima M, Ruggeri G, Randi B, et al. Vaginal replacement in the pediatric age group: a 34-year experience of intestinal vaginoplasty in children and young girls. *J Pediatr Surg* 2010;45(10):2087-2091. [<http://dx.doi.org/10.1016/j.pedsurg.2010.05.016>]
12. Kapoor R, Sharma DK, Singh KJ, et al. Sigmoid vaginoplasty: Long term results. *Adult Urology* 2006;67(6):1212-1215. [<http://dx.doi.org/10.1016/j.urology.2005.12.037>]
13. Khen-Dunlop N, Lortat-Jacob S, Thibaud E, Clément-Ziza M, Lyonnet S, Nihoul-Fekete C. Rokitansky syndrome: Clinical experience and results of sigmoid vaginoplasty in 23 young girls. *J Urol* 2007;107:1107-1111. [<http://dx.doi.org/10.1016/j.juro.2006.11.003>]
14. Fedele L, Bianchi S, Frontino G, Fontana E, Restelli E, Bruni V. The laparoscopic Vecchietti's modified technique in Rokitansky syndrome: Anatomic, functional, and sexual long-term results. *Am J Obstet Gynecol* 2008;198(4):377.e1-6. [<http://dx.doi.org/10.1016/j.ajog.2007.10.807>]
15. Folgueira G, Perez-Medina T, Martinez-Cortes L, et al. Laparoscopic creation of a neovagina in Mayer-Rokitansky-Kuster-Hauser syndrome by modified Vecchietti's procedure. *Eur J Obstet Gynecol Reprod Biol* 2006;127(2):240-243. [<http://dx.doi.org/10.1016/j.ejogrb.2005.11.039>]
16. Bianchi S, Frontino G, Ciappina N, Restelli E, Fedele L. Creation of a neovagina in Rokitansky syndrome: comparison between two laparoscopic techniques. *Fertil Steril* 2011;95(3):1098-1100. [<http://dx.doi.org/10.1016/j.fertnstert.2010.11.032>]
17. Fedele L, Frontino G, Restelli E, Ciappina N, Motta F, Bianchi S. Creation of a neovagina by Davydov's laparoscopic modified technique in patients with Rokitansky syndrome. *Am J Obstet Gynecol* 2010;202(33):e1-6. [<http://dx.doi.org/10.1016/j.ajog.2009.08.035>]
18. Fedele L, Bianchi S, Berlanda N, Fontana E, Bulfoni A, Borruto F. Laparoscopy creation of a neovagina with the laparoscopic Vecchietti operation: Comparison of two instrument sets. *Fertil Steril* 2006;86(2):429-432. [<http://dx.doi.org/10.1016/j.fertnstert.2006.01.043>]
19. Ismail IS, Cutner AS, Creighton SM. Laparoscopic vaginoplasty: Alternative techniques in vaginal reconstruction. *BJOG* 2006;113:340-343. [<http://dx.doi.org/10.1111/j.1471-0528.2005.00845>]