

# Combined abdominal sacrocolpopexy and Burch colposuspension for the treatment of stage 3 and 4 anterior compartment prolapse



H S Cronjé, MB ChB, MMed (O et G), FCOG (SA), MD

J A A de Beer, MB ChB, MMed (O et G)

Division of Urogynaecology, Department of Obstetrics and Gynaecology, University of the Free State, Bloemfontein

**Objective.** To review our experience with sacrocolpopexy and Burch colposuspension for stage 3 and 4 anterior compartment prolapse.

**Methods.** Review of 154 patient records drawn from a urogynaecological database, with stage 3 and 4 anterior compartment prolapse treated by sacrocolpopexy and Burch colposuspension.

**Results.** The median age of the patients was 60 years and a third of them had had previous prolapse surgery. Patients presented with bladder (41%) and bowel (55%) symptoms, and most complained of prolapse protruding through the vaginal introitus (86%). Recurrent prolapse, stage 2 - 4, occurred in 24 patients (15.6%); 9.7% were anterior compartment prolapses. Where mesh was omitted from the anterior vaginal wall but placed on the posterior vaginal wall, significantly more recurrent anterior compartment prolapses occurred (95% confidence interval (CI) 0.2%; 34.8%) compared with cases where mesh was placed both anteriorly and posteriorly to the vagina. Perioperative complications occurred in 13% of patients. A tension-free vaginal tape (TVT) procedure for urinary stress incontinence was done at a later stage in 8% of the patients.

**Conclusion.** Sacrocolpopexy effectively treated anterior compartment prolapse where mesh was attached to the anterior vaginal wall as well. A Burch colposuspension probably did not make a difference.

Anterior compartment prolapse is defined as a pathological descent of the anterior vaginal wall and bladder base.<sup>1</sup> The causation is not completely understood but is probably multifactorial. Nichols and Randall described two types of anterior vaginal wall prolapse – distension and displacement.<sup>2</sup> Distension was thought to occur as a result of overstretching and attenuation of the anterior vaginal wall. Displacement was attributed to pathological detachment or elongation of the anterolateral vaginal supports to the arcus tendineus fasciae pelvis. This process initiated the term ‘paravaginal defect’, which was associated with several defects in the pubocervical fascia.<sup>3</sup> However, in more recent work, an authentic fascial layer could not be demonstrated between the bladder and anterior vaginal wall.<sup>4</sup> The defects described earlier were probably within the endopelvic fascia lateral to the bladder and vagina.

We have observed that anterior (and posterior) vaginal prolapse disappeared when the uterus or vaginal vault was pulled cephalad at laparotomy, unless it had previously been stretched and distended, in which case the prolapse would be reduced only partially. It appeared as if anterior and posterior vaginal compartment prolapse were the result of vaginal collapse following

descent of the pelvic floor and disruption of pelvic organ attachments. This observation correlates with the description of Nichols and Randall,<sup>2</sup> except that on theoretical grounds a suspension procedure should be part of the corrective procedure. We moved away from vaginal procedures such as anterior colporrhaphy to abdominal suspension procedures. The aim of this study was to report on our experience with sacrocolpopexy and Burch colposuspension for stage 3 and 4 anterior compartment prolapse.

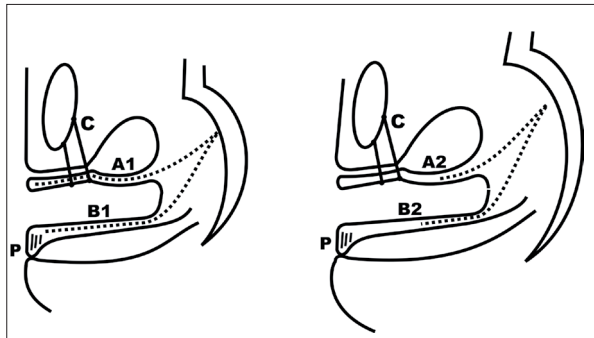
## Patients and methods

A descriptive study was done using data from our urogynaecology database at Universitas Hospital, Bloemfontein. At discharge from hospital, a data sheet was completed for each patient by the attending physician. These were reviewed at weekly departmental meetings and entered into a computer database, which included 913 patient records, covering all the different types of prolapse.

The inclusion criteria for this study were stage 3 or 4 anterior compartment prolapse and the use of Vypro<sup>®</sup> mesh (Johnson and Johnson, Brussels, Belgium) together

with sacrocolpopexy and Burch colposuspension. Initially we used non-absorbable mesh, but since using Vypro® mesh, a semi-absorbable mesh consisting of polypropylene and polyglactin (1:1), our surgical technique was standardised. Therefore, by using Vypro® as an inclusion criterion, we excluded the learning phase.

All patients were managed by the authors. Some patients were operated on by registrars under direct supervision of an author. The POP-Q staging system was used.<sup>5</sup> The surgical approach was by laparotomy. Initially we suspended the vagina with mesh attached posteriorly.<sup>6</sup> Following the occurrence of anterior prolapse, we attached a second mesh anteriorly to the vagina, covering the vagina for about 5 cm. For the same reason we eventually extended the anterior mesh to a level below the bladder base (Fig. 1). To cover the bladder base completely, a midline incision was made vaginally, over the anterior compartment prolapse, with complete exposure of the bladder by lateral dissection. Near the vaginal vault the abdomen was entered through the space already created between the bladder and upper vagina at laparotomy. The mesh was then introduced vaginally and sutured to the vaginal wall around the bladder with the distal end fixed at the level of the mid-urethra. Superiorly the mesh extended into the abdomen and was fixed to the sacrum at S1-2 (Fig. 1).



*Fig. 1. Surgery for cystocele. A1 = mesh completely covering the bladder base; A2 = mesh partially covering the bladder base; B1 = mesh extending from the perineum to sacrum; B2 = mesh extending from mid-vagina to sacrum; C = Burch colposuspension; P = perineal repair.*

A Burch colposuspension was then performed, to support the distal anterior vaginal wall and not for reasons of stress urinary incontinence (SUI), unless the patient presented with SUI. Our aim was to create a complete support of the bladder with the mesh in the midline and the Burch colposuspension laterally.

All patients received a second mesh posteriorly, from the posterior vaginal wall to the sacrum. In most patients, mobilisation of the rectum was performed with a rectopexy where the rectum was elevated, pulled upwards and fixed to the mesh. The reason was the presence of an enterocele in almost all patients

(particularly those without a uterus). A perineal body repair was also done vaginally in patients with a deficient perineal body as judged by rectovaginal examination.

The software for the database was Epi-Info version 6.0 (Centers for Disease Control, Atlanta, Georgia, USA). Follow-up data were also entered into the database. At each follow-up visit a data form was completed and patients who did not return for follow-up were traced by telephone calls or mail. Using a structured questionnaire, these patients' perception of 'something bulging into the vagina' or appearing at the vaginal introitus, as well as bladder, rectal and coital problems, were determined. Statistical analysis consisted of frequency profiles. Analytical analysis consisted of the chi-square test for categorical data (Fisher's exact test for small numbers) with 95% confidence intervals (CI). The study was approved by the Ethics Review Board of the Faculty of Health Sciences, University of the Free State.

## Results

The statistics of 154 patients were collected over a period of 4 years ending in December 2003. The median age was 60 years (range 36 - 86 years), median parity was 3.0 (1 - 8), and 86.7% of the patients were white. Previous surgery for prolapse was reported by 50 patients (32.5%).

The pre- and postoperative symptoms are given in Table I. Of significance was an improvement of digital assistance with defaecation and an decreased incidence of lower abdominal pain postoperatively.

The findings at gynaecological examination preoperatively are given in Table II. Eighty-four patients (54.6%) had an obviously deficient perineal body. In 61 patients (39.6%) the uterus was still intact.

All patients underwent sacrocolpopexy with Vypro® mesh. In 22 patients (14.3%) no mesh was placed anteriorly to the vagina. Of the 132 patients (85.7%) in whom mesh was placed anteriorly to the vagina (Fig. 1), it partially covered the bladder base in 102 patients (66.2%) and completely in 29 (18.8%). In 1 patient (0.6%) the extent of the mesh was unknown. Posteriorly the mesh extended from the perineal body to the sacrum in 101 patients (65.6%), from the mid-vagina to the sacrum in 9 (5.8%), and from the vaginal vault to the sacrum in 44 (28.6%). A hysterectomy was performed on all patients with an intact uterus ( $N=61$ ; 39.6%). A firm plication of the uterosacral ligaments around the mesh was performed on 55 patients (35.7% of the total and 90.2% of the hysterectomy patients). In 132 patients (85.7%) the rectum was mobilised, elevated and attached to the mesh (rectopexy). All patients had a Burch colposuspension. A high posterior repair was done in 89 of the patients (57.8%) and a perineal body repair in 117 (76.0%).

The median volume of intraoperative blood loss was 300 ml (mean 403 ml, range 150 - 2 000 ml), while in

Symptoms	Preoperative		Postoperative		95% CI for percentage difference
	N	%	N	%	
Something protruding through vaginal introitus	130	86.7	0	0	–
Bladder					
Stress urinary incontinence	35	23.3	30	20.0	–12.3%; 5.7%
Urge and urge incontinence	25	16.7	35	23.3	–1.9%; 15.2%
Mixed incontinence	13	8.7	14	9.3	–2.9%; 9.7%
Difficulty in voiding	3	2.0	0	0	–5.7%; 0.8%
Bowel					
Constipation	46	30.7	38	25.3	–13.6%; 3.0%
Digital assistance	32	21.3	19	12.7	–16.5%; –0.9%
Anal incontinence	3	2.0	0	0	–5.7%; 0.8%
Vagina					
Dyspareunia	9	6.0	9	6.0	–5.1%; 5.1%
Other					
Lower abdominal pain	14	9.3	35	23.3	6.9%; 21.3%
Lower back pain	30	20.0	26	17.3	–11.2%; 5.9%

Prolapse	Stage 3 prolapse		Stage 4 prolapse	
	N	%	N	%
Anterior compartment prolapse	105	68.2	49	31.8
Vault prolapse	24	15.6	16	10.4
Enterocoele	56	36.4	15	9.7
Posterior compartment prolapse	58	37.7	9	5.8
Uterine prolapse	34	22.1	5	3.2

50 patients the blood loss was described as 'minimal'. A transurethral catheter was inserted in 146 patients (94.8%) and a suprapubic catheter in 8 (5.2%). The median day of postoperative catheter removal was day 2 (range 1 - 15 days). Nine patients (5.8%) were discharged from hospital with a urinary catheter *in situ*.

Perioperative complications occurred in 20 patients (13.0%), covering a wide spectrum of conditions. The most serious, however, were deep-vein thrombosis (1 patient), pulmonary embolus (1), and rectal perforation (1) with a postoperative acute abdomen that required a re-laparotomy, colostomy and intensive care management. The latter patient recovered well.

Follow-up data were obtained in 150 patients (97.4%). The median duration of follow-up was 15 months (range 1 - 50 months). Recurrent prolapse, stage 2 - 4, occurred in 24 patients (15.6%), of whom 9 (5.8%) underwent repeat surgery. Another 5 patients underwent subsequent surgery for incisional hernia (2 patients), mesh removal (1), laparotomy (1) and closure for colostomy (1). In addition, 12 patients (7.8%) had a tension-free vaginal tape (TVT) procedure for postoperative SUI. The profile of recurrent prolapse (stage 2 - 4) was as follows: 15 anterior compartment prolapses (9.7%), 1 vault prolapse (0.7%), and 16 patients with posterior compartment prolapse (10.4%). Some patients had prolapse on both sides.

Table III summarises the relationship between the length of mesh along the anterior vaginal wall and recurrent prolapse. Significantly more recurrent anterior compartment prolapses occurred in patients with no mesh along the anterior vaginal wall than in those with mesh anteriorly to the vagina (95% CI 0.2%; 34.8%). No significant difference was found when partial and complete insertion below the bladder were compared (95% CI –9.2%; 13.4%). Reviewing recurrent prolapse (all types), similar results were obtained. With no mesh along the anterior vaginal wall, more recurrences (any type) were documented (95% CI 1.5%; 37.8%). Partial or complete insertion of mesh did not make a difference (95% CI –7.4%; 12.8%).

Long-term postoperative complications included SUI (30 patients; 19.5%), urinary urge (35; 22.7%), difficulty in defaecation (19; 12.3%), and constipation (38; 24.7%). Anal incontinence remained a problem in 1 patient and small-bowel obstruction that required laparotomy developed in another.

## Discussion

Anterior compartment prolapse is difficult to manage owing to an absence of well-developed direct support structures, and associated urinary symptoms. A wide variety of surgical methods have been described for the repair of anterior compartment prolapse with results

**Table III. Recurrent anterior compartment prolapse in relation to length of mesh on the anterior vaginal wall (N=150)\***

Length of mesh	Recurrent prolapse		Anterior compartment prolapse (%)
	Yes	No	
None (N=22)	5	17	22.7
≤5 cm (partial) (N=99)	9	93	9.1
>5 cm (complete) (N=28)	1	28	3.6
Unknown (N=1)	0	1	0
Total (N=150)	15	135	

\*Excluding 4 patients without follow-up data.

that differ significantly between different methods, and even within specific techniques. These methods can be divided into three groups:

- Increased support below the bladder
- Lateral fixation of the vagina, and
- Suspension and fixation of the anterior vaginal wall (with or without the posterior wall).

The classic operation for increasing support below the bladder is the anterior colporrhaphy.<sup>7</sup> Results for recurrent bladder prolapse vary tremendously, from 2% to 92% with a mean of 16%.<sup>8</sup> This large variation is understandable in view of the documented absence of fascia between the bladder and vagina.<sup>4</sup> An anterior colporrhaphy probably works by means of formation of fibrosis between the bladder and vagina. Success in preventing recurrent prolapse therefore depends on the strength of this fibrosis. The support beneath the bladder was more recently strengthened by different forms of mesh and other material,<sup>9,10</sup> which seems to deliver better results than anterior colporrhaphy alone.<sup>11,12</sup>

Lateral fixation of the vagina has recently been suggested. The classic operation is paravaginal defect repair.<sup>13</sup> This is a site-specific defect repair with excellent results (7% recurrence of anterior compartment prolapse; 1.6 years' follow-up). The more lateral the dissection extends, the better the results seems to be.<sup>11</sup> Numerous variations on paravaginal repair have been described.<sup>14,15</sup>

Suspension procedures for bladder prolapse can be performed anteriorly (e.g. Burch colposuspension) or superiorly (e.g. sacrocolpopexy). The Burch colposuspension may be used for anterior compartment prolapse,<sup>16</sup> but sacrocolpopexy is more successful. In our experience, a mesh completely covering the bladder base with fixation to the sacrum completely corrects large anterior compartment prolapse.<sup>17</sup> However, in this study we could not demonstrate a difference in recurrent prolapse between partial and complete coverage of the bladder base with mesh.

Although a Burch colposuspension was done in all patients, 12 patients (7.8%) received a TVT procedure at a later stage for SUI. Taking this and the fairly high recurrence rate for bladder prolapse into account (9.7%),

it can be asked whether the Burch colposuspension had a role to play? In our study, SUI decreased from 23.3% to 20.0% pre- to postoperatively, an insignificant decrease. It seems therefore as if the Burch colposuspension did not play a meaningful role, an opinion supported by a recent study.<sup>18</sup> However, in a more recent study by Brubaker *et al.*<sup>19</sup> a Burch colposuspension significantly decreased the incidence of postoperative SUI.

Another observation we have made is that all the patients in this study had an excessively deep and wide cul de sac which we designated an enterocele, although it did not strictly comply to the definition of a true enterocele.<sup>20</sup> In our patients the enterocele was probably formed by a descent of the levator ani muscle and often exaggerated by a previous hysterectomy.<sup>21</sup> This observation has two important implications. Firstly, it fits in with our view that an anterior compartment prolapse is part of a general pelvic organ prolapse with collapse of the vaginal supports. Secondly, repair of anterior compartment prolapse should always be accompanied by a form of posterior compartment repair. We used posterior sacrocolpopexy (Fig. 1) together with rectopexy.<sup>6</sup>

In analyses from the same database where we selected patients with enterocele<sup>6</sup> and uterine prolapse,<sup>22</sup> our recurrence rates for any form of prolapse were 8% and 10%, respectively. The surgical technique was similar for these three studies (including the present study), as well as the follow-up period. Therefore, it seems that an anterior compartment prolapse is a marker for an increased risk for recurrent prolapse (9.7% anterior compartment prolapse, 15.6% for any type of prolapse).

The results of different approaches for the repair of extensive anterior compartment prolapse are difficult to interpret owing to inconsistent criteria for operation, a wide variation of surgical techniques and an absence of well-conducted randomised controlled trials. From the evidence available it seems, however, that abdominal fixation procedures to the sacrum delivered improved results compared with supportive procedures beneath the bladder. This study emphasised the importance of mesh attached to the anterior vaginal wall followed by fixation to the sacrum.

We acknowledge Lientjie Beyer for assistance in the research and Ina Venter for preparing the manuscript.

1. Walters MD, Weber AM. Anterior vaginal prolapse with and without genuine stress incontinence. In: Cardozo L, Staskin D, eds. *Textbook of Female Urology and Urogynaecology*. 1st ed. London: Isis Medical Media Ltd, 2001.
2. Nichols DH, Randall CL. *Vaginal Surgery*. 4th ed. Baltimore: Williams & Wilkins, 1996.
3. Richardson AC, Lyon JB, Williams NL. A new look at pelvic relaxation. *Am J Obstet Gynecol* 1976; 126: 568-573.
4. Farrell SA, Dempsey T, Geldenhuys L. Histologic examination of 'fascia' used in colporrhaphy. *Obstet Gynecol* 2001; 98: 794-798.
5. Bump RC, Mattiasson A, Bo K, et al. The standardization of terminology of female pelvic organ prolapse and pelvic floor dysfunction. *Am J Obstet Gynecol* 1996; 175: 10-17.
6. Cronjé HS. Colposacrosuspension for severe genital prolapse. *Int J Gynaecol Obstet* 2004; 85: 30-35.
7. Beck RP, McCormick S, Nordstrom L. A 25-year experience with 519 anterior colporrhaphy procedures. *Obstet Gynecol* 1991; 78: 1011-1018.
8. Weber AM, Walters MD. Anterior vaginal prolapse: review of anatomy and techniques of surgical repair. *Obstet Gynecol* 1997; 89: 311-318.
9. Groutz A, Chaikin DC, Theusen E, Blaivas JG. Use of cadaveric solvent-dehydrated fascia lata for cystocele repair – preliminary results. *Urology* 2001; 58: 179-183.
10. de Tayrac R, Fernandez H. Surgical repair of cystocele with mesh by the vaginal route. *Am J Obstet Gynecol* 2002; 186: 852-853.
11. Weber AM, Walters MD, Piedmonte MR, Ballard LA. Anterior colporrhaphy: a randomized trial of three surgical techniques. *Am J Obstet Gynecol* 2001; 185: 1299-1306.
12. Maher C, Baessler K, Glazener CM, Adams EJ, Hagen S. Surgical management of pelvic organ prolapse in women. *Cochrane Database of Systematic Reviews* 2004; 4: CD004014.
13. Shull BL, Benn SJ, Kuehl TJ. Surgical management of prolapse of the anterior vaginal segment: an analysis of support defects, operative morbidity, and anatomic outcome. *Am J Obstet Gynecol* 1994; 171: 1429-1439.
14. Cosson M, Collinet P, Occelli B, Narducci F, Crepin G. The vaginal patch plastron for vaginal cure of cystocele. Preliminary results for 47 patients. *Eur J Obstet Gynecol Reprod Biol* 2001; 95: 73-80.
15. Chung SY, Franks M, Smith CP, Lee JY, Lu SH, Chancellor M. Technique of combined pubovaginal sling and cystocele repair using a single piece of cadaveric dermal graft. *Urology* 2002; 59: 538-541.
16. Kjølhede P. Genital prolapse in women treated successfully and unsuccessfully by the Burch colposuspension. *Acta Obstet Gynecol Scand* 1998; 77: 444-450.
17. Cronje HS. Management of an extremely large cystocele. *J Obstet Gynaecol* 2003; 23: 89-90.
18. Baessler K, Stanton SL. Sacrocolpopexy for vault prolapse and rectocele: do concomitant Burch colposuspension and perineal mesh detachment affect the outcome? *Am J Obstet Gynecol* 2005; 192: 1067-1072.
19. Brubaker L, Cundiff GW, Fine P, et al. Abdominal sacrocolpopexy with Burch colposuspension to reduce urinary stress incontinence. *N Engl J Med* 2006; 354: 1557-1566.
20. Holley RL. Enterocoele: a review. *Obstet Gynecol Surv* 1994; 49: 284-293.
21. Symmonds RE, Williams TJ, Lee RA, Webb MJ. Posthysterectomy enterocele and vaginal vault prolapse. *Am J Obstet Gynecol* 1981; 140: 852-859.
22. Cronje HS, de Beer JA. Abdominal hysterectomy and Burch colposuspension for uterovaginal prolapse. *Int Urogynecol J* 2004; 15: 257-260.