



CASE REPORT

Acute generalised exanthematous pustulosis secondary to cotrimoxazole or tenofovir

J Black, R Kruger, R Roberts, R Lehloenya, M Mendelson

Division of Infectious Diseases and HIV Medicine, Department of Medicine, Faculty of Health Sciences, University of Cape Town and Groote Schuur Hospital, Cape Town

J Black, MB ChB, FCP (SA), Dip HIV Man (SA)

M Mendelson, BSc, PhD, MBBS, FRCP (UK), DTM&H

Division of Dermatology, Department of Medicine, Faculty of Health Sciences, University of Cape Town and Groote Schuur Hospital, Cape Town

R Kruger, MB ChB, FCDerm (SA)

R Lehloenya, BSc, MB ChB, FCDerm (SA)

Department of Clinical Laboratory Sciences, Division of Anatomical Pathology, University of Cape Town and National Health Laboratory Service, Groote Schuur Hospital, Cape Town

R Roberts, MB ChB

Corresponding author: J Black (docjohnblack@gmail.com)

Cutaneous adverse drug reactions are a common complication of antiretroviral therapy and of drugs used to treat opportunistic infections. We present a rare case of acute generalised exanthematous pustulosis secondary to cotrimoxazole or tenofovir.

S Afr J HIV Med 2012;13(4):198-200. DOI:10.7196/SAJHIVMED.852

Cutaneous adverse drug reactions (CADRs) are a common complication of antiretroviral therapy (ART) and of drugs used to treat opportunistic infections.¹ The common clinical manifestations range from mild maculopapular eruptions to the more severe recognised spectrum of Stevens-Johnson Syndrome (SJS), toxic epidermal necrolysis (TEN) and drug reaction with eosinophilia and systemic symptoms (DRESS). Occasionally, however, a rare manifestation of CADR occurs which presents a diagnostic dilemma.

Case report

A 24-year-old South African woman was newly diagnosed with disseminated culture-positive tuberculosis (TB) and HIV. Her CD4 count was 77 cells/mm³ and she had no prior TB history (including contacts). The patient was initiated on Rifampin, and cotrimoxazole prophylaxis was started 9 days later. After a further 2 weeks, ART was initiated (tenofovir (TDF), lamivudine and efavirenz).

One month after ART initiation, the patient presented with sudden-onset generalised, pustular, itchy rash, associated with 1 week of fatigue, nausea, vomiting and painful feet. She had renal impairment (creatinine 521 µmol/l) and was anaemic (haemoglobin 6.1g/dl). Treatment with TDF, cotrimoxazole and rifampicin was ceased, and the patient was referred for further assessment.

On examination, she was tachycardic but afebrile. She had a widespread pustular rash sparing the palms and soles (Fig. 1). Pustules were <5 mm in size and monomorphic on an erythematous background, with areas of desquamation on the lower limbs. She had no mucous membrane involvement, but had manifested angular cheilitis and oral candidiasis. Tender hepatomegaly and painful, peripheral sensory neuropathy were noted.

A pus swab from one of the lesions showed neutrophils, but Gram-stain and culture testing were both negative. Testing of a pustule aspirate for varicella zoster virus by polymerase chain reaction (PCR) was also negative. Blood, urine and sputum bacterial cultures were negative, as was syphilis serology, serum cryptococcal latex antigen test and hepatitis B serology. In addition to anaemia, the patient had a leucocytosis of 11.5 x 10⁹/l (93% neutrophils), but her platelet count was normal. She was hypo-albuminaemic (19 g/l) with mild liver dysfunction (total bilirubin 23 µmol/l, alkaline phosphatase 171 U/l, gamma-glutamyl transferase 111 U/l, alanine transaminase 34 U/l and aspartate transaminase 58 U/l). A chest X-ray showed diffuse bi-basal nodularity. Necrotic lymph nodes and multiple splenic hypodensities, suggestive of abdominal TB, were evident on abdominal ultrasound.

Two days after admission, treatment with abacavir was started to replace TDF, and the patient was started on

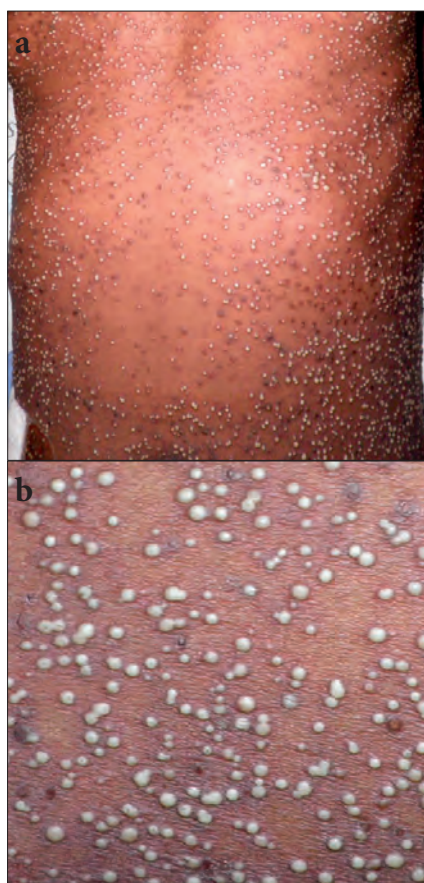


Fig. 1(a and b). Acute generalised exanthematous pustulosis.

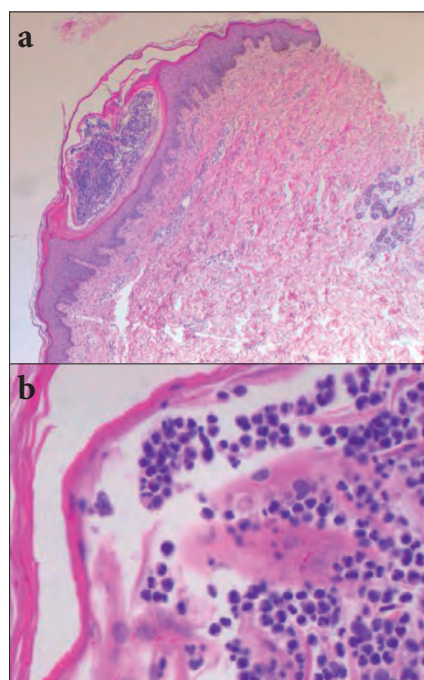


Fig. 2. (a) Intracorneal pustule (x20) containing (b) neutrophils and occasional lymphocytes (x200).

acyclovir, pending the results of investigations. Rifampicin was re-introduced on day 4. Her

rash had considerably improved after 8 days and her creatinine level diminished to 303 $\mu\text{mol/l}$. Renal biopsy was delayed due to the overlying skin lesions.

Histopathology of a skin biopsy on admission showed basket-weave hyperkeratosis, spongiosis and an intracorneal pustule, containing neutrophils and occasional lymphocytes (Fig. 2). Small cocci were noted within the pustule and a mild superficial perivascular lymphocytic infiltrate was present. Superficial dermal vessels were mildly dilated and contained marginated neutrophils. Special stains for fungi and acid-fast bacilli were negative and no granulomas, dysplastic or malignant cells were found. A histopathological diagnosis of acute generalised exanthematous pustulosis (AGEP) was made.

Multi-drug resistant TB (MDR-TB) was subsequently diagnosed on the basis of a urine culture (sampled on admission) and her TB regimen was altered. She was discharged with a clinical diagnosis of acute kidney injury secondary to TDF, disseminated MDR-TB, and AGEP most likely secondary to cotrimoxazole or TDF. She has had a good clinical response and, at the time of writing, remains in care 7 months post discharge.

Discussion

AGEP is an uncommon severe cutaneous reaction associated with drug exposure in 90% of cases. The remaining 10% of cases have been attributed to viral infections, vaccines, spider bites, heavy metal exposure, chemotherapy and radiation.² The reaction has a mortality rate of 2%, typically occurring in the elderly with co-morbidities, and is related to septic complications.² A wide spectrum of pustular skin diseases forms the differential diagnosis, including pustular psoriasis, Sweet's syndrome (acute febrile neutrophilic dermatosis), pustular erythema multiforme, TEN, DRESS and bullous impetigo.^{2,3} In our patient, disseminated varicella was also considered. The combination of clinical and histological features together with appropriate drug exposure is usually enough to make the diagnosis of AGEP.^{2,3}

To date, a single case of AGEP has been described in an HIV-infected patient with a CD4 count of 220 cells/ mm^3 , attributed to boosted darunavir, which recurred on atazanavir re-challenge.⁵ Protease inhibitors (indinavir and boosted lopinavir) have also been implicated in AGEP in patients receiving post-exposure prophylaxis.^{6,7} Nucleoside/nucleotide reverse transcriptase inhibitors

have not been implicated as causal agents. However, there are case reports of AGEP following cotrimoxazole treatment in HIV-negative patients.^{8,9}

The pathophysiology of AGEP involves drug-specific T cell activation by dendritic cells followed by T cell expansion and migration to the dermis and epidermis. The T cells are activated to produce high levels of neutrophil-attracting chemokine (CXCL8) and express a type 1 T-helper (Th-1) cytokine profile (granulocyte-macrophage colony-stimulating factor, interferon gamma and tumour necrosis factor-alpha). Stimulated keratinocytes recruit T cells and neutrophils to the inflamed skin. Drug-specific cytotoxic CD8 T cells are responsible for killing keratinocytes and for vesicle formation, while neutrophils migrate along the CXCL8 gradient into the vesicles to form pustules.² In the case described here, the delayed presentation following initiation of cotrimoxazole, the most likely causative agent, may have been attributed to reduced drug-specific T cell activation in advanced HIV disease.

Characteristic features of AGEP include an acute generalised cutaneous eruption of whitish non-follicular, sterile pustules <5 mm in size and on a background of erythema, which may be accompanied by a burning sensation. Lesions often start on the face or intertriginous areas, moving to the trunk and limbs within a few hours. The reaction rarely affects the palms and soles and has mucous membrane involvement in only 20% of cases. Half of affected patients may report other skin symptoms. The rash lasts for a mean of 9.4 days (range 4 - 10), followed by desquamation. The rash is accompanied by a fever >38°C that lasts for approximately 1 week.³ The onset of rash follows 2 distinct patterns: (i) a rapid onset after drug ingestion (a few hours to 2 - 3 days) which is most commonly associated with antibiotics and may signify previous sensitisation; and (ii) an onset after 1 - 3 weeks (mean 11 days), which may result from primary sensitisation.^{3,4}

A neutrophilia occurs in 90% of cases, while up to 30% have mild eosinophilia. Renal dysfunction (predominantly pre-renal) occurs in one-third of cases. Rarely, hypocalcaemia and a mild elevation in amino-transferases have been observed.^{2,3} The skin biopsy is characterised by spongiform subcorneal or intradermal pustules, papillary oedema and neutrophilic perivascular infiltrates.^{2,3}

When there is doubt over the causal agent, and there are no alternative therapeutic agents,

confirmatory tests may be performed under specialist supervision:

- Drug provocation testing: although the gold standard for CADR, this is contra-indicated in AGEF.¹⁰
- Patch testing: although this has only a 50% sensitivity and 85% specificity, it is the best available test for practical reasons.²
- The lymphocyte transformation test (LTT): requires a specialised laboratory, but has an improved sensitivity of 78% with varying specificity.²

Treatment of AGEF is symptomatic, with withdrawal of treatment with the offending drug. Antibiotics are not indicated unless secondary infection occurs. Corticosteroid treatment has been used, but is not required in the majority of cases.³

Conclusion

This case highlights a rare adverse drug reaction that can occur in HIV-infected patients and is an important differential diagnosis of a pustular eruption. Antibiotics are the most common causative agents, and protease inhibitors are the

most commonly implicated ART drugs. Early recognition and drug withdrawal are vital. If drug re-challenge is required, this should be done under specialist supervision.

Acknowledgments. MM receives support from the President's Emergency Plan for AIDS Relief (PEPFAR)/United States Agency for International Development (USAID) through ANOVA Healthcare.

References

1. Coopman SA, Johnson RA, Platt R, Stern RS. Cutaneous disease and drug reactions in HIV infection. *N Engl J Med* 1993;328:1670-1674. [http://dx.doi.org/10.1056/NEJM199306103282304]
2. Speckaert MM, Speckaert R, Lambert J, Brochez L. Acute generalized exanthematous pustulosis: An overview of the clinical, immunological and diagnostic concepts. *Eur J Dermatol* 2010;20(4):425-433. [http://dx.doi.org/10.1684/ejd.2010.0932]
3. Sidoroff A, Halevy S, Bavinck JN, Vaillant L, Roujeau JC. Acute generalized exanthematous pustulosis (AGEP) – a clinical reaction pattern. *J Cutan Pathol* 2001;28:113-119. [http://dx.doi.org/10.1034/j.1600-0560.2001.028003113.x]
4. Sidoroff A, Dunant A, Viboud C, et al. Risk factors for acute generalized exanthematous pustulosis (AGEP) – results of a multinational case-control study (EuroSCAR). *Br J Dermatol* 2007;157:989-996. [http://dx.doi.org/10.1111/j.1365-2133.2007.08156.x]
5. Bourkia M, Charès L, Lambotte O, OrosteGUI-Giron L, Goujard C, Ghosn J. Life-threatening acute generalized exanthematous pustulosis induced by two different protease inhibitors in an HIV-1-infected patient. *J Antimicrob Chemother* 2011;66(9):2188-2189 [http://dx.doi.org/10.1093/jac/dkr227]
6. Aquilina C, Viraben R, Roueire A. Acute generalized exanthematous pustulosis: a cutaneous adverse effect due to prophylactic antiviral therapy with protease inhibitor. *Arch Intern Med* 1998;158:2160-2161.
7. Ghosn J, Duvivier C, Tubiana R, et al. Acute generalized exanthematous pustulosis induced by HIV postexposure prophylaxis with lopinavir-ritonavir. *Clin Infect Dis* 2005;41(9):1360-1361. [http://dx.doi.org/10.1086/497075]
8. Lee I, Turner M, Lee CC. Acute patchy exanthematous pustulosis caused by sulfamethoxazole-trimethoprim. *J Am Acad Dermatol* 2010;63(2):e41-e43 [http://dx.doi.org/10.1016/j.jaad.2009.11.008]
9. Anliker MD, Wüthrich B. Acute generalized exanthematous pustulosis due to sulfamethoxazol with positive lymphocyte transformation test (LTT). *J Investig Allergol Clin Immunol* 2003;13(1):66-68.
10. Aberer W, Bircher A, Romano A, et al. Drug provocation testing in the diagnosis of drug hypersensitivity reactions: General considerations. *Allergy* 2003;58:854-863. [http://dx.doi.org/10.1034/j.1398-9995.2003.00279.x]

EMBO – Workshop on AIDS-Related Mycoses

3 – 5 July 2013

Cape Town, South Africa

www.aids-and-mycoses-2013.co.za

Venue: Institute of Infectious Disease and Molecular Medicine, University of Cape Town of Cape Town
Organisers: Gordon Brown (UK), Jay Kolls (USA), Graeme Meintjes (SA), Clive Gray (SA), William Horsnell (SA)

This conference will bring together, for the first time, the world's leading researchers dealing with AIDS and AIDS-related mycoses.

Session Topics:

- The effect of HIV/ AIDS on anti-fungal immunity,
 - Epidemiology, surveillance and public health,
- The fungal diseases (Candida, Pneumocystis, Cryptococcus and other pathogens)
 - IRIS
- Treatment options and the way forward

With support from:



CIDRI
CLINICAL INFECTIOUS DISEASES
RESEARCH INITIATIVE



welcome trust

