

TUBERCULOSIS

CLINICAL INSIGHTS INTO THE INTERACTION OF CHILDHOOD TUBERCULOSIS AND HIV IN THE WESTERN CAPE

H Simon Schaaf, MMed (Paed), Mark F Cotton, FCP, Gerrit S de Villiers, FCP, Peter R Donald, MD

Department of Paediatrics and Child Health, University of Stellenbosch and Tygerberg Children's Hospital, Tygerberg, W Cape

The mutually deleterious interaction of HIV infection and tuberculosis (TB) was recognised in adults soon after the scope of the HIV epidemic became evident.¹ It is now clear that in populations with a high incidence of infection due to *Mycobacterium tuberculosis*, clinical TB disease is one of the first signs of declining immunity in HIV-infected adults.²

The HIV/AIDS epidemic impacts on childhood TB, both directly and indirectly, but documentation of this interaction is less certain than for adult TB because of the difficulties in diagnosing childhood TB. Firstly, HIV-infected children probably have the same degree of susceptibility to TB infection and subsequent disease as adults, and secondly, HIV-infected and non-infected children will be exposed to increasing sources of TB because of the impact of HIV/AIDS on adult TB prevalence.

The Western Cape (WC) province of South Africa is an area with a remarkably high incidence of TB. The reported TB notification rate was 589 new cases per 100 000 population per year in 1998 (data from Department of Health: Directorate Health Systems Research and Epidemiology). It is also the province with the lowest prevalence of HIV infection at 5.2% (95% confidence interval (CI) 3.2 - 7.2%) according to the 1998 national HIV survey of women attending public antenatal clinics (data from Department of Health: Directorate Health Systems Research and Epidemiology).

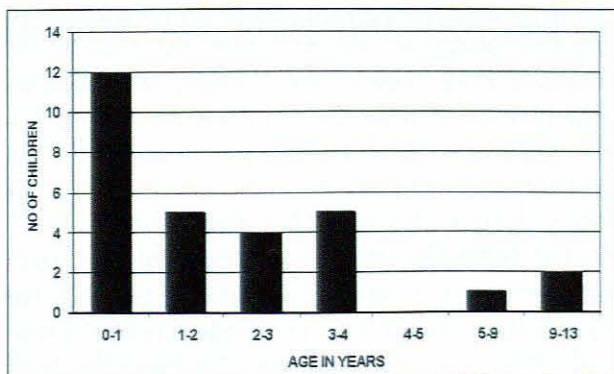



Fig. 1. Age at time of culture-confirmed TB diagnosis in HIV-infected children (N = 29).

TB is often an early opportunistic infection in adults in developing countries as they are already infected with the tubercle bacillus at the time that their immunity starts to decline. In children, the situation may be different because they are almost always primarily infected by mother-to-child transmission of HIV, while the TB infection usually occurs later in life. Therefore, children will more often present with other infections before they develop TB disease. This is confirmed by postmortem studies of young children dying of HIV/AIDS; TB was only found in 1/78 cases in the Ivory Coast³ and in 1/74 children with a median age of 2.7 years in South America.⁴

WESTERN CAPE EXPERIENCE

In our own experience, working in communities with a very high incidence of TB, young HIV-infected children (less than 2 years of age) can develop culture-positive TB⁵ (and H S Schaaf, M F Cotton - unpublished data, 1998 - 2000). (See age distribution in Fig. 1 and final confirmation of HIV diagnosis in Fig. 2). The high incidence of TB in our region is probably responsible for this early increased presentation of TB, which corresponds with the very young age at presentation of a number of infants at King Edward VIII Hospital in KwaZulu-Natal.⁶

At Tygerberg Children's Hospital (TBCH), a tertiary care institution in the WC, the number of HIV-infected children has been rising steadily. During the first 5 years (1992 - 1997) of documenting childhood HIV infection, 135 children were registered as HIV-infected, of whom 14 (10.4%) had culture-confirmed TB.⁵ The following 3 years yielded a further ± 160 cases of HIV infection, with 15 cases of confirmed TB - a constant rate of about 10% (H S Schaaf, M F Cotton - unpublished data). As only 20 - 30% of children with TB yield a positive culture for *M. tuberculosis*, we deduce that between 30% and 50% of HIV-infected children will present with TB at some time during the course of their disease.

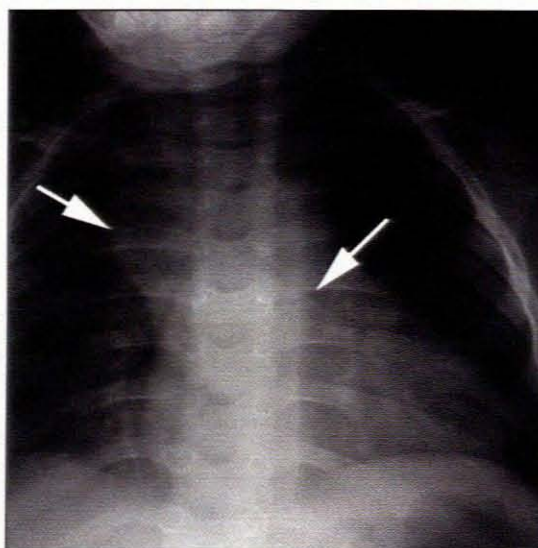
On the other hand, HIV infection among children diagnosed with TB still seems to be relatively low at only 8% of those screened for HIV infection among the culture-confirmed TB cases from 1995 to 1998. The prevalence was much higher in a selected group of patients admitted to Brooklyn Chest Hospital (BCH), a TB hospital in the WC where 26% of 99 children admitted and tested over a period of 1 year (1998) were HIV-infected.

HIV-infected children		
Feature	N	%
Adult TB contact	19	66
Cough > 2 weeks	14	48
Confirmed weight loss	22	76
Hepatomegaly	26	90
Respiratory signs	20	69
Splenomegaly	16	55
Otorrhoea acute/chronic	10	34
Extrapulmonary TB	12	41
Anaemia (Hb < 10 g/dl)	26	90
Mantoux ≥ 15 mm (N = 24)	12	50

Table 1. Symptoms, signs and side-room investigations at culture-confirmed diagnosis of TB in 29 HIV-infected children

DIAGNOSIS OF TB

The diagnosis of TB in children has always been difficult. This problem has been accentuated by HIV infection and its associated lung conditions, which on clinical and radio-



Chest radiograph demonstrating paratracheal and hilar lymph nodes with the compression of the left main bronchus.

logical evaluation can present in similar ways. Over-reporting and over-diagnosis of TB is therefore most likely, and to evaluate the role of TB in HIV-infected children, culture of the *M. tuberculosis* organism remains important.

Criteria suggested by the World Health Organisation (WHO) for diagnosing TB in children, such as weight loss and cough of more than 2 weeks' duration, have become less helpful.⁷ Evaluating 29 children with culture-positive TB at TBCH over a period of 8 years showed that some criteria may still be helpful (Table 1)⁵ (and H S Schaaf, M

F Cotton - unpublished data).

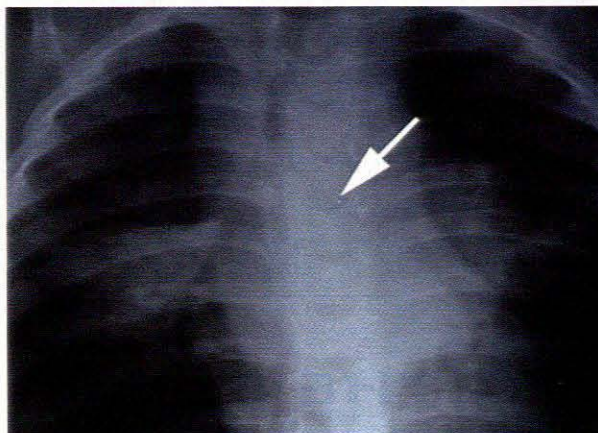
Contact history remains important, and from observations done at BCH it is clear that determining whether the contact has drug-resistant TB is essential. Five of 13 (38%) HIV-infected children with culture-confirmed TB admitted over a 1-year period had drug-resistant TB, 4 of whom had received previous TB treatment. Three of the latter 4 children had previously had drug-sensitive TB, but thereafter had contact with adults with drug-resistant TB. In some cases this involved the same adult who also developed drug-resistant TB after previously being fully sensitive.

Tuberculin skin tests have often been reported to be of little value in dually infected children mainly from developed countries.⁸⁻¹¹ However, in our series, 50% of 24 culture-proven TB cases had a Mantoux test of ≥ 15 mm⁵ (H S Schaaf, M F Cotton - unpublished data). That no child had a Mantoux size between 5 mm and 14 mm leads one to consider an 'all or nothing' type of response to the tuberculin test. More important, this shows that the Mantoux test remains a useful tool in the diagnosis of TB in children. It is even truer than in the past that a negative tuberculin skin test does not exclude the diagnosis of TB. These children probably had significant tuberculin reactions because they presented quite early in the course of their HIV disease and probably still had relatively good immunity. Clinical signs are not of much help in terms of diagnosing TB in children.¹²

Extrapulmonary TB such as lymph node TB, tuberculous meningitis and abdominal TB are reported to be present in about 25% of children with TB.¹³ Extrapulmonary TB has been reported to be more common in adults with HIV infection. Forty-one per cent of the children in our series had confirmed extrapulmonary TB⁵

(H S Schaaf, M F Cotton - unpublished data) - a finding that should be interpreted with care, however, since complicated cases of TB are more often referred to hospital and this could lead to selection bias. What is evident though, is that every available body fluid or biopsy specimen, even unlikely sources such as ear swabs, should be sent for culture of *M. tuberculosis*.⁵

Interpreting chest radiographs in HIV-infected children has become increasingly difficult. The reticulo-nodular pattern typical of miliary TB can be identical to lymphoid interstitial pneumonia (LIP), and both conditions could have enlarged hilar and/or mediastinal lymphadenopathy. Hepatosplenomegaly occurs in both and is also of no value with regard to diagnosis. Furthermore, patients with LIP may also develop TB. Recurrent pneumonias, more nonspecific presentations of LIP, bronchiectasis, *Pneumocystis carinii* pneumonia and other lung conditions may add to the diagnostic dilemma. We have observed a very high prevalence of significant paratracheal adenopathy (52%), hilar adenopathy (67%), and bronchial compression (30%), the latter even in older children (2 - 3 years of age), in 27 culture-confirmed cases⁵ (H S Schaaf, M F Cotton - unpublished data). (See radiographs) This incidence is significantly higher than in HIV-negative patients.¹²



The child's culture susceptibility pattern followed that of the mother despite adherence to treatment.

The duration of treatment for TB in HIV-infected children remains controversial. In the light of our experience we suggest that the minimum period of treatment should be 9 months. Furthermore, close monitoring with chest radiographs and follow-up cultures for *M. tuberculosis* is important, and previous diagnosis and treatment for TB should not prevent the clinician from considering this curable disease when the patient presents with a clinical or radiological picture that could fit the diagnosis.

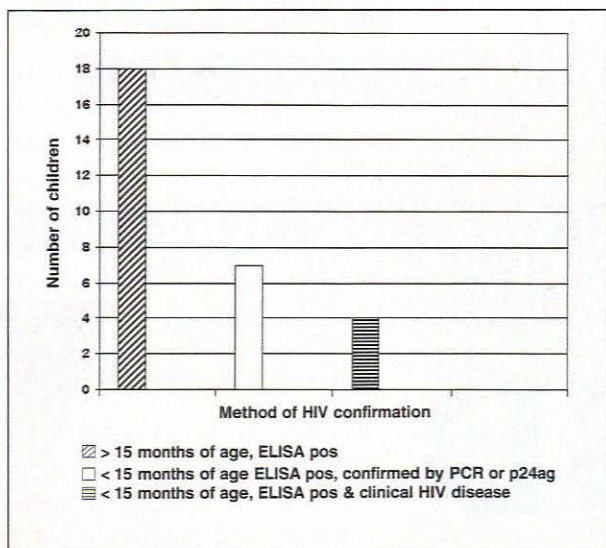


Fig. 2. Final confirmation of HIV diagnosis in children with confirmed TB (N = 29) (ELISA = enzyme-linked immunosorbent assay, PCR = polymerase chain reaction; p24ag = p24 antigen test)

RELAPSE OF TB

Relapse (re-activation or re-infection) occurred in 10 of our patients (34%). Two children had been on treatment for between 4 and 5 months when *M. tuberculosis* was again cultured. In the remainder, TB was reconfirmed by culture after a median of 23 months (range 10 - 83 months) of initial diagnosis. We recently confirmed by DNA fingerprinting that one of these patients had true reactivation.¹⁴ Drug susceptibility testing was available for 6 patients, with only 1 child drug-resistant. His mother initially had drug-susceptible TB and developed multidrug-resistant TB over a period of 28 months.

REFERENCES

- Pitchenik AE, Fertel D, Bloch AB. Mycobacterial disease: epidemiology, diagnosis, treatment, prevention. *Clin Chest Med* 1988; **9**: 425-441.
- Subcommittee of the Joint Tuberculosis Committee of the British Thoracic Society. Guidelines on the management of tuberculosis and HIV infection in the United Kingdom. *BMJ* 1992; **304**: 1231-1233.
- Lucas SB, Peacock CS, Hounnou A, et al. Disease in children infected with HIV in Abidjan, Côte d'Ivoire. *BMJ* 1996; **312**: 335-338.
- Drut R, Anderson V, Greco MA, et al. Opportunistic infections in paediatric HIV infection: a study of 74 autopsy cases from Latin America. The Latin America AIDS Pathology Study Group. *Pediatr Pathol Lab Med* 1997; **17**: 569-576.
- Schaaf HS, Geldenhuys A, Gie RP, Cotton MF. Culture-positive tuberculosis in human immunodeficiency virus type 1-infected children. *Pediatr Infect Dis J* 1998; **17**: 599-604.
- Adhikari M, Pillay T, Pillay DG. Tuberculosis in the newborn: an emerging disease. *Pediatr Infect Dis J* 1997; **16**: 1108-1112.
- World Health Organisation. WHO tuberculosis programme framework for effective tuberculosis control. WHO/TB/94. Geneva: WHO, 1994: 179.
- Moss WJ, Dedyo T, Suarez M, Nicholas SW, Abrams E. Tuberculosis in children infected with human immunodeficiency virus: a report of five cases. *Pediatr Infect Dis J* 1992; **11**: 114-120.
- Khouri YF, Mastrucci MT, Hutto C, Mitchell CD, Scott GB. Mycobacterium tuberculosis in children with human immunodeficiency virus type 1 infection. *Pediatr Infect Dis J* 1992; **11**: 950-955.
- Bakshi SS, Alvarez D, Hilfer CL, Sordillo EM, Grover R, Kairam R. Tuberculosis in human immunodeficiency virus-infected children. *Am J Dis Child* 1993; **147**: 320-324.
- Chan SP, Birnbaum J, Rao M, Steiner P. Clinical manifestation and outcome of tuberculosis in children with acquired immunodeficiency syndrome. *Pediatr Infect Dis J* 1996; **15**: 443-447.
- Schaaf HS, Beyers N, Gie RP, et al. Respiratory tuberculosis in childhood: The diagnostic value of clinical features and special investigations. *Pediatr Infect Dis J* 1995; **14**: 189-194.
- Rieder HL, Snider DE jun., Cauthen GM. Extrapulmonary tuberculosis in the United States. *Am Rev Respir Dis* 1990; **141**: 347-351.
- Schaaf HS, Gie RP, van Rie A, Seifart HI, van Helden PD, Cotton MF. Second episode of tuberculosis in an HIV-infected child: Relapse or reinfection. *J Infect* (in press).