




Muscle ultrasound: a reliable bedside tool for dietitians to monitor muscle mass

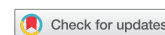Lizl Veldsman^{a*} , Alison Lupton-Smith^b, Guy A Richards^c  and Renée Blaauw^a 

^aDivision of Human Nutrition, Department of Global Health, Stellenbosch University, Cape Town, South Africa

^bDivision of Physiotherapy, Department of Health & Rehabilitation Sciences, Stellenbosch University, Cape Town, South Africa

^cDivision of Critical Care, University of the Witwatersrand, Johannesburg, South Africa

*Correspondence: lizveld@gmail.com



Objectives: Monitoring muscle mass (cross-sectional area [CSA]) and quality (echogenicity) using ultrasound may help optimise nutrition support in the critically ill. However, to date, ultrasound imaging has not been included in the undergraduate training of dietitians, who are mostly responsible for the nutrition care of critically ill patients. This study assessed the accuracy and reliability of bedside imaging performed by a dietitian trained according to standardised methodology, followed by blinded analyses.

Methods: Two operators (a trainer and dietitian trainee) performed B-mode ultrasonography of the rectus femoris quadriceps muscle. For inter-rater accuracy, imaging was performed independently on 32 subjects by both operators, and for intra-rater reliability both obtained a second image on 15 subjects. A blinded assessor performed analyses (CSA and echogenicity) on all images. In a subset of 11 subjects, a musculoskeletal sonographer repeated all measurements. Inter- and intra-rater reliability were determined by calculating intraclass correlation coefficients (ICC), based on an absolute-agreement, 2-way mixed-effects model. An ICC > 0.75 was classified as good and > 0.90 as excellent.

Results: Intra- (ICC = 0.9–0.94) and inter-rater (ICC = 0.85–0.95) reliability of the imaging performed was good to excellent. No statistically significant differences were found between the two operators (mean difference for CSA = 0.18 cm², 95% CI = –0.38–0.03, *p* = 0.08; mean difference for echogenicity = 6.88, CI = –0.71–14.78, *p* = 0.07). Inter-rater reliability for image analyses was excellent (ICC = 0.97–1.0).

Conclusion: Bedside ultrasound performed by a dietitian trained according to standardised methodology shows good to excellent reliability and reproducibility. Training dietitians to perform bedside ultrasound may help to monitor muscle mass and quality in the critically ill.

Keywords: critical illness, ICU, muscle mass, muscle quality, bedside ultrasound, nutrition, ICU recovery

Introduction

Despite a marked decline in intensive care unit (ICU) mortality over recent years, ICU survivors often suffer from severe muscle loss^{1–3} with extensive impairment of physical functioning and health-related quality of life,^{1,2,4–7} which may carry on for years after hospital discharge.^{8,9}

The presence of systemic inflammation, organ dysfunction, anabolic resistance, prolonged bedrest and mechanical ventilation, reduced peripheral blood flow, insulin resistance, pharmacological agents, insufficient nutritional intake, as well as individual patient factors, such as old age, poor pre-morbid nutritional status and comorbidities, all contribute to muscle loss in critical illness.^{1,2,10–13} As one of the primary objectives of providing nutritional care in the ICU is to stop or attenuate muscle atrophy, there is a need for an easy and accessible tool to measure and monitor muscle mass.^{1,14,15} Owing to their dedicated training in clinical nutrition, critical care dietitians are equipped to assess patients' nutritional status,^{16,17} and to formulate and implement individualised nutritional plans pre-, during and post-ICU admission.¹⁸ Although several conventional methods are available to assess nutritional status, such as weight monitoring, bio-electrical impedance analysis (BIA) and circumferences, the validity of these methods is affected by fluid shifts and oedema, a phenomenon commonly encountered in the ICU.^{14,19} Weight and body mass index (BMI) are also unable to differentiate between adipose and lean tissue and fluid that has accumulated.¹⁹

Furthermore, although computed tomography (CT) is regarded as the gold standard to assess muscle mass, because it can visually distinguish muscle mass from other tissues,¹⁵ CT imaging cannot be ordered for the sole purpose of body composition analysis and can only be used if already ordered as part of a patient's medical management plan. As such, CT imaging is not always available for every patient and also not always in a timely manner that would allow for serial monitoring of body composition.

Recently, muscle ultrasound (US) has emerged as a non-invasive, safe and easy-to-use bedside tool to measure muscle mass in the ICU.^{1,12,15,20–23} Puthuchery et al.³ demonstrated a 10.3% drop in US-derived rectus femoris cross-sectional area over the first seven days in ICU and low muscle mass forms part of the Global Leadership Initiative on Malnutrition (GLIM) criteria for the diagnosis of malnutrition.²⁴ Measuring muscle mass may help to identify high-risk patients at baseline and repetitive measurements may help guide nutrition therapy towards reducing the muscle loss both in ICU and after discharge.¹³

In addition to quantifying muscle mass, US can also assess muscle quality by quantifying muscle echogenicity, or measuring the reflection of sound waves.^{12,21,25} Lower muscle echogenicity indicates higher muscle density and quality and, because healthy muscle tissue contains little adipose or fibrous tissue, it causes minimal sound reflection. Conversely,

Table 1: Factors affecting the accuracy and reliability of ultrasound measurements

Factor	Recommendation	Rationale for recommendation
1. Choice of equipment and type of probe	Ultrasound (US) device with a bi-dimensional mode and linear transducer or probe (frequency 7–13 MHz) ¹⁴	To allow high-resolution images of superficial structures (e.g. muscle tissue) to be obtained ¹⁴
2. Choice of muscle	Rectus femoris (RF) quadriceps muscle ¹²	Lower limb muscles are at greater risk of early atrophy compared with upper limbs. Quadriceps muscle is the largest muscle group of the lower limb, and the RF is easy to visualise ¹²
3. Landmarking	One-third distance between the superior border of the patella and the anterior superior iliac spine (ASIS) ¹⁴	Midway or one-third from the proximal patella to ASIS allows for best visualisation of the entire muscle ^{14,27}
4. Measurements of muscle mass: quadriceps muscle layer thickness versus RF CSA	RF CSA over quadriceps muscle layer thickness ²⁸	Literature suggests that RF CSA is a more precise estimate of muscle loss compared with quadriceps muscle layer thickness ^{27,28}
5. Patient positioning	Supine position with knees extended and toes pointing upwards ¹⁴	The most frequently used position, which allows the patient to be placed in the same static position with repeat imaging. Using an angle (e.g. 30° or 45°) of head of bed elevation could introduce error with repeat imaging ¹⁴
6. Probe positioning	Transducer should be oriented transversally to the longitudinal axis of the thigh, forming a 90° angle to the skin surface ^{14,29}	This allows for a cross-sectional view of the shortest axis of the muscle. ²⁹ Tilting or moving the probe from its original position and angle may cause an incorrect measurement. ¹⁴ The angle of the probe and the orientation of the scanned image (longitudinal or transverse) can also impact the accuracy of the echogenicity measurement ²⁵
7. Technical settings (e.g. gain, distortion minimisation)	Standardised settings are important, especially with serial measurements in order to compare changes over time	Adipose tissue and subcutaneous oedema can substantially impact the appearance and quality of the US images obtained. Hence, technical settings such as gain and depth should be considered ¹²
8. Amount of water-soluble gel and compression level	The US probe should be sufficiently covered with water-soluble gel and minimal compression is recommended, especially when measuring RF CSA ¹⁴	The US probe should be adequately covered with water-soluble gel so that distortion is minimised, ¹⁴ and minimal pressure should be applied to the tissue under the probe to allow for best visualisation of the entire RF muscle CSA ^{12,14}

US: ultrasound; RF: rectus femoris; CSA: cross-sectional area; ASIS: anterior superior iliac spine; QMLT: quadriceps muscle layer thickness.

an increase in muscle echogenicity relates to an increase in intra-muscular adipose and fibrous tissue, indicating disease state, and is linked to lower muscle strength and function.²⁵

To date, a number of studies have been performed using US as a means to assess muscle mass and quality in the ICU. However, the methodology used has been inconsistent, with not all reporting on the reliability, reproducibility and accuracy of their methodology.^{13,19,26} As various factors such as choice of equipment, probe and patient positioning, choice of muscle, landmarks used, US settings such as gain, compression level and distortion minimisation may affect the reliability of the results (Table 1), a standardised procedure along with a formal training programme is paramount to ensure consistency of methodology in clinical practice.^{13,19,26}

Training critical care dietitians to perform bedside US may allow them to incorporate these findings directly into the patient's nutritional assessment and monitoring plans, thereby further optimising nutritional care and minimising muscle loss.²³ This pilot study nested within a larger intervention trial aimed to determine the accuracy and reliability of imaging performed by a dietitian with no prior US experience, and of analyses by a blinded assessor.

Methodology

We conducted a prospective observational pilot study to determine the accuracy and reliability of the two-step process involved in rectus femoris quadriceps US imaging for the purpose of body composition analysis in a convenience sample of critically ill patients admitted to an adult surgical

ICU in a tertiary hospital, after approval from the Stellenbosch University (SU) Health Research Ethics Committee 1 (HREC 1) (M20/08/023), as well as the Western Cape Department of Health and Hospital management. The methods process and hence reliability testing involved two steps: first, US image acquisition performed at the bedside by a trainer and a dietitian trainee, and, second, the blinded analysis of the acquired US images using specialised software. Hereinafter, the term 'operator' refers to the individual who conducted the US image acquisition at the bedside, i.e. the trainer or dietitian trainee, while the 'assessor' refers to the individual who conducted the blinded image analyses on computer software at a later date. Figure 1 shows a graphical display of the flow of the pilot study. For step 1, both operators acquired US images independently on a total of 32 ($n = 32$) subjects. In 15 ($n = 15$) both operators acquired a second image on a separate occasion on the same day. This was followed by step 2 where a blinded assessor analysed the acquired US images for all subjects ($n = 32$) by measuring rectus femoris cross-sectional area and echogenicity on specialised software. In a subset of 11 subjects, a second assessor, namely a registered musculoskeletal sonographer, blinded to the primary assessor's analyses, repeated all measurements (rectus femoris cross-sectional area and echogenicity). All procedures were followed in accordance with the ethical standards of the SU HREC and Declaration of Helsinki.

Training prior to conducting the study

For the US image acquisition technique, a standardised operating procedure (Supplementary file 1) based on a similar method published by Parry et al.³⁰ and Martín et al.¹⁴ was compiled and approved by a registered musculoskeletal sonographer. A

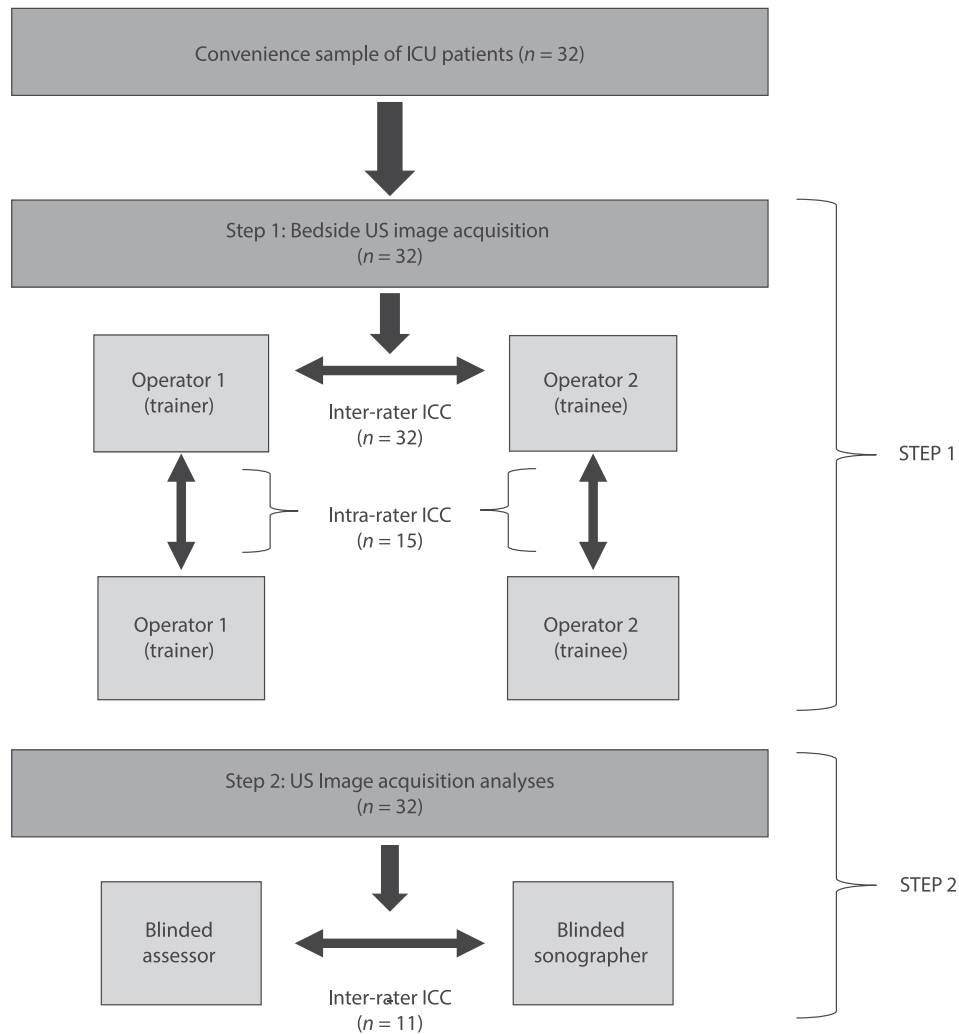


Figure 1: Graphical display of the study flow. ICU: intensive care unit; US: ultrasound; ICC: intraclass correlation coefficients, US: ultrasound.

dietitian trainee with no prior US experience was trained as per the standardised operating procedure (SOP) by a trainer with previous training and experience in the procedure. In short, the training involved a review of the written instructions as per the SOP of the portable US device, then observation of a hands-on demonstration on an actual patient, followed by performance of multiple measurements on patients under direct supervision.

Ultrasound imaging technique

In accordance with the SOP, the two operators performed B-mode US using a 4–12 MHz linear transducer array (Philips Lumify 795005[®], Philips, South Africa) to obtain an anterior image of the rectus femoris quadriceps muscle on the right leg. Two images were acquired for each subject. First, the operator positioned the subject supine with the knee in passive extension and neutral rotation. Using a measuring tape, a point one-third of the distance from the superior border of the patella to the anterior superior iliac spine (ASIS) was then measured in centimetres, and marked as the point at which the US would be performed. Thereafter the transducer was placed transversally in relation to the longitudinal axis of the anterior thigh, forming a right angle to the skin surface with the depth altered to obtain the best image of the rectus femoris (with all borders of the muscle visible on the image). The image was obtained with minimum probe compression. For inter-rater accuracy, imaging was performed independently

on all subjects ($n = 32$) by both investigators, and for intra-rater reliability, both operators obtained a second image in a subset of subjects ($n = 15$) on a separate occasion on the same day, whilst keeping the gain and depth constant. Images were exported to a hard drive for further analysis (cross-sectional area and echogenicity) by a blinded assessor.

Image acquisition analyses

Blinded image acquisition analyses were performed on all subjects ($n = 32$) by a previously trained and experienced assessor according to a method similar to that of Parry et al.³⁰ using ImageJ software (NIH, Bethesda, MD, USA). The rectus femoris cross-sectional area was measured at the widest point of the muscle and reported in centimetres squared, plus echogenicity in pixels.³⁰ Echogenicity was determined by quantitative grey-scale analysis of a 2 cm x 2 cm region of interest in the muscle, where gain had been standardised.³⁰ The means and standard deviation were calculated using the histogram function in the software and expressed as a value between 0 (= black) and 255 (= white). Both measurements (i.e. rectus femoris cross-sectional area and echogenicity) were repeated three times and the average of each, provided all three measurements were within 10% of another, were used for analysis.³⁰

In a subset of subjects ($n = 11$), a registered musculoskeletal ultrasonographer, blinded to the primary assessor's analyses,

repeated all measurements (cross-sectional area and echogenicity) as per the standardised operating procedure to determine the accuracy of the blinded analyses.

Statistical analyses

The distribution of continuous variables was assessed with the Shapiro–Wilk test. Based on the outcome, an independent sample t-test was used for normally distributed data and the results presented as means and 95% confidence intervals. In the case of non-normal data distribution, a Wilcoxon rank sum test was used and the data presented as median and interquartile range. All values were reported with statistical significance set at $p < 0.05$.

Inter- and intra-rater reliability were determined by calculating intraclass correlation coefficients (ICC) and 95% confidence intervals, based on an absolute-agreement, 2-way mixed-effects model. ICC values were classified as poor (ICC < 0.50), fair (ICC = 0.50–0.75), good (ICC = 0.75–0.90) and excellent (ICC = 0.90–1.0). Intra-rater reliability was determined as follows: $ICC = \text{between-subject variance} / (\text{between-subject variance} + \text{within-subject variance})$. Between-subject variance refers to the variance between images/measurements obtained by the same operator on different subjects, and within-subject variance to the variance between different images/measurements obtained from an individual operator on the same subject. Conversely, interrater reliability refers to the variance between the two operators' images/measurements of the same subject. The reliability was determined by the ICC as set out above, with the exception that *within-subject variance* was now the variance between the two operators' images of the same subject. Interrater reliability was also applied to determine the variance between the blinded assessor and registered sonographer's blinded analyses of the same US image.

Results

Reliability of US imaging technique

As set out in Table 2, the trainer yielded a mean rectus femoris cross-sectional area of 4.14 (3.49–4.79) cm² (median 3.96 cm²), and the trainee recorded a mean rectus femoris cross-sectional area of 3.97 (3.29–4.64) cm² (median 3.63 cm²). There were no statistically significant differences between the two operators with a mean difference of 0.18 cm² (–0.38–0.03), $p = 0.08$. For

rectus femoris echogenicity, the trainer recorded a mean of 82.75 (68.92–96.58) pixels (median 81.59 pixels) and the trainee recorded a mean of 89.63 (75.04–104.34) pixels (median 77.30 pixels). Again, there were no statistically significant differences between the two operators with a mean difference of 6.88 pixels (–0.71–14.78), ($p = 0.07$).

Inter- and intra-rater reliability testing for both the US imaging technique and image acquisition analyses is presented in Table 3. Thirty-two ($n = 32$) pairs of between-operator measurements were evaluated with a mean inter-rater ICC of 0.95 and 0.85 for rectus femoris cross-sectional area and echogenicity respectively. In a subset of 15 subjects, where a second measurement was obtained by both operators, an intra-rater ICC of between 0.91 and 0.94 was obtained.

Reliability of image acquisition analyses

As listed in Table 3, 11 pairs of between-assessor measurements were evaluated for the blinded image acquisition analyses. These showed a mean inter-rater ICC of 1.00 and 0.97 for RF echogenicity and rectus femoris cross-sectional area respectively.

Discussion

One of the main objectives of the provision of nutritional support to ICU patients is to stop or attenuate the loss in muscle mass.^{1,14,15} Consequently, it is essential that dietitians have access to an easy and accessible tool to monitor muscle mass during critical illness.^{1,14,15} According to Rodrigues et al.,¹ conventional nutritional screening tools, such as the Subjective Global Assessment (SGA), or nutritional assessment tools, such as anthropometry, biochemical nutritional markers, and bio-electrical impedance analysis, are influenced by several factors, such as oedema, changes in serum inflammatory markers, as well as trauma-related anatomical changes, or patient sedation, which makes obtaining an accurate nutrition history challenging.^{1,14,19} Conversely, musculoskeletal US offers a cheap, non-invasive and easy-to-operate bedside tool to assess muscle mass at baseline as part of the initial nutritional and risk assessment and thereafter to monitor change over time, as a guide to optimising nutritional and physical therapy.¹³ In a previous retrospective analysis of prospectively obtained US data at ICU admission,¹⁵ US-derived rectus femoris cross-sectional area measurements correlated well

Table 2: Inter- and intra-rater reliability for ultrasound imaging and blinded analyses

Factor	Sample size (n)	Intra-class correlation coefficient (ICC)	95% CI	
			Lower limit	Upper limit
Reliability of ultrasound imaging technique				
Intra-rater reliability				
CSA of RF (Operator 1)	15	0.94	0.83	0.98
CSA of RF (Operator 2)	15	0.92	0.79	0.97
Echogenicity of RF (Operator 1)	15	0.91	0.74	0.97
Echogenicity of RF (Operator 2)	15	0.94	0.83	0.98
Inter-rater reliability (between 2 operators)				
CSA of RF	32	0.95	0.90	0.98
Echogenicity of RF	32	0.85	0.71	0.92
Reliability of ultrasound image acquisition analyses				
Inter-rater reliability (between blinded assessor and sonographer)				
CSA of RF	11	1.00	1.00	1.00
Echogenicity of RF	11	0.97	0.89	0.99

CSA: cross-sectional area, RF: rectus femoris, VI: vastus intermedius.

Table 3: Mean difference between operators' ultrasound imaging of the rectus femoris muscle

Factor	Rectus femoris CSA			p-value	Rectus femoris echogenicity			p-value
	Mean (cm ²)	−95% CI	+95% CI		Mean (pixels)	−95% CI	+95% CI	
Operator 1 (trainer)	4.14	3.49	4.79		82.75	68.92	96.58	
Operator 2 (trainee)	3.97	3.29	4.64		89.63	75.04	104.34	
Mean difference between operators	0.18	−0.38	0.03	0.08	6.88	−0.71	14.78	0.07

CI: confidence interval; CSA: cross-sectional area.

with CT-derived total muscle cross-sectional area at the level of the third lumbar vertebra (L3), and it was possible to assess low muscularity at ICU admission based on established CT-derived cut-offs for low muscularity. The literature, however, emphasises that an SOP is key to ensuring consistency of technique as described above,¹³ and although Tillquist et al.³¹ showed good intra- and inter-reliability of muscle US imaging performed by range of operators with no prior US experience, including dietitians, these were based on measurements of quadriceps muscle layer thickness in healthy volunteers, whereas rectus femoris cross-sectional area is regarded as superior to quadriceps muscle layer thickness in estimating muscle loss in critically ill patients.^{13,27} Recently, Baston et al.³² found good interrater reliability (ICC 0.87; 0.54–0.97) for US imaging of the RF CSA in 15 critically ill patients when a standardised protocol was followed, but their imaging was performed by trained sonographers. In our study US imaging of the RF muscle performed by a dietitian trained according to standardised methodology showed good to excellent intra- and inter-rater reliability (ICC = 0.85–0.95).³¹ Training dietitians to perform bedside US may hence offer a reliable tool to identify and monitor high-risk patients with low muscle mass and quality. When monitoring muscle quality (echogenicity) over time, the same dietitian should ideally perform serial imaging, given the stronger ICC for intra-rater reliability (> 0.90) versus inter-rater reliability (0.85) that was observed in this study. Our study also shows excellent inter-rater reliability between the two blinded assessors who performed the image acquisition analyses (i.e. CSA and echogenicity measurements using appropriate software) and future studies should investigate the reliability of such measurements when performed by dietitians.

Limitations

A limitation of our study was that the two operators did not perform a second measurement on all subjects, and that the registered musculoskeletal sonographer also only repeated the cross-sectional area and echogenicity measurements in a subset, decreasing the strength of the study. Furthermore, although this study established excellent reliability for US images acquired by a registered dietitian trainee, the reliability of dietitian involvement in the second step, i.e. image acquisition analyses, should still be established in future studies.

Conclusion

This study shows good to excellent intra-rater and inter-rater reliability for ultrasound imaging of the rectus femoris muscle for determining muscle cross-sectional area and echogenicity as a marker of muscle mass and quality in critically ill patients, respectively. It also highlights that with standardised training, multidisciplinary team members with no prior ultrasound experience, such as dietitians, can accurately perform US image acquisition as a means to measure muscle mass and quality, which in turn may be incorporated into their nutritional

assessment and care plans. This has the potential to reduce muscle loss over time, thereby reducing patient morbidity and mortality, and ultimately may improve long-term patient functionality and health-related quality of life.

Supplemental data – Additional supporting information may be found online in the Supporting Information section at the end of the article.

Disclosure statement – No potential conflict of interest was reported by the authors.

Funding – This study was funded by the Fresenius Kabi Jump-Start Research (Grant number 2019).

ORCID

Lizl Veldsman  <https://orcid.org/0000-0002-1613-6071>

Guy Richards  <https://orcid.org/0000-0002-8893-3934>

Renée Blaauw  <https://orcid.org/0000-0001-7413-5918>

References

- Rodrigues CN, Ribeiro Henrique J, Ferreira Á, et al. Ultrasonography and other nutrition assessment methods to monitor the nutrition status of critically ill patients. *JPEN J Parenter Enteral Nutr.* 2021;45(5):982–90. <http://doi.org/10.1002/jpen.1966>
- Fazzini B, Märkl T, Costas C, et al. The rate and assessment of muscle wasting during critical illness: a systematic review and meta-analysis. *Crit Care.* 2023;27:2. <http://doi.org/10.1186/s13054-022-04253-0>
- Puthuchery ZA, Rawal J, McPhail M, et al. Acute skeletal muscle wasting in critical illness. *JAMA.* 2013;310(15):1591–600. <http://doi.org/10.1001/jama.2013.278481>
- Heyland DK, Stapleton RD, Mourtzakis M, et al. Combining nutrition and exercise to optimize survival and recovery from critical illness: conceptual and methodological issues. *Clin Nutr.* 2016;35(5):1196–206. <http://doi.org/10.1016/j.clnu.2015.07.003>
- Parry SM, Chapple LS, Mourtzakis M. Exploring the potential effectiveness of combining optimal nutrition With electrical stimulation to maintain muscle health in critical illness: A narrative review. *Nutr Clin Pract.* 2018;33:772–89. <http://doi.org/10.1002/ncp.10213>
- Hickmann CE, Castanares-Zapatero D, Deldicque L, et al. Impact of very early physical therapy during septic shock on skeletal muscle: A randomized controlled trial. *Crit Care Med.* 2018;46(9):1436–43. <http://doi.org/10.1097/CCM.0000000000003263>
- Bear DE, Wandrag L, Merriweather JL, et al. The role of nutritional support in the physical and functional recovery of critically ill patients: A narrative review. *Crit Care.* 2017;21:226. <http://doi.org/10.1186/s13054-017-1810-2>
- van Aerde N, Meersseman P, Debaveye Y, et al. Five-year outcome of respiratory muscle weakness at intensive care unit discharge: secondary analysis of a prospective cohort study. *Thorax.* 2021;76(6):561–7. <http://doi.org/10.1136/thoraxjnl-2020-216720>
- Meyer-Frießem CH, Malewicz NM, Rath S, et al. Incidence, time course and influence on quality of life of intensive care unit-acquired weakness symptoms in long-term intensive care survivors. *J Intensive Care Med.* 2021;36(11):1313–22. <http://doi.org/10.1177/0885066620949178>

10. Morton RW, Traylor DA, Weijs PJM, et al. Defining anabolic resistance: implications for delivery of clinical care nutrition. *Curr Opin in Crit Care.* 2018;24:124–30. <http://doi.org/10.1097/MCC.0000000000000488>
11. Sundström-Rehal M, Tardif N, Rooyackers O. Can exercise and nutrition stimulate muscle protein gain in the ICU patient? *Curr Opin Clin Nutr Metab Care.* 2019;22:146–51. <http://doi.org/10.1097/MCO.0000000000000548>
12. Formenti P, Umbrello M, Coppola S, et al. Clinical review: peripheral muscular ultrasound in the ICU. *Ann Intensive Care.* 2019;9:57. <http://doi.org/10.1186/s13613-019-0531-x>
13. Van Ruijven IM, Stapel SN, Molinger J, et al. Monitoring muscle mass using ultrasound: A key role in critical care. *Curr Opin Crit Care.* 2021;27:354–60. <http://doi.org/10.1097/MCC.0000000000000846>
14. Martín CAG, Zepeda EM, Méndez OLA. Bedside ultrasound measurement of rectus femoris: A tutorial for the nutrition support clinician. *J Nutr Metab.* 2017; 2767232.
15. Arai Y, Nakanishi N, Ono Y, et al. Ultrasound assessment of muscle mass has potential to identify patients with low muscularity at intensive care unit admission: A retrospective study. *Clin Nutr ESPEN.* 2021;45:177–83. <http://doi.org/10.1016/j.clnesp.2021.08.032>
16. Sabatino A, Regolisti G, Bozzoli L, et al. Reliability of bedside ultrasound for measurement of quadriceps muscle thickness in critically ill patients with acute kidney injury. *Clin Nutr.* 2017;36(6):1710–5. <http://doi.org/10.1016/j.clnu.2016.09.029>
17. Fetterplace K, Deane AM, Tierney A, et al. Targeted full energy and protein delivery in critically ill patients: A study protocol for a pilot randomised control trial (FEED trial). *Pilot Feasibility Stud.* 2018 Apr 25;4(1). <http://doi.org/10.1186/s40814-018-0249-9>
18. Patel JJ, Mundi MS, Taylor B, et al. Casting light on the necessary, expansive, and evolving role of the critical care dietitian: An essential member of the critical care team. *Crit Care Med.* Lippincott Williams and Wilkins. 2022;50:1289–95. <http://doi.org/10.1097/CCM.0000000000005607>
19. Mourtzakis M, Parry S, Connolly B, et al. Skeletal muscle ultrasound in critical care: A tool in need of translation. *Ann Am Thorac Soc.* American Thoracic Society. 2017;14:1495–503. <http://doi.org/10.1513/AnnalsATS.201612-967PS>
20. Sheean P, Gonzalez MC, Prado CM, et al. American society for parenteral and enteral nutrition clinical guidelines: The validity of body composition assessment in clinical populations. *JPEN J Parenter Enteral Nutr.* 2020;44(1):12–43. <http://doi.org/10.1002/jpen.1669>
21. Looijaard WGPM, Molinger J, Weijs PJM. Measuring and monitoring lean body mass in critical illness. *Curr Opin Crit Care.* 2018;24:241–7. <http://doi.org/10.1097/MCC.0000000000000511>
22. Nakanishi N, Tsutsumi R, Okayama Y, et al. Monitoring of muscle mass in critically ill patients: comparison of ultrasound and two bioelectrical impedance analysis devices. *J Intensive Care.* 2019;16;7(61):1–8. <https://doi.org/10.1186/s40560-019-0416-y>
23. Bury C, DeChicco R, Nowak D, et al. Use of bedside ultrasound to assess muscle changes in the critically ill surgical patient. *JPEN J Parenter Enteral Nutr.* 2021;45(2):394–402. <http://doi.org/10.1002/jpen.1840>
24. Cederholm T, Jensen GL, Correia MITD, et al. GLIM criteria for the diagnosis of malnutrition – A consensus report from the global clinical nutrition community. *Clin Nutr.* 2019;38(1):1–9. <http://doi.org/10.1016/j.clnu.2018.08.002>
25. Mundi MS, Patel JJ, Martindale R. Body composition technology: implications for the ICU. *Nutr Clin Pract.* 2019;34:48–58. <http://doi.org/10.1002/ncp.10230>
26. Weinel LM, Summers MJ, Chapple LA. Ultrasonography to measure quadriceps muscle in critically ill patients: A literature review of reported methodologies. *Anaesth Intensive Care.* 2019;47:423–34. <http://doi.org/10.1177/0310057X19875152>
27. Nakanishi N, Takashima T, Oto J. Muscle atrophy in critically ill patients: a review of its cause, evaluation, and prevention. *J. Med. Invest.* 2020; 67:1–10.
28. Van Ruijven IM, Stapel SN, Girbes ARJ, et al. Early high protein provision and mortality in ICU patients including those receiving continuous renal replacement therapy. *Eur J Clin Nutr.* 2022;76:1303–8. <http://doi.org/10.1038/s41430-022-01103-8>
29. Balmert N, Espinosa J, Arafeh MO, et al. Integration of bedside ultrasound into the ICU—a review of indications, techniques and interventions. *JECM Emerg Crit Care Med.* 2018;2:17. <http://doi.org/10.21037/jecm.2018.01.07>
30. Parry SM, El-Ansary D, Cartwright MS, et al. Ultrasonography in the intensive care setting can be used to detect changes in the quality and quantity of muscle and is related to muscle strength and function. *J Crit Care.* 2015;30(5):1151.e9–1151.e14. <http://doi.org/10.1016/j.jcrc.2015.05.024>
31. Tillquist M, Kutsogiannis DJ, Wischmeyer PE, et al. Bedside ultrasound is a practical and reliable measurement tool for assessing quadriceps muscle layer thickness. *JPEN J Parenter Enteral Nutr.* 2014;38(7):886–90. <http://doi.org/10.1177/0148607113501327>
32. Baston CM, Gellhorn AC, Hough CL, et al. Interrater reliability of quantitative ultrasound measures of muscle in critically ill patients. *Am Acad Phys Med Rehab.* 2022;14:183–9.

Received: 16-01-2024 Accepted: 30-05-2024