

Nutritional management of a complicated surgical patient by means of fistuloclysis

Du Toit A, BSc(Dietetics), Chief Dietitian, Groote Schuur Hospital, Cape Town
 Correspondence to: Anna du Toit, e-mail: anna-lena.dutoit@westerncape.gov.za
 Keywords: fistuloclysis, nutritional management, complicated surgical patient

Due to the complexity of the case, the format of patient information, followed by discussion at the appropriate point of the case study, has been adopted.

© Peer reviewed. (Submitted: 201300-00 Accepted: 2013-00-00) © SAJCN

S Afr J Clin Nutr 2014;27(4):230-236

Introduction

A fistula is defined as an abnormal communication between two organs, an organ and the skin, or an organ and a wound.¹ Up to 70% of patients with fistulae present with malnutrition.¹ Enteral nutrition (EN) has considerable advantages over parenteral nutrition (PN) support, including improved gut barrier function, a reduction in infectious morbidity and improved immune function.² EN support remains the preferred route of nutrition support in patients with fistulae, unless it causes a significant increase in fistula output, abdominal pain or exacerbates diarrhoea.¹ Fistuloclysis, i.e. enteral feeding via an intestinal fistula, is an effective means of providing nutritional support to these patients and can replace the need for PN support.³

Case study (days 0-65)

A 30-year-old male, with no significant past medical history, was admitted to hospital with multiple gunshot wounds to the abdomen.

On admission to hospital, he underwent a damage control laparotomy, where he was found to have complete transection at the duodenojejunal (DJ) flexure, a transverse colon perforation, a splenic laceration, a left kidney injury, multiple small bowel perforations and arterial bleeding. The DJ flexure and colonic injuries were repaired primarily, a left nephrectomy was performed, the arterial bleed ligated and packed, and the small bowel tied off. The patient was transferred to the intensive care unit (ICU) on ventilation and inotropic support, with an open abdomen. The patient's anthropometry on admission to the ICU was an estimated height and weight of 1.75 m and 75 kg, respectively, with a normal body mass index (BMI) of 24.5 kg/m². PN support was started on day 1 of ICU admission, according to The European Society for Clinical Nutrition and Metabolism guidelines on PN with respect to intensive care.⁴ The PN prescription provided 20 kCal/kg non-protein energy (NPE) with 1.7g/kg protein, which included 0.4 g/kg of intravenous (IV) glutamine.

Nine relook laparotomies were performed while the patient was in the ICU. A feeding jejunostomy was placed at the second relook in an attempt to obtain a secure enteral feeding route distal to the duodenal injury. The primary repair to the duodenum broke down and required re-repair, making successful gastric feeding at that point potentially impossible. The feeding jejunostomy was complicated by necrosis, and was eventually removed at the last re-look laparotomy. The patient had developed a frozen abdomen with fistulae, presumably from the initial duodenal injury and site of the feeding jejunostomy.

After 38 days in ICU, the patient was weighed on a bed scale. A weight of 64 kg was recorded, equating to a BMI of 21 kg/m², still within the normal range. He was discharged to the intestinal failure unit on day 65 post injury on PN, with an open abdomen with vacuum dressing, multiple enteroatmospheric fistulae (EAF) and a sacral bedsore.

Discussion with respect to the case study (days 0-65)

A fistula arising from the gut to any other part of the body is referred to as a gastrointestinal fistula, while that between the gut and the skin is an enterocutaneous fistula (ECF).¹ An EAF is a subset of an ECF that arises in the setting of an open abdomen with exposed viscera.^{5,6} An ECF can develop due to complications of injury, intra-abdominal surgery (75-85% of cases),¹ malignancy, inflammatory bowel disease, post-radiation therapy for malignancy or due to distal obstruction.⁵ Crohn's disease is a major contributor to spontaneous fistula development, and 40% of patients with this condition will develop a fistula in the course of their illness.¹ Patients with an open abdomen present a high risk for the development of fistulae, with an incidence of 5-19%.⁶

Over the past 30 years, with improvements in wound and skin care, the management of sepsis, and the provision of safe and effective nutritional support and appropriate timing of surgical intervention, the associated mortality of ECFs has been reduced from 65% to 10%.⁷ Mortality rates associated with EAF still remain around 10%.⁷

Table I: Subtypes of intestinal failure^{9,11}

Type	Description	Management
Type 1	Self-limiting, short term and often perioperative	Settles within 7-14 days with conservative management, nasogastric drainage and parenteral nutrition support
	Common causes include non-mechanical ileus (post surgery, intra-abdominal sepsis, spinal cord injury, head injury, extra-abdominal sepsis and multi-organ failure), and mechanical intestinal obstruction	
Type 2	High incidence of mortality	Early diagnosis and treatment of abdominal sepsis and adequate nutrition support, usually in the form of parenteral nutrition
	Usually not self-limiting	
	Often secondary to abdominal sepsis and intestinal fistulation	
Type 3	50% of patients with type 2 intestinal failure develop type 3 intestinal failure	Long-term parenteral nutrition support

Table II: Nutrition requirements

Descriptor	Energy	Protein	Micronutrients
Open abdomen ¹²	25-35 kCal/kg NPE	1.5-2.5 g/kg plus 29 g/l effluent	
Low-output gastrointestinal fistula ¹	25 kCal/kg TE	1-1.5 g/kg	
High-output gastrointestinal fistula ¹	At least 30 kCal/kg TE	1.5-2 g/kg plus 2 g/l effluent	2 x DRIs for vitamins and trace elements. Up to 5 x DRIs for vitamin C and zinc. At high risk of vitamin B ₁₂ , zinc, magnesium and selenium deficiency
Short bowel syndrome ^{13,14}	PN: 32 kCal/kg TE ¹³	PN: 1-1.5 g/kg ¹³	Typically requires doses higher than the DRI for healthy individuals. Depends on the remaining gastrointestinal anatomy, e.g. ileum resection with vitamin B ₁₂ malabsorption
	EN: Up to 60 kCal/kg TE ¹⁴	EN: 1.5-2 g/kg ¹⁴	

DRI: dietary reference intake, EN: enteral nutrition, NPE: non-protein energy, PN: parenteral nutrition, TE: total energy

An EAF requires surgery in order to close, while an ECF type of fistula with an intact abdominal wall has a spontaneous closure rate of 50-80%.⁷

Fistulae are classified according to output.⁶ Less than 200 ml effluent per day is considered to be low output, while 200-500 ml per day is classified as moderate output.⁶ An ECF effluent of more than 500 ml per day is considered a high-output fistula and is associated with high morbidity and mortality.^{1,6} Therefore, the treatment and management of patients with fistulae focuses on addressing sepsis, improving nutritional status, excluding distal obstruction and reducing fistulae output.⁷

Reducing fistulae output can be achieved by slowing the gastrointestinal transit with loperamide and codeine, optimising luminal absorption with isotonic feeding and reducing enteric secretions.⁷ Somatostatin is a naturally occurring peptide hormone, with an inhibitory effect on gastrointestinal secretions.⁷ However, it has a half-life of only 1-2 minutes, and therefore requires constant infusion in order to be effective.⁸ Synthetic somatostatin analogues have been developed with a longer half-life, making intermittent administration possible.⁹ Octreotide is one such analogue.⁹ Although similar to somatostatin, the receptor-binding properties are not the same, and their action might not be equivalent.⁸ It was found in a meta-analysis and systematic review published in 2012 that both somatostatin and octreotide increased the likelihood of spontaneous fistula closure, and were effective in reducing time to closure.⁸

However, closure of the fistulae tract largely depends on the anatomy of the fistulae tract, and not only the output.⁸ The review data did not show a mortality benefit.⁸ Somatostatin appeared to be superior to octreotide in improving outcome.⁸ Side-effects associated with the use of somatostatin and somatostatin analogues include nausea, abdominal cramps, loose stools, mild steatorrhoea and flatulence.⁸ These side-effects start within hours of the first dose and appear to be dose dependent, but usually subside spontaneously within the first few weeks of treatment.⁸ There is an increased risk of gallstones developing in patients treated with somatostatins.⁸ Octreotide is often recommended in the literature for use in the management of ECF patients, but the literature is not consistent and larger randomised control trails are needed.

Intestinal failure can be defined as a condition resulting from obstruction, dysmotility, surgical resection, congenital defect or disease-related loss of absorptive ability, and is characterised by the inability to maintain protein energy, fluid, electrolytes or micronutrient balance.^{9,10} Patients usually require supplementary PN and/or IV fluid to maintain nutrition and fluid status (Table I).¹¹

Case study (days 66-112)

This patient would have been classified as a type 2 intestinal failure while in the ICU because of his multiple fistulae and the long duration of his intestinal failure.

Table III: Nutrition delivery

Nutrition	Days 42-68 (PN)	Days 74-113 (PN)	Days 114-134 (EN)	Days 135-139 (EN and PN)	Days 140-170 (PN)	Days 171-184 (EN)	Days 225-246 (oral)
Volume (ml)	2 400	2 400	1 000	2 600	2 620	2 000	-
Total energy (kCal/kg)	36	41	22	50	44	38	84
Non-protein energy (kCal/kg)	27	31	16	40	33	31	68
Protein (g/kg)	2.2	2.6	1.4	2.6	2.7	1.7	4
Glutamine (g/kg)	0.3	0.4	0.58	0.45	0.5	-	-
Lipid (g/kg)	0.8	0.9	0.5	1.5	1	1.1	-
Carbohydrate	3.3 mg/kg/minute	3.8 mg/kg/minute	2.75 g/kg	6 g/kg	4 mg/kg/minute	5.5 g/kg	-
Na (mmol)	116.5	116.5	35	77.7	115.5	70	-
K (mmol)	52.5	52.5	51	91	60	102	-
Cl (mmol)	130.5	130.5	83	145.7	165.5	166	-
PO ₄	21.2	21.2	48	65.7	21.5	42.5	-
Water-soluble vitamins	2 x RDA	2 x RDA	At least 1 x RDA	At least 2 x RDA	2 x RDA	At least 1 x RDA	At least 1 x RDA
Fat-soluble vitamins	1 x RDA	1 x RDA	At least 1 x RDA	At least 1 x RDA	1 x RDA	At least 1 x RDA	At least 1 x RDA
Trace elements	2 x RDA	2 x RDA	At least 1 x RDA	At least 2 x RDA	2 x RDA	At least 1 x RDA	At least 1 x RDA

Cl: chloride, EN: enteral nutrition, K: potassium, Na: sodium, PN: parenteral nutrition, PO₄: phosphate, RDA: recommended dietary allowance, TE: total energy

Table IV: The patient's biochemistry

Days post admission	Normal value	Day 73	Day 80	Day 90	Day 112	Day 133	Day 154	Day 171	Day 182	Day 189	Day 245	Day 318
Urea (mmol/l)	2.6-7	3.3	2.1	6.5	5.1	2	6.2	8.4	7.9	6.9	3.6	4.6
Creatinine (µmol/l)	64-104	88	70	53	51	68	68	80	115	93	98	101
Total bilirubin (µmol/l)	0-21	7	12	9	3	3	3	8	5	4	9	9
Conjugated bilirubin (µmol/l)	0-6	3	6	3	2	< 1	< 1	-	2	2	3	2
Alkaline phosphatase (U/L)	40-120	96	149	173	91	83	250	444	175	141	99	83
-glutamyl transferase (U/L)	0-60	35	-	73	28	15	86	183	46	47	50	15
Alanine transaminase (U/L)	5-40	18	31	31	8	12	27	112	15	18	21	12
Aspartate transaminase (U/L)	5-40	8	26	28	8	16	29	113	14	13	13	15
Albumin (g/l)	35-52	17	20	21	17	14	14	29	27	29	37	39

His PN regimen was calculated to compensate for his fistula losses and open abdomen, using his last actual weight of 64 kg. Energy requirements were calculated with the aim of providing 25-35 kCal/kg NPE and 1.5-2.5 g/kg protein. Protein losses from the open abdomen were also taken into consideration.¹² Protein losses from an open abdomen are estimated to be approximately 29 g/l, while fistula losses contain approximately 2 g of protein per litre (Table II).¹² An average output of 730 ml/day was recorded from the open abdomen, inclusive of fistula losses. Protein losses from the open abdomen calculated at 29 g/l equated to 21 g of protein. Therefore, the PN regimen had to provide 96-160 g of protein (1.5-

2.5 g/kg), plus an additional 21 g/kg to compensate for the losses, i.e. 117-181 g protein/day. The patient received 140 g protein per day, which included 20 g of glutamine (Table III). The patient was kept *nil per os* and only received PN support.

The patient remained on this PN regimen until he developed a central line-associated blood stream infection (CLABSI) requiring removal of the central line on day 68. It is practice to remove the central line in our intestinal failure unit while the CLABSI is being treated, and to reinsert a central line for recommencement of PN once the patient has been afebrile for 48 hours. During this period, patients only receive IV fluids via a peripheral line to maintain hydration status

and oral intake, as tolerated. The patient's weight had deteriorated to 55 kg on day 68 of treatment.

On day 74 of treatment, six days later, his PN was restarted on the same regimen as before, and he was allowed to continue the full ward diet (providing approximately 1 800 kCal TE and 80 g protein), as tolerated. Patients with ECF should be allowed to eat orally if they wish to do so because of the psychological benefit that is derived from it.⁶ Oral intake should be abandoned if the fistula output increases to unmanageable levels in terms of volume and electrolyte abnormalities.⁶ His appetite was poor and he had ongoing episodes of vomiting.

The biochemistry, repeated on days 80 and 90, showed ongoing deranged liver function tests and hypoalbuminaemia (Table IV). The deranged liver enzymes were thought to be owing to prolonged PN support, as well as ongoing sepsis.¹⁵ His PN regimen included a fish oil-containing lipid emulsion. Lipids were restricted to < 1 g/kg and he was started on cyclic PN over 18 hours. His oral intake was encouraged in an attempt to optimise the enteral route, in order to improve his deteriorating liver function tests (Table IV).¹⁵

The patient underwent a fistulogram on day 93 in order to delineate the anatomy of the gastrointestinal tract. The fistulogram showed approximately 60 cm of small bowel distal to the most distal fistula with colon in situ and no distal defects or obstructions. At this stage, he had an average fistula output of 800 ml/day and vomited 400 ml/day on average. He had a gastroscopy to rule out a gastric outlet obstruction as the cause of the ongoing vomiting, but a mechanical or functional cause was not found. On day 95 post injury, the distal fistula was canulated and the patient was started on fistuloclysis. PN support continued on the same regimen, with negligible oral intake (< 150 kCal taken by mouth).

The fistula effluent re-infusion was started at 21 ml/hour via the fistuloclysis catheter, and increased daily until all of the effluent was being re-infused. By re-infusing the fistula output, the losses via a fistula are eliminated and there is no need to compensate for them. The length of the bowel available for absorption and enteral intake need to be taken into consideration when calculating energy requirements and the need for ongoing PN support. Seventeen days after starting fistuloclysis, day 112 post injury, the liver enzymes normalised. Despite ongoing PN support, his albumin remained low at 17 g/l (Table IV).

Discussion with respect to the case study (days 66-112)

The process of a fistulogram refers to the injection of contrast into the most distal fistula through a thin catheter. X-rays of the abdomen are then taken to assess the flow of contrast and exclude any distal

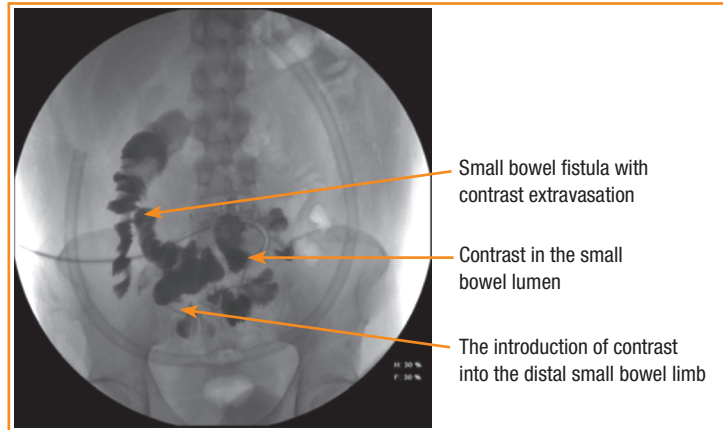


Figure 1: Fistulogram demonstrating the free flow of contrast distal to the fistula or stoma to exclude distal obstruction or fistulae prior to commencing fistuloclysis

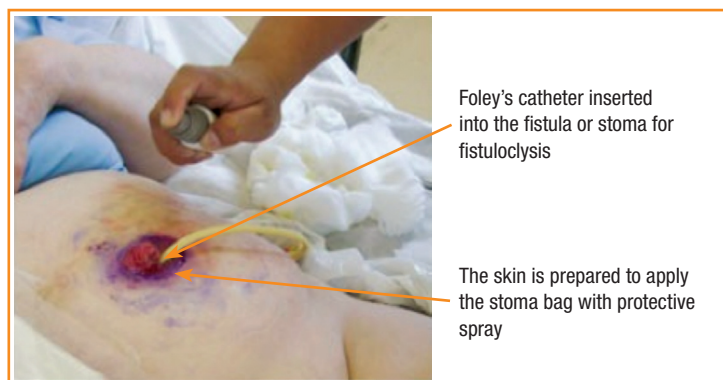


Figure 2: The insertion of a Foley's catheter and preparation of the skin

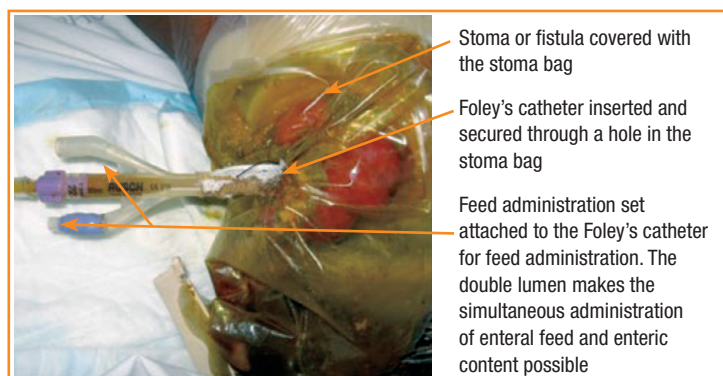


Figure 3: The insertion of a Foley's catheter and the accompanying preparations

obstruction or fistulae, and to determine the location of the fistula and the length of the distal bowel (Figure 1). If a patient is deemed to be a suitable candidate for fistuloclysis, a catheter is inserted into the fistula (Figures 2 and 3).

The skin is sprayed to protect it against the stoma or fistula effluent. A Foley's catheter is inserted into the stoma or fistula, and advanced down the distal limb for fistuloclysis

The stoma or fistula is covered with a suitable stoma bag and the Foley's catheter inserted and secured through a hole in the bag. A feed administration set is connected to the catheter. The double lumen catheter makes simultaneous administration of the enteral feed and enteric content possible.

Fistuloclysis refers to enteral feeding via an intestinal fistula, and is an effective means of providing nutritional support.¹⁶ Suitable patients for this approach include those with a distal fistula opening that can be intubated with a balloon-retained gastrostomy tube, no evidence of distal intestinal obstruction and at least 75 cm of small bowel distal to the fistula.⁵

Fistuloclysis successfully replaced PN in 11 of 12 patients in a series described by Teubner et al, and increased body weight and serum albumin, as well as decreasing hospital length of stay.³ Complications were not associated with fistuloclysis, and the method was considerably more cost-effective.³ The nutritional status was maintained for a median of 155 days (a range of 19-422) until definitive reconstructive surgery could be undertaken in nine of the 11 patients.³ Two patients who did not undergo surgery were maintained on fistuloclysis for nine months.³ One patient died at home due to ischaemic heart disease, while the second could not undergo reconstructive surgery because of medical co-morbidities.³

Wu et al found that fistuloclysis could successfully improve liver function and overall nutritional status in patients with high-output enteric fistulae.² Ninety-five patients met the entry criteria in this study² and were enrolled. They were divided into a control group who received EN only, and a fistuloclysis group who received EN and fistuloclysis. Patients in the fistuloclysis group were further divided into three subgroups with regard to the location of the fistula: group 1, patients with jejuna-ileal fistulae; group 2, patients with biliary fistulae and group 3, patients with duodenal fistulae. EN was administered into the distal fistula or nasojejunally in the case of biliary fistulae. The feeding goal was at least 30 kCal/kg/day and 1.5-2 g/kg protein/day, with an additional 2 g of nitrogen for every litre of fistula output. Both groups showed a statistically significant decline in hepatic indexes from baseline to 28 days. Similarly, there was an increasing trend with regard to the nutritional parameters in both groups. The fistuloclysis group showed a statistically significant increase in albumin levels. The fistuloclysis group also demonstrated a significant reduction in fistula output. With respect to differences between the groups receiving fistuloclysis, the biggest improvement in total and direct and indirect bilirubin and alkaline phosphatase was seen in group 2, i.e. in patients with biliary fistulae. The greatest improvement in alanine transaminase and total protein was also seen in patients in group 2. Patients in group 1, i.e. patients with jejunal-ileal fistulae, showed the least improvement with respect to these parameters. In terms of one-year survival, one patient (2.9%) in the fistuloclysis group died, while 10 patients (16.7%) in the control group died at one year follow-up. In terms of survival time, the fistuloclysis plus EN group was significantly (*p*-value 0.045) superior when compared to the group of patients who received EN only.

Fistuloclysis, as a method of nutrition support, has several advantages.² Benefits seen might be because of the improvement in liver function and nutritional status, together with a reduction in fistula output.² Up to 70% of patients with fistulae have malnutrition.¹ EN support is the preferred route of nutrition support, unless it

increases fistula output dramatically, causes increased abdominal pain or exacerbates diarrhoea.¹ Fistuloclysis could eliminate some of the limitations associated with enteral feeding.

Fistuloclysis also has a better positive impact on liver function tests than EN alone.² This may, in part, be attributable to cholecystokinin (CCK) which is produced by the endocrine cells in the duodenum and upper jejunum.² CCK stimulates gallbladder contractility and bile secretion.² CCK is secreted in response to fat, protein and amino acid in the duodenum.² Trypsin-sensitive monitor peptide in the upper intestinal lumen is another potent CCK-releasing factor, but it might be lost through fistula output.² Therefore, supporting the digestive system through fistuloclysis might improve CCK secretion, and thereby enhance cholestasis.²

Additionally, fistuloclysis provides salivary amylase, gastric pepsin and pancreatic enzymes, as well as bile acid which is necessary for optimal EN utilisation.² The fistula effluent also has the perfect pH to activate proenzymes and appropriate enzyme components for optimal EN absorption.² Bile acid in the intact gut is secreted in the duodenum, absorbed in the terminal ileum and recycled to the liver.² This cycle is interrupted in the patient with a fistula, leading to a lack of bile acid and the subsequent malabsorption of fatty acid, phospholipids and fat-soluble vitamins.² The enterohepatic circulation of bile acid can be restored with fistuloclysis, and improvements in nutritional status achieved.²

High output from enteric fistulae is associated with high fluid and electrolyte losses, resulting in hyponatraemia, hypochloreaemia, hypokalaemia, metabolic acidosis or alkalosis and renal dysfunction.² Fistuloclysis has the ability to decrease fistula output, probably through an inhibitory effect on upper gastrointestinal secretions.² It is speculated that this might be attributable to the restoration of bowel continuity and physiological digestive processes.²

Case study (days 113-157)

The patient developed another episode of CLABSI, and the central line was removed again on day 113 of treatment. His oral intake remained poor, and in an attempt to meet the requirements enterally, and to avoid the need for ongoing PN, he was started on a semi-elemental enteral feed via the fistuloclysis catheter. He also started on enteral glutamine at 0.6 g/kg oral administration. The prescribed amount of feed was 2 300 kCal TE (45 kCal/kg actual bodyweight) and 112 g (2.2 g/kg actual bodyweight) protein. On average, the patient only received 1 000 kCal total energy and 44 g of protein, less than 50% of the prescribed daily calories and protein. The semi-elemental feed was high in medium-chain triglycerides to optimise the energy absorptive capacity of the colon in view of the very short distal small bowel remnant available for feeding.¹⁴ The patient's oral intake from the ward diet and supplements remained negligible (< 150 kCal taken by mouth). He continued to receive the recommended dietary allowance for fat-soluble and water-soluble vitamins and trace elements intravenously.

The patient passed 3-5 loose stools per day, and tested negative for *Clostridium difficile* on day 118. He maintained his weight at 52 kg, but his albumin deteriorated to 14 g/l. His liver function tests normalised off PN support (Table IV). After 20 days of fistuloclysis and semi-elemental feeds via the distal limb, day 133 in total, the patient was restarted on supplemental PN, while continuing fistuloclysis and additional semi-elemental enteral feeds, as previously defined.

He had a repeat computed tomography scan on day 140, and was found to have only 10 cm of small bowel distal to the most distal fistula. Fistuloclysis and the additional feeds were stopped, and the patient was restarted on full PN support (Table III). During this period of fistuloclysis (53 days), he had an average fistula output of 1 000 ml per day, of which 75% was re-infused via fistuloclysis. The PN regimen contained a 100% soybean lipid emulsion and his liver enzymes deteriorated significantly (Table IV). His albumin remained low and his weight remained stable at 52 kg.

On day 157 post injury, he went to theatre for surgery. Intraoperatively, there were very dense adhesions, with a fistula 80 cm distal to the DJ flexure and a chronic abscess cavity. There was 40 cm of small bowel with multiple iatrogenic enterotomies secondary to mobilisation of the segment distal to the proximal fistula. A decision was made to resect the 40 cm segment. An iatrogenic serosal injury to the second part of the duodenum was primarily repaired. The two ends were brought out as a double-barrel stoma, and enterotomies distal to the stoma were also repaired primarily. Post surgery, the patient's gastrointestinal anatomy was 80 cm of small bowel proximally and 40 cm of small bowel distally to a double-barrel stoma, with the ileocaecal valve and the colon in situ. Skin closure was achieved, but the abdominal wall was left open. A new tunnelled central line was placed. Owing to the short remnant of small intestine, 120 cm in total, the patient was classified as a short bowel syndrome (SBS) patient.

Discussion with respect to the case study (days 113-157)

SBS refers to a condition in which patients present with malabsorption-related diarrhoea, dehydration, electrolyte disturbances and malnutrition secondary to poor digestive and absorptive capacity, as a result of a reduced functional intestinal area.^{11,17} SBS is often a result of surgical resection, but can also be caused by other conditions that influence absorptive capacity in the absence of surgical resection, including radiation enteritis, chronic intestinal pseudo-obstruction and congenital villus atrophy.¹⁷ Intestinal failure due to SBS is mostly due to massive intestinal loss as a result of surgery, trauma or infarction. Less commonly, it is associated with congenital defect or loss of absorptive surface as a result of disease.⁹

Normal lengths of small bowel differ significantly, from 300-850 cm.⁹ Evidence suggests that patients with less than 200 cm of small bowel are likely to develop intestinal failure, a number that is of little significance in practice.⁹ Although the length of remaining bowel correlates with a patient's degree of nutritional autonomy,

the location of the resection and condition of the remaining bowel also play a role.^{9,14} SBS accounts for nearly 80% of long-term PN patients^{18,19} since all SBS patients require PN support in the immediate postoperative phase to maintain nutritional status.²⁰ Some patients can be weaned off PN, while others might require long-term PN support.²⁰

Case study (days 158-190)

The patient continued PN postoperatively and had very poor oral intake. On day 14 post surgery, day 171 of treatment in total, he developed another episode of CLABSI and the central line was removed and PN stopped. On biochemistry review, his liver enzymes remained increased, but albumin had improved to 29 g/l (Table IV).

A nasogastric tube was placed and the patient was started on a semi-elemental enteral feed, the distal stoma was canulated and the patient restarted fistuloclysis. He was weaned onto a standard polymeric feed within five days and oral intake was encouraged (Table III). Twenty-five days post surgery, day 182 in total, his weight improved to 53 kg and his albumin was 27 g/l. The liver function tests improved (Table IV).

He was discharged home 33 days post surgery, day 190 of treatment in total, on oral supplements and fistuloclysis. He required two readmissions for dehydration in the month following discharge. During this time, he maintained his weight and his albumin improved to 38 g/l. At his second readmission, he remained in hospital awaiting definitive surgery. He coped well with oral intake and twice took the full ward diet and additional oral supplements, providing 84 kCal/kg TE and 4 g/kg protein, while he continued fistuloclysis.

Discussion with respect to the case study (days 158-190)

Patients with a very short remnant bowel and patients absorbing less than a third of their intake typically require long-term PN support, while others might be able to maintain nutritional status through hyperphagia.²⁰ Hyperphagia is defined as a >1.5-fold increase in calories over resting energy expenditure.²⁰

Woolf et al found that SBS patients absorbed approximately 62% of delivered energy. The absorption of fat, carbohydrate and protein was 54%, 61% and 81%, respectively.¹⁴ Calorie provision, of up to 60 kCal/kg bodyweight/day via the enteral route might be necessary to maintain body weight with a protein intake of 1.5-2 g/kg.¹⁴ If the colon is intact, the delivery of large amounts of carbohydrate can improve the energy balance through short-chain fatty acid production in the colon.^{13,14}

Case study (days 191-396)

The patient underwent definitive surgery 247 days post his initial injury. His weight was stable at 53 kg and his albumin had improved to 37 g/l. The liver function tests were all normal. His postoperative gastrointestinal anatomy was 120 cm of small bowel, with ileocaecal valve and colon in situ. He was discharged on day five postoperatively

on an oral intake with oral supplementation. Oral supplementation was provided in the form of three servings of a polymeric powdered supplement, providing 690 kCal TE and 30 g protein.

He had been on fistuloclysis for 128 days in total, and was managed as an outpatient for 28 days during his total hospital stay of 252 days. He had an average stoma or fistula output of 1 400 ml per day, on average of which 60% was re-infused via fistuloclysis. During the total period of fistuloclysis, he had seven documented incidences of fistuloclysis catheter-related complications, limited to tube dislodgement or blockage of the catheter in this patient. Other possible catheter-related complications included skin corrosion from effluent leaking onto the skin, as well as a very rare complication of a “swallowed” feeding tube, in which the feeding tube was ingested into the intestine by peristalsis.² It is unknown if feeding tubes delay the spontaneous healing of fistulae.²

At follow-up five months post discharge (day 396 post injury), the patient’s weight improved to 67 kg. By then, he had regained nutritional autonomy. At the time of writing this, he was awaiting surgical repair of a large ventral hernia secondary to his open abdomen.

Conclusion

The nutritional management of patients with grade 2 and grade 3 intestinal failure remains a challenge. Nutritional intervention and successful nutritional rehabilitation are often limited by the ability to provide long-term PN support. Owing to line sepsis, limited vascular access, PN-associated liver disease and cost, PN is not always a sustainable solution. Fistuloclysis has been demonstrated to be safe and effective in this group of patients, and should be considered an alternative way of providing adequate nutrition support to suitable patients.

References

1. Tong CY, Lim LL, Brody RA. High output enterocutaneous fistula: a literature review and a case study. *Asia Pac J Clin Nutr.* 2012;21(3):464-469.

2. Wu Y, Ren J, Wang G, et al. Fistuloclysis improves liver function and nutritional status in patients with high-output upper enteric fistula. *Gastroenterol Res Pract.* 2014;2014:941514.
3. Teubner A, Morrison K, Ravishankar HR, et al. Fistuloclysis can successfully replace parenteral feeding in the nutritional support of patients with enterocutaneous fistula. *Br J Surg.* 2004;91(5):625-631.
4. Singer P, Berger MM, Van den Berghe G, et al. ESPEN guidelines on parenteral nutrition: intensive care. *Clin Nutr.* 2009;28(4):387-400.
5. Dubose JJ, Lundy JB. Enterocutaneous fistulas in the setting of trauma and critical illness. *Clin Colon Rectal Surg.* 2010;23(3):182-189.
6. Majercik S, Kinikini M, White T. Enterocutaneous fistula: from soup to nuts. *Nutr Clin Pract.* 2012;27(4):507-512.
7. Stevens P, Burden S, Delicata R, et al. Somatostatin analogues for treatment of enterocutaneous fistula. [Cochrane review]. In: *The Cochrane Library, Issue 11; 2013.*
8. Rahbour G, Siddiqui MR, Ullah MR, et al. A meta-analysis of outcomes following use of somatostatin and its analogues for the management of enterocutaneous fistulas. *Ann Surg.* 2012;256(6):946-954.
9. O’Keefe SJ, Buchman AL, Fishbein TM, et al. Short bowel syndrome and intestinal failure: consensus definitions and overview. *Clin Gastroenterol Hepatol.* 2006;4(1):6-10.
10. Saunders J, et al. The financial cost of managing patients with type 2 intestinal failure: experience from a regional centre. *e-SPEN Journal.* 2013;8(3): e80-e85.
11. Tappenden KA. Pathophysiology of short bowel syndrome: considerations of resected and residual anatomy. *JPEN J Parenter Enteral Nutr.* 2014;38(1 Suppl):14S-22S.
12. Friese RS. The open abdomen: definitions, management principles, and nutrition support considerations. *Nutr Clin Pract.* 2012;27(4):492-498.
13. Matarese LE. Nutrition and fluid optimization for patients with short bowel syndrome. *JPEN J Parenter Enteral Nutr.* 2013;37(2):161-170.
14. Lochs H, Dejong C, Hammarqvist F, et al. ESPEN guidelines on enteral nutrition: gastroenterology. *Clin Nutr.* 2006;25(2):260-274.
15. Abu-Wasel B, Molinari M. Liver disease secondary to intestinal failure. *Biomed Res Int.* 2014;2014:968357.
16. Curtis K, Judson K. Management of fistulae in patients with open abdomen. *Nurs Stand.* 2014;28(25):56-58, 60-44.
17. Storch KJ. Overview of short bowel syndrome: clinical features, pathophysiology, impact and management. *JPEN J Parenter Enteral Nutr.* 2014;38(1 Suppl):5S-7S.
18. Venecourt-Jackson E, Hill SJ, Walmsley RS. Successful treatment of parenteral nutrition-associated liver disease in an adult by use of a fish oil-based lipid source. *Nutrition.* 2013;29(1):356-358.
19. Gardiner, Keith R. Management of acute intestinal failure. *Proc Nutr Soc.* 2011;70(3):321-328.
20. Jeppesen PB. Spectrum of short bowel syndrome in adults: intestinal insufficiency to intestinal failure. *JPEN J Parenter Enteral Nutr.* 2014;38(1 Suppl):8S-13S.