

# Hydatid lung cyst in a 5-year-old boy presenting with prolonged fever

Hakim Irfan Showkat, *postgraduate scholar in Internal Medicine*

Arif Hussain Sarmast, *postgraduate scholar in Surgery*

Abid Amin, *senior resident in Paediatrics, SKIMS Medical College*

Sohail Farooq Mir, *postgraduate scholar in Surgery*

Suman Kotwal, *senior resident in Internal Medicine*

Fazl Q Parray, *additional professor, General Surgery*

Rubina Lone, *assistant professor, Microbiology, SKIMS Medical College*

Faheem Arshad, *postgraduate scholar in Internal Medicine*

Iftikhar Bakhshi, *senior resident in Surgery*

*Sheri-Kashmir Institute of Medical Sciences (SKIMS), Srinagar, India*

*Corresponding author: HI Showkat (docirfanshabhi512@gmail.com, +91-9419028326)*

Cystic echinococcosis is the larval cystic stage (echinococcal cysts) of a small taeniid-type tapeworm (*Echinococcus granulosus*) that may cause illness in intermediate hosts, generally herbivorous animals and people who are infected accidentally. Pulmonary hydatid cysts are typical, involving one lobe in 72% of cases, usually at the lung base. In the paediatric age group, boys are affected more commonly than girls. We present a case of isolated hydatid cyst of the lung in a 5-year-old boy from a nomadic cattle-rearing tribe.

Hydatid disease is prevalent and widespread in sheep- and cattle-raising countries throughout the world. Our institute (the Sheri-Kashmir Institute of Medical Sciences (SKIMS), a tertiary care hospital in central Kashmir) sees about 150 - 200 cases of various forms of hydatid disease a year. The lungs are the most common site of involvement in children and the second most common in adults.<sup>1</sup> Intact cysts are usually asymptomatic and found as a chance occurrence on chest radiographs. Occasionally rupture of the cyst may be the first manifestation of the disease, and this can have catastrophic allergic sequelae.<sup>2,3</sup>

## Case report

A 5-year-old boy from a remote rural area in Kashmir, North India, where the Gujjar and Bakarwallah tribes keep cattle and dogs, presented with complaints of fever and cough for 1 month. He was initially managed at a primary health centre in northern Kashmir, where he was thought to have a respiratory tract infection. After 23 days of treatment, including cefixime 100 mg twice a day for 10 days and levofloxacin for 7 days, he was referred to SKIMS because of persistent symptoms.

On examination at our institution he was pale and had a temperature of 38.3°C. There was no cyanosis, clubbing or lymphadenopathy. Chest examination revealed decreased chest expansion and air entry on the right side of the chest. The haemoglobin concentration was 9.7 g/dl and the white cell count  $14.3 \times 10^9/l$ , with 82% neutrophils, 13% lymphocytes and 4% eosinophils. A chest radiograph showed a cystic lesion (Figs 1 and 2) with an air/fluid level. A provisional diagnosis of lung abscess was made. Intravenous antibiotics (ceftriaxone, sulbactam, amikacin, metronidazole) and antipyretics were commenced, and serological testing for hydatid disease was requested because the child came from a rural area and had close contact with livestock and dogs. The hydatid serological test was positive (titre 1:320). A

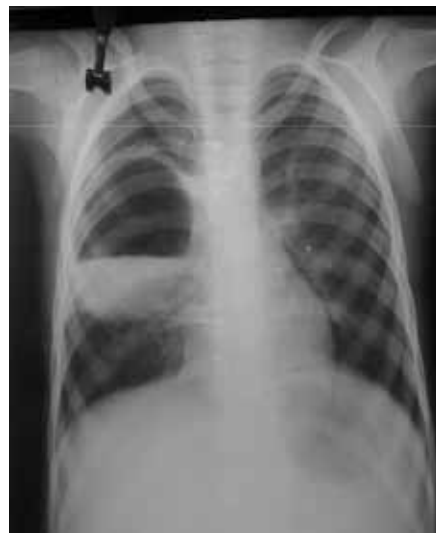
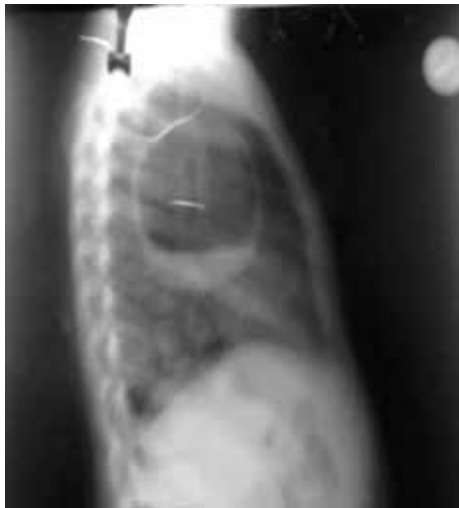
Fig. 1. Plain chest radiograph, postero-anterior view.

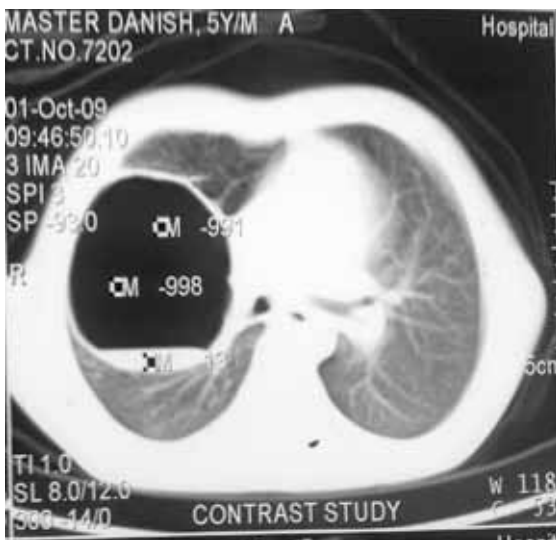
computed tomography (CT) scan of the chest confirmed the presence of a solitary hydatid cyst (Fig. 3). Definitive therapy consisting of oral albendazole and surgical management was instituted. Surgery was done at SKIMS and involved enucleation of the cyst with capitonnage of the cavity. The patient was discharged on the 10th postoperative day on albendazole. He was followed up for about 6 months and is doing well and attending school without any problems.

## Discussion

Hydatid disease represents the larval form of the canine intestinal tapeworm *Echinococcus granulosus*,<sup>4</sup> which infects humans as accidental intermediate hosts. The adult phase of *E.*



**Fig. 2. Chest radiograph, lateral view.**



**Fig. 3. Contrast-enhanced computed tomography of the chest.**

*granulosus* occurs in dogs and other carnivores. The head consists of a double crown of hook-like structures, and the body is formed of three or four rings, the last of which bears the eggs. After being shed in faeces, the eggs contaminate fields, irrigated land and wells. Herbivores such as sheep ingest the eggs, which develop into larvae, or hydatids, in the viscera. The cycle is completed with ingestion of the infected viscera by carnivores.

In accidental cases humans become aberrant intermediate hosts, contracting the disease from water or food or by direct contact with dogs. Once the eggs reach the stomach, the hexacanth embryos are released. These pass through the intestinal wall and reach the tributary veins of the liver, where they undergo vesicular transformation and

develop into hydatids. If they overcome the hepatic obstacle, they may become lodged in the lung, where they also transform into hydatids. If they advance beyond the lung, they may remain in any organ to which they are carried by the bloodstream. It has been shown that the embryos can reach the lung via the lymphatic vessels, bypassing the liver, and there is also evidence that the disease can be contracted through the bronchi.<sup>5</sup> Structurally the cysts consist of a tough outer pericyst that protects a delicate inner endocyst from which brood capsules and daughter cysts develop.

Humans may also acquire *E. multilocularis* infection by egg ingestion. Although a rare disease in humans, alveolar echinococcosis is of considerable public health importance because it can be lethal in up to 100% of untreated patients.<sup>6</sup>

Most intact cysts are asymptomatic and found incidentally on chest radiographs, but involvement of the lungs can produce chronic cough, dyspnoea, pleuritic chest pain and haemoptysis. Expectoration of cyst membranes and fluid is observed with intrabronchial rupture.<sup>7</sup> Cough, chest pain and breathlessness are the most common presenting symptoms, while haemoptysis is rare.<sup>8</sup> The mechanism of haemoptysis in pulmonary hyatid disease may be pressure erosion of a bronchus or bronchial infection resulting from obstruction. Further erosion into a branch arterial supply then causes haemoptysis. Hydatid cysts may erode into the great vessels, e.g. the aorta, causing massive haemoptysis.<sup>9</sup>

More common causes of paediatric haemoptysis include infection, foreign body aspiration, tracheostomy-related problems, congenital heart disease, cystic fibrosis, pulmonary haemosiderosis, trauma and fictitious haemoptysis.<sup>10</sup> A rare case of hydatid cyst of the lung associated with digital clubbing has been described.<sup>11</sup>

A variety of signs denoting different appearances of the hydatid cysts have been described on chest radiographs and CT scans. In uncomplicated hydatid cysts, radiological diagnosis is relatively easy. CT provides further information in equivocal cases by revealing the fluid density of an intact cyst and the air/fluid density of a ruptured cyst. Simple hydatid cysts have water density on CT and ruptured cysts may present with a wide variety of radiological appearances due to different combinations of collapsed membrane, air and fluid. However, infection of the cyst may increase the attenuation values and produce a solid appearance, which may hamper the correct diagnosis. Such complicated cysts, in the absence of positive history, serological tests and other radiological signs, may simulate a malignant tumour, tuberculosis, abscess or other infected cystic lesions of the lung. The 'air bubble sign' has been described in complicated cysts and reported to be an important clue in the differentiation of hydatid cysts from other disease processes.<sup>4,12,13</sup> Radiological signs occurring as a result of separation of cyst membranes have been described, and include the 'crescent', 'water-lily', 'daughter cysts', 'double arch', 'ring within a ring', 'serpent' or 'snake', and 'spin' or 'whirl' signs.<sup>4,13,14</sup>

Laboratory testing should be used either in highly suspicious cases or for postoperative follow-up of pulmonary hydatid cyst disease. Serological tests are often helpful, but measurable immunological responses do not develop in some patients. Both qualitative (immunoelectrophoresis) and quantitative enzyme-linked immunosorbent assay (ELISA) tests are available for hydatid disease. The most sensitive technique in detecting pulmonary hydatid disease is immunoglobulin G ELISA, with a sensitivity of 85.3%. Antibody production is elevated during the first 4 - 6 weeks after surgical intervention, followed by a decrease during the next 12 - 18 months. In patients who have a recurrence before 2 years, antibody production remains similar to pre-operative levels.<sup>15,16</sup>

The main treatment of a ruptured pulmonary hydatid cyst is surgery. Operative morbidity is higher in complicated pulmonary hydatid

**The goal of surgical therapy in pulmonary hydatid disease is to remove the cyst while preserving as much lung tissue as possible.**



cysts than intact ones. The most frequent postoperative sequelae of complicated pulmonary hydatid cysts are prolonged air leakage (15.2%), empyema (9.1%) and atelectasis (9.1%). The complication rate is much lower in patients with intact pulmonary hydatid cysts.<sup>17</sup>

Medical treatment of pulmonary hydatid cysts with albendazole or mebendazole is used together with surgical treatment to avoid recurrence. It is given pre-operatively to prevent the consequences of possible rupture of the cysts during surgery, and postoperatively as adjuvant therapy for cysts that may have ruptured during the operation.<sup>18</sup> The usual dosage of orally administered albendazole is 10 - 15 mg/kg/d in 2 divided doses, or a fixed dose of 400 mg twice a day. For mebendazole the daily dosage is 40 - 50 mg/kg in 3 divided doses.<sup>19</sup>

The goal of surgical therapy in pulmonary hydatid disease is to remove the cyst while preserving as much lung tissue as possible. The surgical method may be different in intact (simple) and ruptured (complicated) cysts. The operation has two steps: (i) removal of the germinative layer; and (ii) management of the residual pulmonary cavity. Simple cysts are generally removed after needle aspiration or enucleation without needle aspiration. Enucleation cannot be performed in ruptured cysts. The lung cavity that remains after removal of the cyst may be left or obliterated by sutures from within the cavity, depending on the size and location of the cyst. However, the bronchial openings in the cavity must be closed by sutures in all cases. Rarely, hydatid cysts can occur in other thoracic structures such as pulmonary artery, chest wall or diaphragm.<sup>20</sup>

Compared with surgical intervention for cystic hepatic echinococcosis, PAIR (puncture, aspiration, injection of scoleicidal agents and re-aspiration) plus albendazole or mebendazole has been reported to be associated with greater clinical and parasitological efficacy, less major and minor morbidity, lower rates of mortality and disease recurrence, and a shorter duration of hospitalisation.<sup>21</sup>

In addition to current (and past) hydatid control campaigns, there have been significant technological improvements in the diagnosis and treatment of human and animal cystic echinococcosis, the diagnosis of canine echinococcosis, and the genetic characterisation of strains and vaccination against *E. granulosus* in animals. Incorporation of these new measures could increase the efficiency of hydatid control programmes, potentially reducing the time required to achieve effective prevention of disease transmission to as little as 5 - 10 years.<sup>22</sup>

## References

- Beggs I. The radiology of hydatid disease. *AJR Am J Roentgenol* 1985;145:639-648.
- Saksouk FA, Fahl MH, Rizk GK. Computed tomography of pulmonary hydatid disease. *J Comput Assist Tomogr* 1986;10:226-232.
- Aggarwal S, Kumar A, Mukhopadhyay S, Berry M. A new radiologic sign of ruptured pulmonary hydatid cyst. *AJR Am J Roentgenol* 1989;152:431-432.
- VonSinner WN, Rifai A, Strake LT, Sieck J. Magnetic resonance imaging of thoracic hydatid disease. Correlation with clinical findings, radiography, ultrasonography, CT and pathology. *Acta Radiol* 1990;31:59-62.
- Burgos R, Varela A, Castedo E, et al. Pulmonary hydatidosis: surgical treatment and follow-up of 240 cases. *Eur J Cardiothorac Surg* 1999;16:628-635.
- Deplazes P, Eckert J. Veterinary aspects of alveolar echinococcosis – a zoonosis of public health significance. *Vet Parasitol* 2001;98:65-87.
- Dandan IS, Soweid AM, Abiad, F, et al. Hydatid cysts. *eMedicine*. <http://emedicine.medscape.com/article/178648-overview> (accessed 23 May 2011).
- Sahul B, Bhavneet B. Hydatid disease of lungs – unusual cause of hemoptysis. *Indian Pediatrics* 2002;39:1062-1063.
- Harris DG, Van Vuuren WM, Augustyn J, Rossouw GJ. Hydatid cyst fistula into the aorta presenting with massive hemoptysis: case report and literature review. *J Cardiovasc Surg (Torino)* 2001;42:565-567.
- Batra PS, Holinger LD. Etiology and management of pediatric hemoptysis. *Ann Otolaryngol Head Neck Surg* 2001;127:377-382.
- Bashour FA. Hydatid cyst of lung with clubbing. *Ann Intern Med* 1961;54(2):326-331.
- Köktürk O, Öztürk C, Diren B, Ünsal M, Ayla K. 'Air bubble': a new diagnostic CT sign of perforated pulmonary hydatid cyst. *Eur Radiol* 1998;9:1321-1323.
- Kervancıoğlu R, Bayram M, Elbeyli L. CT findings in pulmonary hydatid disease. *Acta Radiol* 1999;40:510-514.
- Gouliamos A, Kalovidouris A, Papailiou J, Vlahos L, Papavasiliou C. CT appearance of pulmonary hydatid disease. *Chest* 1991;100:1578-1581.
- Zarzosa MP, Orduña Domingo A, Gutiérrez P, et al. Evaluation of six serological tests in diagnosis and postoperative control of pulmonary hydatid disease patients. *Diagn Microbiol Infect Dis* 1999;35:255-262.
- Bustamante AJ, García San José I, Quinzanos ER, Tasis A. Hidatidosis (equinococcosis): micosis y parasitosis pulmonares II. *Patología Aparato Respiratorio* 1993;122:13.
- Kuzucu A, Soysal O, Özgel M, Yologlu S. Complicated hydatid cysts of the lung: clinical and therapeutic issues. *Ann Thorac Surg* 2004;77:1200-1204.
- Keshmiri M, Baharvahdat H, Fattahi SH, et al. A placebo controlled study of albendazole in the treatment of pulmonary echinococcosis. *Eur Respir J* 1999;14:503-507.
- Smith AL, Rego LP, Williams R. Albendazole monitoring. *Am J Health Syst Pharm* 1997;54:319-320.
- Halezerglu S. *Multimedia Manual Cardiothoracic Surgery*. European Association for Cardiothoracic Surgery, 2004;10.1510:1-7.
- Smego RA, Jr, Bhatti S, Khaliq AA, Beg MA. Percutaneous aspiration-injection-reaspiration drainage plus albendazole or mebendazole for hepatic cystic echinococcosis: a meta-analysis. *Clin Infect Dis* 2003;37(8):1073-1083.
- Craig PS, McManus DP, Lightowers MW, et al. Prevention and control of cystic echinococcosis. *Lancet Infect Dis* 2007;7(6):385-394.