

Discrepant clinical and haematological features in siblings of Pakistani origin with β -thalassaemia

Andrea Prinsloo, MSc (Med Micro)

Johan J C Potgieter, MMed (Fam Med), MMed (Haemat)

Vanessa Moodley, MMed (Haemat)

Roger Pool, MMed (Haemat)

Department of Haematology, University of Pretoria and National Health Laboratory Services, Pretoria

Johannes Opperman, MMed (Path), MMed (Paed)

Department of Paediatrics, University of Pretoria and Gauteng Department of Health

Shirley Henderson, PhD

John Old, PhD, FRCPath

Oxford Haemophilia Centre, The Churchill Hospital, Headington, Oxford, UK

An 8-year-old boy was referred with anaemia and splenomegaly. Physical examination revealed short stature, thalassaemic facies, pallor and splenomegaly. The full blood count showed a hypochromic, microcytic anaemia. The serum ferritin level was normal. Haemoglobin electrophoresis revealed 56% HbF, 2.3% HbA₂ and 41.7% HbA. The boy's younger sister was subsequently found to have a mild hypochromic, microcytic anaemia with a marked increase in HbF level.

Using the polymerase chain reaction (PCR) and deoxyribonucleic acid (DNA) sequencing, two different β -thalassaemia mutations were identified in the parents. Both parents therefore had a β -thalassaemia trait, while both children were compound heterozygotes.

The proband had become transfusion dependent while his sister had managed to maintain her Hb above 8.5 g/dl. The family was studied for β -thalassaemia and hereditary persistence of fetal haemoglobin (HPFH) deletions. This showed that the daughter had inherited a single β -gene deletion from her mother while the son had not. Studies for HPFH mutations revealed that all four family members had one β -point mutation.

The presence of HPFH in this family cannot be considered to have any effect on the thalassaemia major phenotype as neither of these β -mutations are known to be associated with any HbF induction. It is also possible that the daughter inherited a non-deletional HPFH gene which her brother did not.

Haemoglobins consist of different combinations of α -, β -, γ - and δ -chains encoded by genes on chromosomes 11 and 16. Many naturally occurring, genetically determined variants of human haemoglobin (Hb) exist (>750); some of these are harmless but others have serious clinical implications. Clinical syndromes due to disorders of Hb synthesis are collectively referred to as 'haemoglobinopathies'.¹ These syndromes can be classified into three categories:

- Structural variants of Hb, e.g. sickle Hb (HbS)
- Failure or reduction in globin chain synthesis, e.g. thalassaemia
- Interruption or failure of conversion from fetal Hb to adult Hb. This group of disorders is referred to as hereditary persistence of fetal Hb (HPFH).

Heterogeneous groups of inherited conditions caused by defects in globin chain synthesis are called thalassaemia syndromes.¹ Clinical thalassaemic syndromes are a consequence of a reduced rate of globin chain synthesis. This leads to imbalanced globin production and defective Hb formation with resultant damage to red blood cells and their precursors. The clinical picture may vary greatly from completely asymptomatic microcytosis to profound anaemia incompatible with life.

Thalassaemic syndromes are among the most prevalent genetic disorders worldwide, with 4.83% of the world's population being carriers of globin variants. About 1.67% of all people are heterozygous for α - or β -thalassaemia.² Thalassaemias are most common in Mediterranean countries, the Arabian peninsula, the Indian subcontinent and South-East Asia.

Beta-thalassaemia is extremely heterogenous at the molecular level with over 200 different mutations having been described. These mutations fall broadly into two groups, viz. deletions of the β -globin gene and non-deletional mutations which may affect the transcription, processing or translation of the β -globin gene. These can affect every step in β -gene expression. β -thalassaemia major, a severe transfusion-dependent, inherited anaemia, occurs when there is a profound defect in β -chain synthesis.¹

Accumulation and precipitation of excess α -chains damages normoblasts and erythrocytes, resulting in severe anaemia. This leads to expansion of the bone marrow affecting development, bone formation and growth.³ If left untreated, 80% of children may die within the first 5 years.¹ Iron overload due to both increased intestinal absorption and regular blood transfusions damages the endocrine organs, liver and heart and is a major cause of morbidity and mortality.³

Deletion or mutation of a globin gene may lead to a reduction in globin chain synthesis. Simultaneous inheritance of more than one type of thalassaemia may either lessen the globin chain imbalance and ameliorate the condition or aggravate the imbalance, increasing the severity of the disorder.

Due to the large number of β -thalassaemia mutations, compound heterozygosity may occur with the subject having two mutant genes in the absence of a normal β -gene. β -thalassaemia may co-exist with a non-deletional HPFH resulting in a modification of the β -thalassaemia phenotype. In these cases the mean cell Hb (MCH) and mean cell volume (MCV) are higher and HbA₂ is decreased.⁴ Beta-thalassaemia intermedia represents a phenotype that is more severe than the asymptomatic β -thalassaemia trait but milder than β -thalassaemia major. This phenotype has been associated with numerous molecular abnormalities including co-inheritance of α - and β -thalassaemia, compound heterozygosity for β -thalassaemia and non-deletional forms of HPFH as well as compound heterozygosity for β -thalassaemia and other β -chain variants.

Thalassaemia is the most common inherited disorder in Pakistan, with the β -thalassaemia national carrier state estimated at 5.4%.⁵ This translates to between 5 and 6 million carriers in the country. Consanguinity is a major factor in Pakistan, with up to 72% of cases of β -thalassaemia major arising from marriages between first cousins.^{5,6} There are important ethnic and regional differences in the prevalence of mutations. The five most common mutations are IVSI-5 (G-C) (37.3%), Fr 8-9 (+G) (25.9%), del 619 (7.0%), Fr 41-42 (-TTCT) (6.7%) and IVSI-1 (G-T) (5.4%). Fr 8-9 (+G) is the most common mutation in northern Pakistan (41.3%), whereas IVSI-5 (G-C) is the most frequent mutation in southern Pakistan (52.2%).⁵ The high frequency of Fr 8-9 and IVSI-5 mutations suggests that these may be the oldest β -thalassaemia mutations in the Indian subcontinent. Less frequent mutations include IVS-II-848 (C→A), IVSI-1(G→A), IVS-II-1(G→A), Cd 15 (G→A), and Cap+1 (A→C).⁷

An interesting family of Pakistani origin was seen at our clinic. This family had a combination of different mutations and deletions resulting in varying clinical signs and symptoms.

Case report

An 8-year-old boy of Pakistani origin was referred by a general practitioner to the Steve Biko Academic Hospital with anaemia and splenomegaly as well as a history of lethargy and poor appetite of 1 month's duration. Further questioning revealed that his birth had been normal and he had attained milestones on time. The parents denied any history of haemoglobinopathies in the family. On specific questioning the mother stated that both her pregnancies had been uneventful.

Clinical presentation

Physical examination of the boy revealed short stature, typical thalassaemic facies, pallor and splenomegaly. A full blood count showed the following: Hb 7.5 g/dl; MCV 76.1 fl; MCH 24.9 pg; red cell distribution width (RDW) 27.6%; platelets $260 \times 10^9/l$; and white cell count $9.68 \times 10^9/l$ with a normal differential count. The reticulocyte count was 10.1% with an absolute value of $306 \times 10^9/l$. The serum ferritin value was normal (90.34 ng/l). Hb alkaline gel electrophoresis revealed raised levels of HbF and reduced HbA. Quantitation of these bands showed 56% HbF (increased), 2.3% HbA₂ (normal) and

41.7% HbA (reduced). Radiological examination of the skull and facial bones showed granular osteoporosis, widening of the diploe, thinning of the outer table and obliteration of the maxillary sinuses. A working diagnosis of homozygous β -thalassaemia was made.

At a subsequent visit the boy's younger sister was examined. Although she was small for her age, she showed no features of marrow expansion as had been noted in the brother. She did, however, have a mild hypochromic, microcytic anaemia with a marked increase in HbF level.

Laboratory findings

The findings on studies of the family are set out in Table I.

Figs 1 and 2 display the chromatograms of the propositus and his sister, respectively.

TABLE I. HAEMATOLOGICAL VALUES OF THE FAMILY MEMBERS						
	Hb	RBC	MCV	MCH	HbA ₂	HbF
Propositus (8 yrs)	7.5	3.22	76.1	24.9	2.3	56
Sister (6 yrs)	9.2	4.15	66.3	22.2	3.0	90
Mother	10.4	5.69	59.4	18.3	5.0	2.1
Father	14.7	6.94	60.2	21.2	5.3	1.3

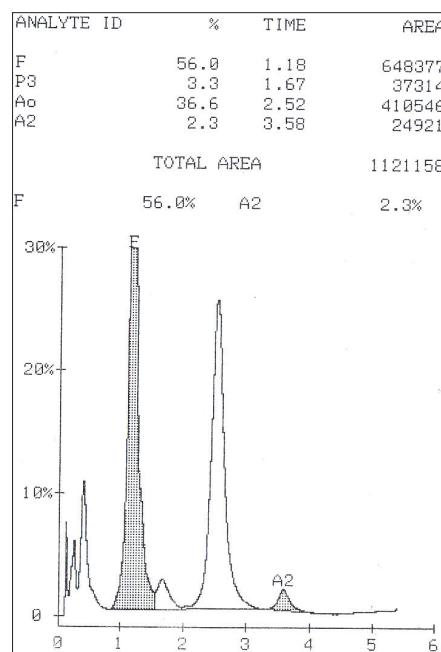


Fig. 1. High-performance liquid chromatography (HPLC) chromatogram of the propositus, indicating the large percentage of HbF (Bio-Rad Variant II HPLC instrument).

Using the polymerase chain reaction (PCR) and deoxyribonucleic acid (DNA) sequencing, we identified two β -thalassaemia mutations, viz. β^0 -thalassaemia Cd5 (-CT) in the mother and β^0 -thalassaemia Cd15 (G→A) in the father. Both parents therefore had a β -thalassaemia trait.

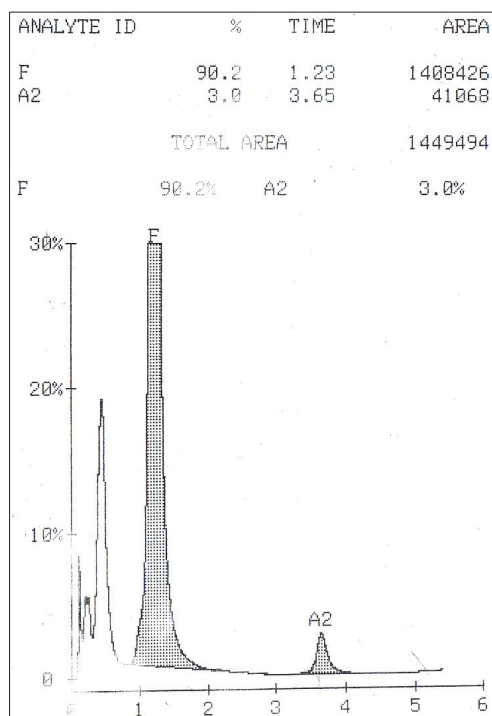


Fig. 2. HPLC chromatogram of the sister, also indicating a high percentage of HbF (Bio-Rad Variant II HPLC instrument).

The propositus and his sister were confirmed by PCR and DNA sequencing to be compound heterozygotes for the paternal and maternal β -thalassaemia mutations.

In view of the discrepancy between the siblings' clinical pictures the family was studied for α^+ -thalassaemia deletional mutations by gap-PCR (amplification across the breakpoints of a deletion). This showed that the sister had inherited a single α -gene deletion from her mother which the propositus had not. The sister was subsequently screened for the presence of an additional non-deletional α^+ -thalassaemia gene by DNA sequencing. The results showed a normal sequence for both the $\alpha 1$ - and $\alpha 2$ -genes, thus excluding non-deletional α^+ -thalassaemia.

Studies for HPFH mutations using Xmn I restriction enzyme digestion analysis revealed that all four family members had one $\alpha\gamma$ -158 C→T point mutation as well as one normal γ -gene.

Discussion

The propositus and his sister were both confirmed to be compound heterozygotes for β -thalassaemia, and as such would be expected to portray a severe phenotype. This was not the case, since the propositus had become transfusion dependent over the last year while his sister had managed to maintain her Hb above 8.5 g/dl without requiring transfusion.

A β -thalassaemia major phenotype may be ameliorated by an additional inherited factor such as α -thalassaemia or HPFH, which could transform the phenotype into one of thalassaemia intermedia. In contrast to the propositus, the sister was shown to have inherited a single α -gene deletion from her mother. While the α -gene deletion of the sister is unlikely to improve her phenotype, it may delay the onset of transfusion

dependence. Since DNA sequencing failed to confirm the presence of an additional non-deletional α^+ -thalassaemia gene in the sister and γ -globin gene promoter mutation has been found to be linked to several β^+ -thalassaemia mutations in some ethnic groups (e.g. the mutation IVSII-1 G→A), studies for HPFH mutations were performed. These mutations result in enhanced γ -chain production in response to anaemic stress. This increases the HbF level thus reducing the severity of the anaemia.

All four family members were shown to have one point mutation as well as one normal γ -gene. Because both children are heterozygous for the HPFH gene, one gene must be associated with one of the β -thalassaemia mutations while the other is linked to a haplotype with a normal β -gene, and the presence of the HPFH mutation in this family cannot therefore be considered to have any effect on the thalassaemia major phenotype.

Neither Cd15 (G→A) nor Cd5 (-CT) mutations are known to be associated with any HbF induction when present on a haplotype containing an Xmn I polymorphism, which is consistent with our findings.

Conclusion

Despite exhaustive electrophoretic and molecular investigations the phenotypic difference between the two children still cannot be completely explained. While inheritance of a single α -gene deletion may delay the onset of transfusion dependency, loss of two functional α -globin genes is required to ameliorate thalassaemia major to thalassaemia intermedia, either as co-inheritance of the α^0 -thalassaemia trait or homozygous α^+ -thalassaemia. This has been excluded in our patient's sister, whose results show that she has only the α^+ -thalassaemia trait. She therefore appears to have inherited an HPFH gene which her brother did not. This has to be unlinked to the β -globin gene cluster, such as the unidentified HPFH genetic determinants that have been found to be associated with either the X-chromosome or chromosome 6.

This study was supported in part by a NHLS trust grant and Bio-Rad South Africa.

References

- Wild B, Bain BJ. Investigation of abnormal haemoglobins and thalassaemia. In: Lewis SM, Bain BJ, Bates I, eds. *Dacie & Lewis Practical Haematology*. 10th ed. Philadelphia: Churchill Livingstone/Elsevier, 2006: 271-310.
- Rund D, Rachmilewitz E. β -thalassaemia. *N Engl J Med* 2005; 353: 1135-1146.
- Weatherall DJ. The thalassaemias. In: Beutler E, Lichtman MA, Coller BS, Kipps TJ, Seligsohn U, eds. *Williams Hematology*. 6th ed. New York: McGraw Hill, 2001: 547-580.
- Bain BJ. *Haemoglobinopathy Diagnosis*. 2nd ed. Oxford: Blackwell Publishing, 2006.
- Ahmed S, Petrou M, Saleem M. Molecular genetics of beta-thalassaemia in Pakistan: a basis for prenatal diagnosis. *Br J Haematol* 1996; 94(3-1):476-482.
- Khattak I, Khattak ST, Khan J. *Gomal Journal of Medical Sciences* 2006; 4(2): 52-56.
- Baig SM, Rabbi F, Hameed U, Qureshi JA, Mahmood Z. Molecular characterization of mutations causing β -thalassaemia in Faisalabad Pakistan using the amplification refractory mutation system (ARMS-PCR). *Indian Journal of Human Genetics* 2005; 11(2): 80-83.