

Surgical management of sialorrhoea: A review and outcome report from Red Cross Hospital, Cape Town

Graeme J Copley, MB ChB, FCS (Orl) (SA)

Department of Otorhinolaryngology, University of Cape Town and New Somerset Hospital, Cape Town

Chris A J Prescott, MB ChB, FRCS (Eng)

Department of Otorhinolaryngology, University of Cape Town and Red Cross War Memorial Children's Hospital, Cape Town

Johannes J Fagan, MB ChB, FCS (Orl) (SA), MMed

Department of Otorhinolaryngology, University of Cape Town and Groote Schuur Hospital

Aim. To review the surgical management of sialorrhoea (submandibular duct transposition with or without bilateral excision of the sublingual salivary glands: the 'drooling procedure', DP) at Red Cross War Memorial Children's Hospital, Cape Town.

Patients and methods. A retrospective review of the medical records of patients who had undergone a DP between 1996 and 2003, to ascertain the results of the procedure and complications. Subsequently a questionnaire was sent to all patients with a recognisable postal address to ascertain long-term satisfaction with the procedure.

Results. Forty-six patients had had a DP, and 32 of the medical records were available for analysis. In 23 cases a comment had been recorded on the result of the procedure; 18 (78%) had shown 'marked' improvement and 5 (22%) 'a little' improvement. The medical records indicated that 2 patients had had immediate postoperative problems: one patient was slow to commence oral feeding and another required a single high dose of intravenous steroids to resolve marked oedema of the floor of the mouth. In the longer term, one patient developed a ranula (a mucus inclusion cyst). Ten postal questionnaires, were returned; of these 8 reported an improvement in the symptoms.

Discussion. Short-term improvement was recorded in 78% of patients, and although only 10 questionnaires were returned, 8 of these indicated satisfaction with the procedure. It is impossible to draw conclusions, however, as the large number of patients (36 of the original 46) lost to follow-up could have had a poor outcome. There is need for prospective studies on the long-term outcome of the DP.

Sialorrhoea is the unintentional overflow of saliva from the oral cavity onto the lips, chin and clothes (Fig. 1). This is a normal and socially acceptable phenomenon in infants and small children; however oral motor function and control improve as the normal child develops and by the age of 4 years bibs and continuous wiping of the mouth are rarely needed. In children with neurological impairment such as cerebral palsy (defined as a congenital, non-progressive neurological disorder), or following meningitis, persistent drooling can increase the work of the caregiver and lead to embarrassment and social isolation.

There are also medical problems associated with sialorrhoea. The persistently wet skin on the lip and chin can become inflamed, infected and excoriated, and in rare cases the severely neurologically disabled child may aspirate saliva, leading to recurrent chest infections, or lose excessive amounts of fluids, leading to dehydration.¹⁻³

The incidence of sialorrhoea in South Africa is unknown but is probably higher than in developed countries owing to our poorer health care and higher incidence of cerebral palsy (the prevalence of cerebral palsy in rural KwaZulu-Natal has been calculated as 10/1 000).⁴ In North America 0.5 - 0.7% of all children born are diagnosed with cerebral palsy, and it is estimated that 10 - 30% of them have a problem with drooling. It is possible that in South Africa drooling is accepted as normal

for affected children, whereas effective management protocols, when applied appropriately, can significantly improve the quality of life of both the patient and the caregiver.¹⁻³

Persistent drooling is most commonly caused by poor muscular control and dysfunction of the voluntary phase of oral motor activity. This leads to pooling of saliva in the anterior floor of the mouth, which is exacerbated by poor neck muscle tone (the 'floppy' child), and the saliva overflows onto the lower lip and the chin. Drooling is rarely caused by excessive saliva production.

Patients with persistent drooling need to be assessed by a multidisciplinary team. Conservative physical and/or medical therapies are attempted before surgery in the management of sialorrhoea. At Red Cross War Memorial Children's Hospital in Cape Town bilateral submandibular duct transposition with or without bilateral excision of the sublingual salivary glands (the drooling procedure, DP) is the surgical procedure that has been used most often. This procedure is chosen over the others available because the surgery is relatively simple, there is no need for expensive sophisticated equipment such as lasers, and complications are usually minimal with improvement of symptoms. This procedure diverts the flow of saliva from the anterior floor of the mouth into the tonsillar fossa, where the pooling of saliva triggers the involuntary phase of swallowing. In conjunction with excision of the sublingual glands, the

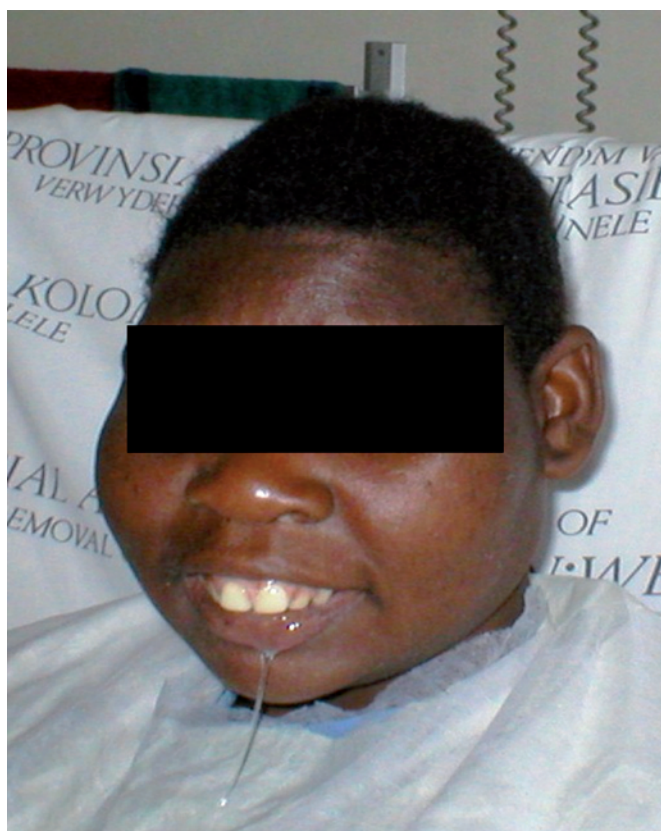

Fig. 1. Child with sialorrhoea.

procedure reduces the basal flow of saliva into the anterior floor of the mouth and therefore lessens the symptomatic drooling.¹⁻³

Aims

This report aims to assess the outcome of the surgical procedure offered to neurologically impaired children with profuse sialorrhoea resistant to conservative methods of control.

Patients and methods

A retrospective analysis was done of the medical records of all patients who had had a DP at Red Cross War Memorial Children's Hospital between 1996 and 2003. Data extracted included the underlying diagnosis, demographic details, the type of surgery performed, any immediate or late complications, length of follow-up, and any notes made regarding the persistence of sialorrhoea after surgery.

A postal survey questionnaire with a return self-addressed and stamped envelope was sent to all the patients/caregivers for whom we had a postal address. This questionnaire was to obtain feedback on their perception of the results of the procedure.

Results

Only 32 of 46 medical records of patients who had had the DP over the 7-year period were available for analysis. The gender distribution was even (15 females, 17 males), and the underlying neurological conditions are shown in Table I.

All the patients had a tonsillectomy at the beginning of the procedure unless this had been done previously. Ten of the

TABLE I. UNDERLYING PSYCHOMOTOR DYSFUNCTION OF THE PATIENTS WHO UNDERWENT THE DP

Diagnosis	No. of patients
Cerebral palsy	12
Microcephaly	7
Mental impairment (cause unknown)	4
Pseudobulbar palsy	2
Schizencephaly	4
Meningitis	2
Herpes encephalitis	1
ACTH deficiency	1

patients (31%) had diversion of the submandibular duct only, and the other 22 (69%) had both duct diversion and resection of the sublingual glands in the floor of the mouth. The surgical protocol was changed after it was observed that the incidence of postoperative salivary mucocele (ranula) seemed to be reduced by the concomitant excision of the sublingual gland.³

Immediate complications

There were few immediate complications, and the majority of the patients were discharged the day after the operation. However, one patient was slow to commence oral feeding and required supplementary orogastric tube feeds till discharged on the 3rd day after surgery. A second patient developed marked oedema of the floor of the mouth after surgery; this responded well to a single high dose of intravenous steroid, and the patient was discharged on the 3rd day after surgery.

Long-term complications

The duration of follow-up at the hospital outpatient department ranged widely from 2 weeks to 4 years, and it is possible that patients were followed up by their referring institutions. Nine patients had no record of any postoperative follow-up at Red Cross Hospital. One patient (who had only undergone ductal translocation without excision of the sublingual glands) developed a ranula. For 23 patients there was some comment on the result of the procedure; 18 (78%) had shown 'marked' improvement, whereas the other 5 (22%) showed 'little' improvement (Fig. 2).

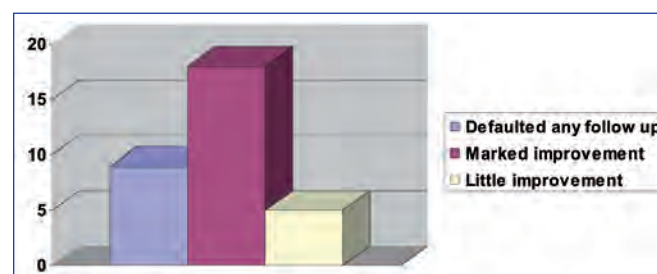

Fig. 2. Long-term follow-up.

We had an address for 30 patients and sent them each a questionnaire, but only 10 were returned. All 10 ticked that their child's lips were 'very wet' prior to surgery, and after surgery 5 were 'dry', 3 still a 'bit wet' and 2 still 'very wet'; i.e. 80% of responding caregivers reported an improvement in patient drooling.

Discussion

The management of sialorrhoea in neurologically disabled children can be challenging. Available treatments can be divided into conservative therapy and surgery; this discussion focuses on the latter.

The salivary glands secrete an average of 1 - 1.5 litres of saliva a day. There are three paired major salivary glands; the submandibular glands provide the basal salivary flow that makes up 70% of the total volume, the parotid glands secrete 20% in response to food stimulation, and the remaining 10% comes from the other paired sublingual glands, plus the hundreds of microscopic minor salivary glands in the mucosa of the palate, oral cavity and pharynx.

The main secretory control of the salivary glands is parasympathetic. In most cases sialorrhoea is due to an inadequate oral phase of swallowing, frequently secondary to neuromuscular disorders such as cerebral palsy or severe mental impairment. Sialorrhoea may occur following surgical resection or trauma in the oral cavity or paresis of the facial nerve. Rarely it may be due to hypersecretion, which can be a side-effect of medications such as tranquilisers, anticonvulsants and anticholinesterases.

Initial assessment of the severity of sialorrhoea can be suggested by the number of bibs/shirts changed per day, and whether the lips are constantly wet. It has been suggested that children with severe impairment of volitional motor function and profuse drooling tend to have a poorer outcome following surgery.³ In such cases surgery may improve symptoms but not cure the problem, so expectations need to be realistic. The severity and progression of the underlying neurological disorder also needs to be taken into consideration. If the neuromuscular co-ordination of swallowing is markedly affected there may be pooling of saliva in the hypopharynx (posterior drooling), with aspiration and related consequences. In such cases, procedures that increase salivary flow into the pharynx (such as relocation of the submandibular duct) would be inadvisable. The age of the patient should also be considered; under the age of 5 occasional spill of some saliva onto the lips is normal, but a normal child should not be drooling beyond that age.

Contributing factors such as nasal airway obstruction due to adenoidal hypertrophy or allergic rhinitis can cause mouth breathing, a slack jaw and drooling. Maxillofacial abnormalities such as a malocclusion, commonly associated with cerebral palsy, may worsen drooling. The child's posture and head control should be assessed, as the head hanging down in a 'floppy child', as well as poor oral motor co-ordination, a large tongue and poor control of the tongue, can all contribute to drooling. Appropriate first-line management should be instituted to rectify any contributing factors before treatment of the salivary glands is considered.

It is useful for these children to be assessed in a combined paediatric swallowing clinic by a multidisciplinary team comprising a speech/swallowing therapist, a physiotherapist and a paediatric otolaryngologist. The management of this multifactorial problem well illustrates the need to assess the patient holistically and to formulate an appropriate management plan. However, such multidisciplinary clinics are demanding on human resources and costly to run.

Infiltration of the salivary glands with botulinum toxin is a treatment option. The toxin blocks acetylcholine release from the presynaptic nerve terminal and causes a chemical

denervation and reduced saliva production of the injected gland.⁵ The toxin is expensive and not readily available, and the injection is painful - an important point, as multiple injections may be needed.

Surgical management would be indicated in a child with moderate to severe drooling in whom conservative therapy has failed or whose cognitive function precludes participation in conservative oral and physical therapy. The goal is to reduce saliva flow by resecting the glands, ligating the ducts or disrupting the nerve supply, or to divert the flow. Options include tympanic neurectomy and chorda tympani section, resection of major salivary glands (usually the submandibular gland), ligation or laser photocoagulation of salivary gland ducts, and submandibular duct diversion with or without sublingual gland resection.

All the above procedures have pros and cons. Transection of the chorda tympani and tympanic nerves as they pass through the middle ear may lead to the loss of taste sensation. It is also prone to late failure, as the nerves regenerate.⁶ A possible solution to this problem is to combine the approaches; for instance, transect the nerves on one side and remove the submandibular gland on the other. (S Sellars, personal communication).

Resection of the major salivary glands may lead to xerostomia, and there is a small but real risk of cranial nerve injury.⁷ Ligation of the ducts is a simple and effective treatment,

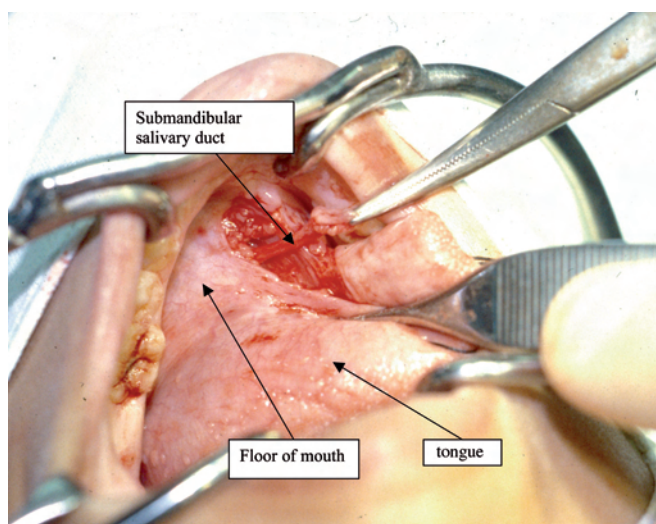


Fig. 3. Dissection of the submandibular duct.

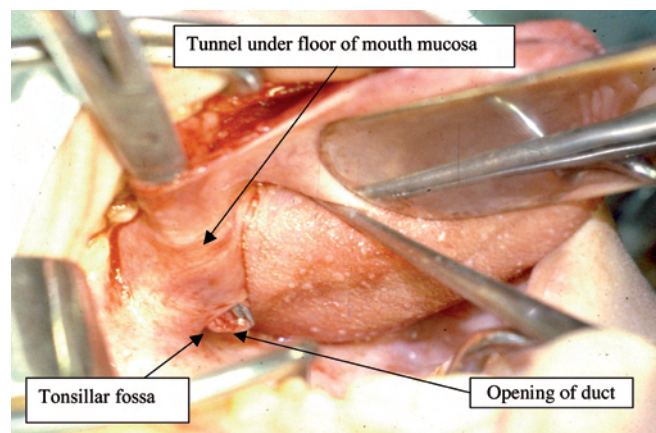


Fig. 4. Placement of duct.

especially when aspiration of saliva is a significant feature.⁸ Laser photocoagulation necessitates specialised expensive equipment not readily available in developing countries.⁹

The rerouting of the submandibular ducts (Figs 3 and 4) can lead to oedema of the floor of the mouth and formation of ranulas following trauma to the sublingual glands.⁵ The latter can be avoided by excising the sublingual glands at the same time as dissecting out the ducts. As far as we know only 2 of our patients had minor early complications that prolonged the postoperative stay, and there was 1 long-term complication (ranula formation), which necessitated a second operation.

Conclusion

Submandibular duct diversion with resection of the sublingual salivary glands appears to be a useful surgical option in the management of neurologically impaired children with significant sialorrhoea unresponsive to conservative management. The results from this centre indicated a 78% positive short-term outcome. Although 80% of caregivers reported long-term improvement, the number of questionnaires returned was too small (i.e. 10 of the original 32 patients with traceable records or the total of 46 treated)

to draw any meaningful conclusions. There is a need for prospective studies on the management of sialorrhoea.

References

1. Lloyd Faulconbrige RV, Tranter RM, Moffat V, Greene E. Review of management of drooling problems in neurologically impaired children. *Clin Otolaryngol* 2001; 26: 76-81.
2. Hockstein NG, Samadi DS, Gendron K, Handler SD. Sialorrhoea: A management challenge. *Am Fam Physician* 2004; 69: 2628-2634.
3. Crysedale WS, Raveh E, McCann C, Roske L, Kolter A. Management of drooling in individuals with neurodisability: a surgical experience. *Dev Med Child Neurol* 2001; 43: 379-383.
4. Couper J. Prevalence of childhood disability in rural KwaZulu-Natal. *S Afr Med J* 2002; 92(7): 549-552.
5. Suskind DL, Tilton A. Botulinum-A toxin in the treatment of sialorrhoea. *Laryngoscope* 2002; 112: 73-81.
6. Mullins WM, Gross CW, Moore JM. Long-term follow-up of tympanic neurectomy for sialorrhoea. *Laryngoscope* 1979; 89: 303-307.
7. Milton C, Thomas B, Bikerton R. Morbidity study of submandibular gland excision. *Ann R Coll Surg* 1986; 68:148-150.
8. Klem CK, Mair EK. Four-duct ligation. *Arch Otolaryngol Head Neck Surg* 1999; 125: 796-800.
9. Chang CJ, Wong AMK. Intraductal laser photocoagulation of the bilateral parotid ducts for the reduction of drooling in patients with cerebral palsy. *Plast Reconstr Surg* 2001; 107: 907-913.

Bioflora

Bioflora's probiotic products are recommended for both infants and toddlers and should be used:

- i) to introduce and maintain beneficial intestinal microflora in infants and toddlers;
- ii) to replenish oral and intestinal microflora after treatment with antibiotic;
- iii) to prevent and treat food allergies;
- iv) when there are symptoms of digestive disorders such as diarrhoea or constipation;
- v) when there is overgrowth of *Candida albicans* (thrush) in the mouth or vagina;
- vi) when it is desirable to boost the functions of the immune system;
- vii) when children have symptoms of lactose intolerance;
- viii) during steroid therapy, chemotherapy or radiotherapy.

The products are available at all pharmacies.

**For further information contact Bioflora at:
012 3482367 or
bioflora@lantic.net**

