

Late-neonatal SARS-CoV-2 infection: A curious case of COVID-19 with respiratory co-infection and treatment with surfactant

E Verster,¹ MMed (Paed); L-A Naicker,¹ MB ChB, MSc; K Chetty,¹ MB BCh; L van Wyk,² FCPaed, Cert Neonatol, MSc (Neonatology)

¹ Department Paediatrics, Klerksdorp-Tshepong Tertiary Hospital, Klerksdorp, South Africa

² Division of Neonatology, Department Paediatrics and Child Health, Tygerberg Hospital, Cape Town, South Africa

Corresponding author: E Verster (ewan.verster@gmail.com)

At the height of the COVID-19 pandemic, South Africa became the epicentre of the continent. Considering the paucity of data on COVID-19, we aimed to describe the clinical picture in a neonate, alert healthcare workers to the presence of co-infection with COVID-19 and propose alternative treatment modalities. The use of surfactant was based on the pathophysiological mechanisms of severe acute respiratory syndrome coronavirus-2 (SARS-CoV-2). There is mounting evidence in support of using surfactant in the management of severe COVID-19. While viral co-infection is a common occurrence among neonates, our case shows that COVID-19, together with rhinovirus infection, may result in a more rapid clinical deterioration, as opposed to rhinovirus infection in isolation.

S Afr J Child Health 2023;17(2):e1946. <https://doi.org/10.7196/SAJCH.2023.v17i2.1946>

COVID-19, caused by the novel severe acute respiratory syndrome coronavirus-2 (SARS-CoV-2), resulted in pandemic-proportion spread and an unprecedented global lockdown.^[1] Despite stringent lockdown measures, South Africa became the epicentre of the continent. Owing to the paucity of data regarding neonatal disease and outcomes, the neonatal mortality rate remains unclear.

Considering the increasing availability of data on COVID-19, early and late presentations and management thereof in the neonate, we aimed to describe the clinical picture, consider the presence of co-infection in the very young, and explain the unique management, which is now being more widely reported on, resulting in a successful outcome as shown in our case.^[1-3]

Ethics

Informed consent was obtained from the mother. Ethics approval was obtained from the Klerksdorp Hospital Patient Safety Group Panel.

Case

A male infant presented on day 25 of life with a one-day history of tachypnoea and poor feeding. He was a full-term baby with a birthweight of 2 900 g, delivered via an uncomplicated spontaneous vaginal delivery to an HIV-infected and virologically suppressed mother. The mother had received regular antenatal care and she had no respiratory symptoms nor recent contact with individuals infected with COVID-19 or tuberculosis.

Physical examination revealed an appropriately grown (3 500 g) afebrile infant with the following vital measurements: pulse, 152 bpm; tachypnoea, 55 - 60 bpm; and peripheral oxygen saturation at 80% on room air, which subsequently improved to 98% on oxygen via nasal cannula at 1 L/min. Examination revealed moderate respiratory distress (characterised by nasal alar flaring and mild intercostal and subcostal recessions), with normal breath sounds bilaterally and no adventitious sounds. The systemic examination was otherwise unremarkable. Bilateral diffuse dense infiltrates were

observed on chest radiography. Haematological investigations were initially normal, with a white cell count of $11.06 \times 10^9/L$, normal differential count, C-reactive protein of 1 mg/L and no metabolic derangements. An HIV polymerase chain reaction (PCR) test was negative at birth.

The infant was admitted with severe pneumonia. Supplemental oxygen therapy was initiated and antibiotics (175 mg ampicillin 12-hourly and 15 mg gentamicin 24-hourly by intravenous (IV) injection) and IV fluids were administered. The initial nasopharyngeal SARS-CoV-2 real-time PCR (RT-PCR), routinely done on all admissions, was negative. Within hours, the infant showed signs of worsening respiratory distress and increasing oxygen requirements.

Five hours after admission, the infant required admission to the neonatal intensive care unit (NICU). Pressure-synchronised intermittent mandatory ventilation (PSIMV) was commenced and pyrexia (38.5 °C) was documented. A follow-up of his chest X-ray also showed worsening opacifications with bilateral diffuse parenchymal infiltrates, a cardiothoracic ratio of <60% and no pleural effusions. Owing to HIV exposure and a recent community outbreak of pertussis, he was initiated on cefotaxime (providing gram-negative cover), azithromycin (to cover atypical organisms), co-trimoxazole and prednisone (*Pneumocystis jirovecii* cover). He was sedated with a morphine and fentanyl infusion. Hypotension was noted in the NICU, which precipitated dobutamine administration at 10 µg/kg/min. Cardiac failure was not present, and myocarditis was not considered as part of the clinical picture. Heparinisation was done via a peripheral arterial line that was used for ease of blood sampling.

Significant hypoxic respiratory failure persisted despite escalation from PSIMV to high-frequency oscillatory ventilation (HFOV). The clinical deterioration together with oxygen index exceeding 40 was indicative of a grave outcome. Local guidelines suggested initiating extracorporeal membrane oxygenation (ECMO), which was not available in our setting. Fig. 1 demonstrates the respiratory support

CASE REPORT

instituted relative to the alveolar-arterial oxygen gradient (A-aDPO₂) and oxygen index (OI) used to evaluate the severity of lung injury and escalation of treatment.

At this precipice, surfactant was administered at 20 hours of admission at 4 mL/kg (100 mg/kg bovine surfactant). An immediate improvement was observed, with rapidly normalising clinical and biochemical parameters. Chest radiography also showed significant improvement. A repeated nasopharyngeal SARS-CoV-2 RT-PCR, done at 19 hours, i.e. one hour before surfactant administration, yielded a positive result and a viral-plex PCR panel was positive for rhinovirus. PCR and blood cultures for *Bordetella pertussis* were negative. The infant was successfully weaned off inotropic support after 12 hours; no cardiac murmurs were present and cardiac failure was not noted. No bleeding or clotting tendencies were noted, therefore a clotting profile was not done. Seizures were not documented.

The infant continued to improve and was weaned onto PSIMV 4 days post surfactant replacement therapy (SRT) and extubated 9 days after admission. He required nasal prong oxygen for a further eight days, together with rehabilitation from allied healthcare professionals. He was discharged from hospital 18 days after admission to complete courses of co-trimoxazole and prednisone. Follow-up revealed good weight gain and no major morbidities related to respiratory sequelae, growth, and development.

Discussion

We presented a case of severe pneumonia in a 25-day infant who tested positive for community-acquired SARS-CoV-2 and rhinovirus. The infant was treated with HFOV and SRT. Most paediatric cases of COVID-19 are asymptomatic or mildly symptomatic, with only 5% accounting for severe cases; 0.6% are critical cases and mortality is rare.^[2,4] This may be attributed to the protective effect of age; children are not subjected to age-related immune-senescence and exhibit a different immune response compared with adults.^[4] However, newborn infants have a higher rate of severe infection (12%), with the predominant presentation being respiratory distress.^[3]

Neonates have immature innate and adaptive immune responses, which would diminish the risk of the cytokine storm and consequently may present and respond differently. The severity varies substantially with a spectrum from respiratory distress to respiratory failure, septic shock and multi-organ dysfunction/failure requiring

intensive care. Based on the COVID-19 clinical severity tool described by Dong *et al.*,^[5] our patient presented at the severe stage and progressed to the critical stage.

Multisystem inflammatory syndrome in neonates (MIS-N) is a relatively new entity, which was previously underreported; however, it is now garnering interest in new cases of COVID-19. MIS-N is proposed to be an exaggerated response to SARS-CoV-2 in response to maternal antibodies.^[1] Neonates could be ill with cardiac compromise (myocarditis, coronary aneurysms and left ventricular dysfunction), disseminated intravascular coagulation (DIC), feeding intolerance and vomiting resembling necrotising enterocolitis, hypoxaemia, persistent pulmonary hypertension of the newborn and renal failure.^[1] A vasculitic rash may also be present. Biochemical investigations are suggestive of a hyperimmune response, with elevated acute-phase reactants. The DIC screen (reduced fibrinogen, thrombocytopenia, neutropenia, lymphopenia, increased D-dimers) is largely positive. Our case did not show clinical features of MIS-N and this entity was largely underreported when the patient presented.

Community-acquired viral co-infection has increased world-wide, with co-infections in as many as 50% of COVID-19 cases.^[2] Viral pathogens mainly included respiratory viruses, e.g. enterovirus/rhinovirus, human metapneumovirus, parainfluenza virus type 2, influenza virus A, respiratory syncytial virus, and other non-COVID-19 coronaviruses. The mechanisms involve virally induced airway damage, decreased

mucociliary clearance, and immune dysfunction.^[1] Furthermore, co-infection in COVID-19 disrupts intestinal homeostasis promoting infection, as well as immune stimulation which produces an exaggerated inflammatory response. It remains unclear whether it is the immune dysregulation or co-infection of SARS-CoV-2 with other organisms that increases susceptibility to severe disease.

Treatment of COVID-19 in neonates and children was initially mostly nonspecific and supportive. Haemodynamic stabilisation, respiratory management and other means of routine care are essential. Many drugs against the cytokine storm are still under investigation. However, systemic steroids have been shown to decrease mortality in cases of COVID-19 requiring supplemental oxygen.^[1] It is hypothesised that the benefit may be attributed to the anti-inflammatory effect and dexamethasone, in particular, has been shown to stimulate synthesis of pulmonary surfactant. The effects of immune modulators and antiviral drugs have been contentious owing to a lack of randomised controlled evidence, especially in neonates.

Postmortem histopathological studies in lungs of patients who demised as a result of COVID-19 showed pneumocyte destruction with hyaline membrane formation, interstitial lymphocyte infiltration and multinucleated syncytial cells.^[6] Lung histopathology after virally induced acute respiratory distress syndrome, including COVID-19, are typically described as passing through three overlapping phases, i.e. inflammatory (or

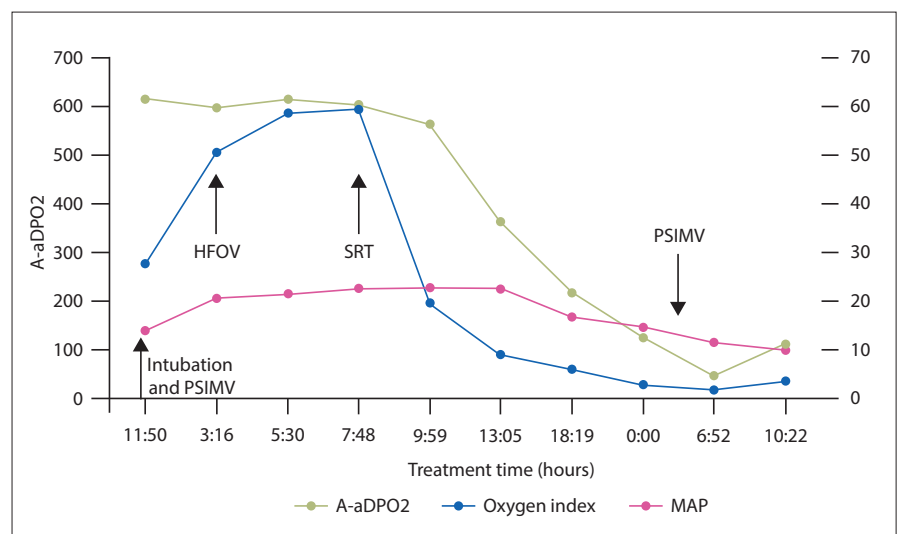


Fig. 1. Respiratory support measures utilised relative to the alveolar-arterial oxygen gradient (A-aDPO₂), mean airway pressure (MAP), oxygen index (OI) and timeline in the present case (neonate with SARS-CoV-2 infection). (PSIMV = pressure-synchronised intermittent mandatory ventilation; HFOV = high-frequency oscillatory ventilation; SRT = surfactant replacement therapy.)

CASE REPORT

exudative), proliferative and fibrotic (phases). These phases may be complicated by episodes of nosocomial pneumonia and/or exacerbated by inappropriate ventilator strategies. Thus, COVID-19 pneumonia is postulated to be analogous to neonatal respiratory distress syndrome owing to surfactant deficiency.

It is important to treat the patient in a holistic manner. Inter-professional collaboration, including the involvement of a physiotherapist, occupational therapist, dietician and social worker, is key to successful treatment outcomes, as illustrated in our case. This includes long-term follow-up, involving monitoring for sequelae of COVID-19, its effects on neurodevelopment and impact on the family unit.

Conclusion

We discussed the management of a neonatal case of severe-to-critical COVID-19. We used combined oxygen therapy, HFOV, steroids and surfactant, which resulted in a successful outcome. A limitation is that this is a single case study, where the proposed treatment plan cannot be used to advocate for routine management in viral co-infections in neonates. Clinicians should be aware of the possibility of an exaggerated response to co-infection with SARS-CoV-2 and other viruses, to the extent that conventional treatment modalities may fail. Although used in our case, the use of antimicrobials is still contentious. Further studies are needed, perhaps with a larger cohort, to indicate whether the treatment used in our study is viable.

Declaration. None.

Acknowledgements. The authors wish to acknowledge all healthcare personnel involved in the case and their contribution to the successful outcome.

Author contributions. EV: literature review, case writeup, editing, correspondence; LN: case writeup and editing; KC: clinical writeup and editing; LvW: literature review and editing.

Funding. None.

Conflicts of interest. None.

1. Sankaran D, Nakra N, Cheema R, Blumberg D, Lakshminrusimha S. Perinatal SARS-CoV-2 infection and neonatal COVID-19: A 2021 update. *Neoreviews* 2021;22(5):e284-295. <https://doi.org/10.1542/neo.22-5-e1001>
2. Di Nardo M, van Leeuwen G, Loreti A, et al. A literature review of 2019 novel coronavirus (SARS-CoV2) infection in neonates and children. *Pediatr Res* 2021;89(5):1101-1108. <https://doi.org/10.1038/s41390-020-1065-5>
3. Liguoro I, Pilotto C, Bonanni M, et al. SARS-CoV-2 infection in children and newborns: A systematic review. *Eur J Pediatr* 2020;179:1029-1046. <https://doi.org/10.1007/s00431-020-03684-7>
4. Yonker LM, Shen K, Kinane TB. Lessons unfolding from pediatric cases of COVID-19 disease caused by SARS-CoV-2 infection. *Pediatr Pulmonol* 2020;55(5):1085-1086. <https://doi.org/10.1002/ppul.24748>
5. Dong Y, Mo X, Hu Y, et al. Epidemiology of COVID-19 among children in China. *Pediatrics* 2020;145(6):1-10. <https://doi.org/10.1542/peds.2020-0702>
6. Afewerky HK. Pathology and pathogenicity of severe acute respiratory syndrome coronavirus 2 (SARS-CoV-2). *Exp Biol Med* 2020;245(15):1299-1307. <https://doi.org/10.1177/1535370220942126>

Accepted 7 February 2023.