

# Too much diarrhoea, too many infections, and too few neutrophils

T Padayachi, MB ChB, DCH (SA), FCP (Paed) (SA); I E Haffejee, MB BCh, MD, FCP (Paed) (SA), FCFP (SA)

Department of Paediatrics and Child Health, Nelson R Mandela School of Medicine, University of KwaZulu-Natal, and King Edward VIII Hospital, Durban, South Africa

Corresponding author: I E Haffejee (iehaffejee@hotmail.com)

Neutropenia is a common finding in ill paediatric patients and can be conveniently subdivided into that due to decreased production or increased destruction. Intrinsic defects in granulocytes or their progenitors or extrinsic factors such as infection, drugs and autoimmune phenomena are the main causes. Our case focuses on cyclic neutropenia presenting with severe chronic diarrhoea lasting 17 weeks, multiple recurrent bacterial infections and pulmonary tuberculosis (TB). To our knowledge this is the first case of pulmonary TB described in association with cyclic neutropenia and chronic diarrhoea in Africa.

*S Afr J Child Health* 2016;10(1):96-98. DOI:10.7196/SAJCH.2016.v10i1.1050

A 7-month-old boy was admitted to the paediatric gastroenteritis ward in King Edward VIII Hospital, Durban, with acute gastroenteritis of 3 days' duration. Birth history was significant for prematurity with a low birth weight of 1.55 kg secondary to premature rupture of membranes. He developed neonatal respiratory distress syndrome requiring surfactant replacement therapy as well as intermittent positive pressure ventilation for the first 6 days of life. He was also HIV-exposed and had received perinatal antiretroviral prophylaxis; the HIV polymerase chain reaction (PCR) was negative at 6 weeks of age. Previous medical history included an admission at another hospital for acute gastroenteritis, and lower respiratory tract infection at 3 months of age. The baby had been exclusively formula fed from birth, with complementary foods introduced from 5 months of age. There was no family history of recurrent infections or unexplained deaths.

Clinical examination revealed an acutely malnourished patient (weight 3.36 kg, length 57 cm), whose weight-for-length *z*-score was  $<-3$ . He was moderately dehydrated, and not in hypovolaemic shock. He had oral candidiasis, generalised lymphadenopathy, and hepatomegaly. Blood tests showed a mild metabolic acidosis with no electrolyte derangements (sodium 139 mmol/L, potassium 3.4 mmol/L, chloride 112 mmol/L, sodium bicarbonate 17 mmol/L, anion gap 13 mmol/L, urea 1.6 mmol/L, creatinine 22  $\mu$ mol/L), and a slightly low serum albumin of 27 g/L. The full blood count showed a normocytic normochromic anaemia of 8 g/dL, a platelet count of  $284 \times 10^9/L$ , and remarkably, a leucopenia of  $1.11 \times 10^9/L$  with a severe neutropenia of  $0.3 \times 10^9/L$ , a normal lymphocyte count ( $0.65 \times 10^9/L$ ) and monocytes of  $0.14 \times 10^9/L$ . Blood levels of folate, iron and vitamin B<sub>12</sub> were normal, and the direct Coombs' test was negative. There was no reticulocytosis.

Blood culture was positive for *Escherichia coli* sensitive to amoxicillin-clavulanic acid and gentamicin, which were administered for 1 week. Two weeks later he developed culture-positive nosocomial *Enterobacter aerogenes* septicaemia, which was treated with piperacillin-tazobactam and amikacin. The neutrophil count at this stage was  $0.37 \times 10^9/L$ . Stool cultures were negative for bacteria, viruses and parasites, and stools were not fatty or foul smelling. Faecal elastase levels were adequate ( $>500 \mu\text{g/g}$ ). The diarrhoea continued despite introducing a lactose-free formula after 4 days in hospital, necessitating semi-elemental formula feeds 9 days after admission. The gastroenteritis resolved 3 weeks after admission, only to recur soon after.

After resolution of the bacterial sepsis with two subsequent negative blood cultures over a period of 2 weeks, the patient remained persistently neutropaenic, and continued to have diarrhoea. Viral studies (cytomegalovirus, Epstein-Barr virus, toxoplasma, parvovirus, rotavirus and adenovirus) were all negative, including a repeat HIV PCR. Thyroid function was normal (thyroid-stimulating hormone 1.56 mIU/L, T4 9.9 pmol/L), and serum complement levels (C3 0.67 g/L, C4 0.2 g/L) and immunoglobulin concentrations (IgG  $<0.25 \text{ g/L}$ , IgA 0.95 g/L, IgM  $<0.15 \text{ g/L}$ ) were within normal limits.

Due to the high prevalence of tuberculosis (TB) in South Africa (SA), a presumptive diagnosis of TB was considered as a cause of the chronic nature of the diarrhoea. Purified protein derivative (Mantoux) test was negative but this could have been a false negative owing to severe malnutrition. Radiography of the chest revealed hilar lymphadenopathy; there were no other features suggestive of TB. Abdominal ultrasonography showed no granulomas or enlarged lymph nodes. Microscopy of gastric washings for acid-fast bacilli using the auramine stain was negative. The patient was empirically started on anti-TB treatment 6 weeks after admission. Sputum culture was later found to be positive for acid-fast bacilli, and anti-TB treatment was continued for 6 months. It should be noted that although the patient had a radiological finding of hilar adenopathy together with culture-proven pulmonary TB, a diagnosis of abdominal TB was not confirmed.

Eventual resolution of the chronic diarrhoea only took place 17 weeks after admission.

## Differential diagnosis

The aetiology of neutropenia can be broadly divided into defects of myelopoiesis and extrinsic factors like malnutrition, drugs or autoimmune phenomena.<sup>[1]</sup> Diarrhoea is a frequent complication of neutropenia.<sup>[2]</sup> In our patient, a differential diagnosis of (i) cyclic neutropenia, (ii) chronic congenital neutropenia, (iii) chronic idiopathic neutropenia and (iv) Schwachman-Diamond syndrome (exocrine pancreatic insufficiency with neutropenia) was considered. Other conditions were excluded on clinical and laboratory grounds (Table 1). Combined immune deficiency is very unlikely in our patient since the immunoglobulin levels were within normal limits. Oral candidiasis as well as lymphadenopathy has been described in cyclic neutropenia by previous workers.<sup>[1,3]</sup>

Bone marrow aspirate and trephine biopsy revealed normocellular marrow in which infection could not be definitively excluded.

## CASE REPORT

No granulomas or infiltrates were observed. Myelopoiesis was hypoplastic with a left shift; however, it was adequate and sequential; maturation arrest was not present, more mature forms being present. This is consistent with a diagnosis of cyclic neutropenia.<sup>[3]</sup>

While hospitalised our patient had a series of infections, including a lower respiratory infection, cellulitis following intravenous line insertion, septicaemia with associated thrombocytopenia, and elevated C-reactive protein. Most infections followed procedures such as intravenous line insertion and bone marrow aspiration. Apart from the pathogens mentioned above, *Pseudomonas* and *Staphylococcus* spp. were also cultured sequentially at 2 - 3-week intervals, the neutrophil count ranging from  $0.3 \times 10^9/L$  to  $0.37 \times 10^9/L$  (Table 2). Antibiotics used included meropenem and ciprofloxacin together with antifungals.

There was no hepatic dysfunction aside from a decreasing albumin level from 27 g/L on admission to 14 g/L 5 months later. The

persistence of neutropenia and diarrhoea together with recurrent infections prompted us to administer granulocyte colony-stimulating-factor (G-CSF) in an attempt to raise the neutrophil count.<sup>[3]</sup>

Severe congenital neutropenia appeared unlikely as the bone marrow did not show 'maturation arrest' at the myelocyte stage of development, the promyelocytes were not increased nor showed dysplastic morphology such as large size, atypical nuclei or vacuolated cytoplasm. The clinical hallmarks of chronic idiopathic neutropenia are an acquired neutropenia with a relatively stable, suppressed neutrophil count without recurrent infections.<sup>[1]</sup> Our patient did not seem to fit into either of these two categories. Chronic diarrhoea with neutropenia is a feature of Schwachman-Diamond syndrome but this was ruled out by the non-fatty stools and normal stool elastase; there was also no evidence of skeletal dysplasia.<sup>[4]</sup>

We suspect that our patient had cyclic neutropenia despite persistently (non-cyclic) low counts of  $<2 \times 10^9/L$  for the first 3 months. Fig. 1 shows that from 12 weeks onwards there were regular cyclic periods when the neutrophil count dropped with a concomitant rise in the monocyte count; this is consistent with a diagnosis of cyclic neutropenia, which is characterised by periodic oscillations with approximately 3-weekly nadirs. Oscillations can be subtle in some patients.<sup>[1]</sup> There was a reciprocal monocytosis at each low point of the neutrophil count in our patient, who responded to three courses of G-CSF but still experienced neutropaenic cycles; this has been described in the literature.<sup>[1]</sup> The amplitude of the cycling may increase, but with shortened cycle periods and increased neutrophil counts at the nadir.<sup>[1]</sup> The baby was finally discharged 35 weeks after admission with a weight of 5 kg. When seen at follow-up 9 weeks after discharge, his neutrophil count was  $1.17 \times 10^9/L$  with a monocyte count of  $0.9 \times 10^9/L$  and he was thriving and well.

### Discussion

Cyclic neutropenia is an autosomal dominant genetic disorder with full penetrance but varying degrees of clinical manifestations; sporadic cases can arise from new germ line mutations. The disorder is secondary to a mutation in the neutrophil elastase gene that leads to increased apoptosis in neutrophil precursors. The genetic diagnosis can be confirmed by sequencing of the ELA2 gene.<sup>[1]</sup> Unfortunately, this genetic test is not available for use in SA.

The primary cellular abnormality in cyclic neutropenia is apoptosis of neutrophil precursors and their removal by marrow macrophages. This can be shown by flow cytometry which demonstrates increased

**Table 1. Differential diagnosis of neutropenia (adapted)<sup>[1]</sup>**

Neutropenia caused by intrinsic defects in granulocytes or their progenitors
Cyclic neutropenia
Severe congenital neutropenia
Schwachman-Diamond syndrome
Reticular dysgenesis (associated with severe combined immunodeficiency)
Albinism/neutropenia syndromes (including Chédiak-Higashi)
Familial benign neutropenia
Bone marrow failure syndromes (congenital and acquired)
Neutropenia caused by extrinsic factors
Infection
Drug-induced neutropenia (e.g. indomethacin, valproate, phenytoin, penicillin)
Autoimmune neutropenia
Nutritional deficiencies
Bone marrow infiltration
Reticuloendothelial sequestration

**Table 2. Sequence of WCC, B/C results and clinical infections during admission**

	Total WCC	Absolute neutrophils	Absolute lymphocytes	Absolute monocytes	Microbiology results	Concurrent clinical infection
On admission	1.11	0.30	0.65	0.14	B/C <i>E. coli</i> followed by <i>Enterobacter</i> spp.	Septicaemia, gastroenteritis
Week 4	0.87	0.30	0.31	0.22	B/C <i>Pseudomonas</i>	Septicaemia, gastroenteritis
Week 6	1.36	0.57	0.44	0.33	B/C <i>S. aureus</i>	Pneumonia
Week 14	1.23	0.31	0.45	0.46	-	Gastroenteritis
Week 19	2.79	1.56	0.25	0.96	-	Thrombophlebitis
Week 23	2.15	0.80	0.37	0.96	Pus swab <i>Pseudomonas</i>	Cellulitis
Week 27	3.30	1.58	0.76	0.95	-	Thrombophlebitis
Week 29	12.91	6.75	1.36	4.54	-	-
Week 33	3.00	0.90	1.02	1.08	-	-
Week 45	5.83	2.17	1.34	2.28	-	-

WCC = white cell count; B/C = blood culture.

## CASE REPORT

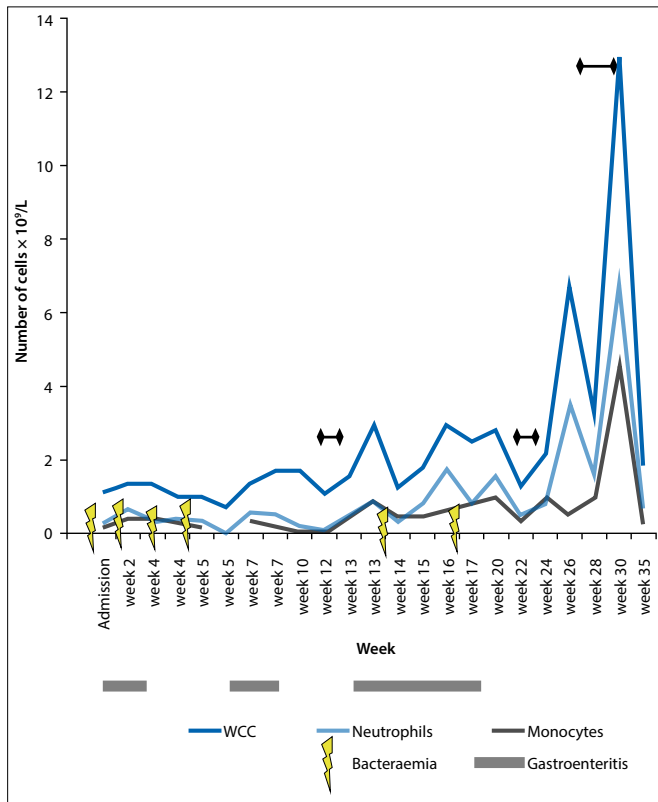


Fig. 1. Response to courses of G-CSF.

numbers of annexin-V stained cells. Furthermore, a lymphocyte subset defect (which can give a similar clinical presentation) can also be diagnosed by flow cytometry. This was not carried out in our patient and is thus a limitation of our study. The diagnosis of cyclic

neutropenia was based on the clinical presentation, the cyclical nature of the low neutrophil counts with reciprocal monocytosis, and the bone marrow abnormalities. It should be noted that the 'typical' bone marrow abnormality seen in cyclic neutropenia, namely hypoplasia of the myeloid series with maturation arrest at the myelocyte stage, was not seen in our patient; however, this occurs during the declining phase of the neutrophil oscillation, and myelopoiesis can be normal or even hyperplastic during neutrophil recovery.

This case illustrates a number of learning points: (i) ongoing diarrhoea of very long duration should be thoroughly investigated to look for a definite underlying cause and not be dismissed as being 'post-enteritic'; (ii) a low leucocyte count, especially a low neutrophil count, must never be ignored and an attempt at establishing its aetiology should always be made; and (iii) apart from bacterial pathogens causing sequential severe infections, especially following invasive procedures, TB should always be searched for in communities where it is endemic. To our knowledge, this is the first case of pulmonary TB described in association with cyclic neutropenia and chronic diarrhoea in the African continent.

**Acknowledgements.** The authors would like to thank Drs N Mathenjwa and K Naidoo for assisting with patient management.

### References

- Dinauer MC, Newburger PE. The phagocyte system and disorders of granulopoiesis and granulocyte function. In: Orkin SH, Nathan DG, Ginsburg D, Look AT, Fisher DE, Lux SE, eds. *Nathan and Oski's Hematology of Infancy and Childhood*. 7th ed. Philadelphia: Saunders, 2009:1109-1220.
- Aksoy DY, Tanriover MD, Uzun O, et al. Diarrhoea in neutropenic patients: A prospective cohort study with emphasis on neutropenic enterocolitis. *Ann Oncol* 2007;18(1):183-189. [<http://dx.doi.org/10.1093/annonc/mdl337>]
- Dale DC, Bolyard AA, Aprikyan A. Cyclic neutropenia. *Semin Hematol* 2002;39(2):89-94.
- Burroughs L, Woolfrey A, Shimamura A. Shwachman-Diamond syndrome: A review of the clinical presentation, molecular pathogenesis, diagnosis, and treatment. *Hematol Oncol Clin N Amer* 2009;23(2):233-248. [<http://dx.doi.org/10.1016/j.hoc.2009.01.007>]