

Session 2 Stress factors associated with nutrition in the subtropics and tropics

Ovine wet carcass syndrome of unknown aetiology

R.M. Brock, J.P.J. Joubert, A. Hattingh, G. Mitchell, S.J. Newsholme*, R.R. van der Veen, H.S. Hofmeyr, E.A.N. Engels, H.B. Groenewald and Pamela Hunter

*Address correspondence to:
Dr S.J. Newsholme, Pathology, Veterinary Research Institute, Onderstepoort 0110 South Africa.

A condition of unknown aetiology, known as 'the wet sheep carcass syndrome' has led to the loss of about R500 000 as a result of the condemnation and trimming of carcasses, during the past 2 years. An affected carcass has a shiny, wet appearance due to the accumulation of watery fluid in subcutaneous tissues over the buttocks, sides and flanks. It cannot be diagnosed in the live animal.

'n Toestand waarvan die oorsaak onbekend is, staan bekend as 'die nat skaapkarkassindroom'. Dit het 'n verlies van sowat R500 000 veroorsaak in die afgelope 2 jaar, weens die afkeuring en gedeeltelike regsny van karkasse. 'n Aangetaste karkas het 'n blinknat voorkoms as gevolg van die aansameling van waterige vloeistof in die subkutane bindweefsels oor die boude, sye en flanke. Dit kan nie in die lewendige dier gediagnoseer word nie.

Keywords: Ovine, wet carcass, non-inflammatory, unknown aetiology

Introduction

Wet sheep carcasses were seen with increasing frequency at abattoirs from January 1981. They were unacceptable to the consumer due to poor keeping qualities and un-aesthetic appearance. This resulted in the condemnation of about 90 000 carcasses valued at R400 000 and the losses due to trimming of other carcasses amounted to R100 000 or more over the past two years.

The syndrome is characterised by the accumulation of a watery fluid in the subcutaneous tissues covering the buttocks, sides, back and flanks of such a carcass. This watery fluid also occurs in the intermuscular connective tissue layers of the flanks and subscapular area. The inside of the skin has the same wet, glistening appearance, which is easily recognizable even at a distance of 10 metres.

Results and Discussion

Appearance of a wet carcass

This can be seen in Figure 2, where colour photographs of wet carcasses are presented.

Animals affected, incidence and area of origin

The condition is commonest in Dorper sheep, but it also occurs in Karakuls and to a lesser extent in Merino-crosses. Most sheep are marketed at 4–8 months of age and hence this age group is most affected. The syndrome is prevalent in sheep of the Gordonia district and adjacent areas, with only a few cases reported from the Southern Orange Free State (See Figure 1). The incidence varies

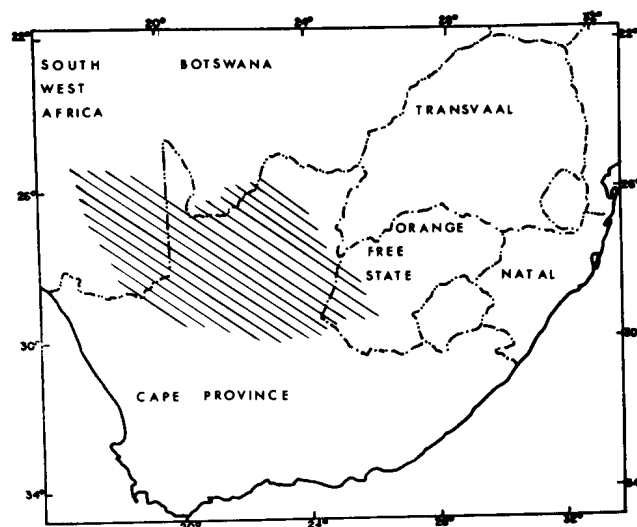


Figure 1 Map of the Republic of South Africa showing the area of origin of wet carcass sheep.

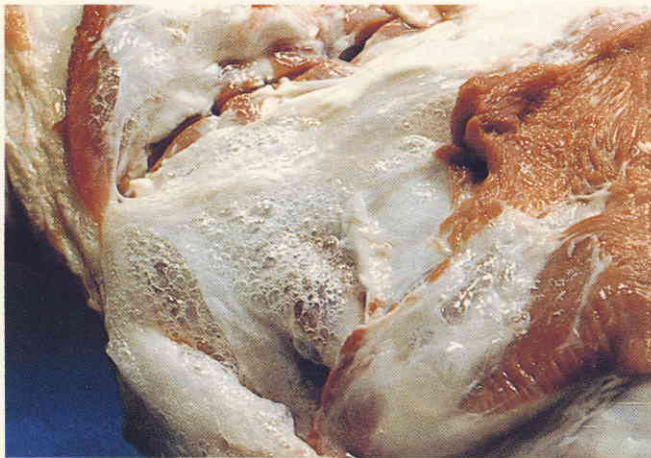markedly between lots from the same farm and averages about 4,5% for the whole area. Wet carcasses occur throughout the year and a few have even been reported on the farms of origin. A large number of wet carcasses were graded Super Lamb and Grade 1, demonstrating that even the best grades are affected.

Clinical pathology

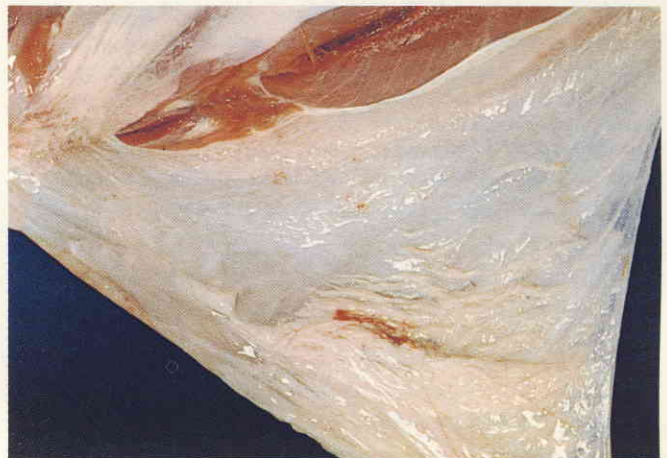This condition cannot be diagnosed in the live animal, therefore analyses of preslaughter blood specimens were correlated with postslaughter findings. Total serum protein, albumin globulin ratio and electrolyte levels of wet carcasses were normal. Liver specimens (kindly analysed by Roche, Switzerland), revealed normal vitamin A levels and significantly higher than normal vitamin E levels for wet carcasses. Interconnective tissue fluid contained less total protein (10 g/l as compared to 45g/l) and relatively more albumin (albumin/globulin ratio of 2,5 as compared to 1,2) than that of normal sheep.

Other investigations

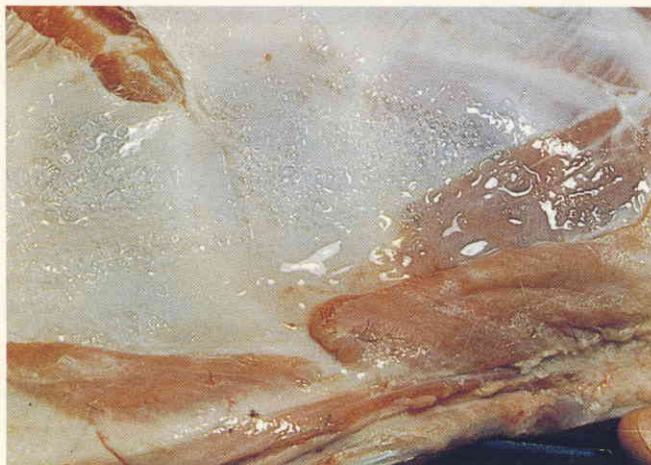At the abattoir, the following possible causes of the syndrome were eliminated: washing carcasses with water



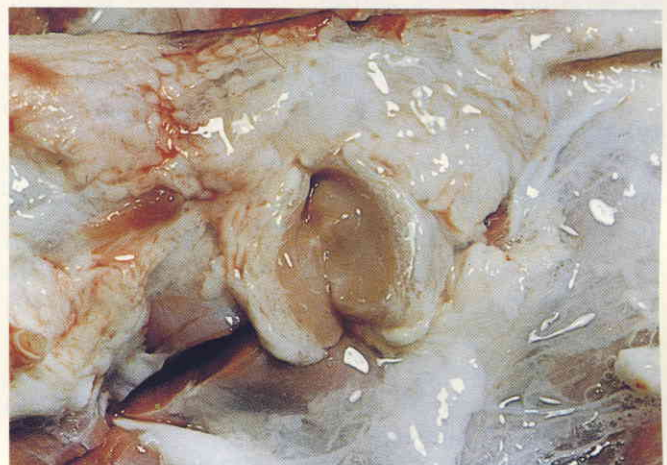
(a) Wet carcass with intermuscular connective tissue layers displayed.



(b) Hindleg with accumulation of watery fluid in subcutaneous tissues.



(c) Watery fluid in flank area.



(d) Subscapular area with fluid accumulation.

Figure 2 Photographs of wet carcasses.

under too high a pressure, faulty cooling systems, feed in the holding pens, and transport stress.

In the high incidence area (see Figure 1), feeding systems varied from feedlots to 100% grazing on grass and shrubs of the Kalahari. Water from these areas was good and very potable. No plants, thought to cause this condition were seen and the vegetation differed widely from farm to farm.

No viral or bacterial organisms capable of causing the condition were isolated.

Apart from the fluid in the loose connective tissue, no other macroscopic pathological lesions could be seen. Histopathological examination, showed no evidence implicating cachexia, inflammatory processes, lymphoedema, cardiac failure, glycogen storage or myxoedema in the pathogenesis of the syndrome.

In conclusion, despite intensive investigation the aetiology of the wet carcass syndrome remains unknown. At present the possibility of a histamine reaction due to insect bites is being investigated using the 'Kalahari sand tampan' (*Ornithodoros savignyi*), since it occurs in the major part of the Gordonia district.