

## Carcinoid heart disease secondary to ovarian tumour: a logical sequence of management?

Sahajanandan R, FRCA, Fellow; Lakshmanan S, FRCA, Consultant; Hester S, FRCA, Consultant  
Norell M, MRCP, Cardiologist; Strouhal P, PMRCP, Radiologist; Murphy D, DMRCOG, Gynaecologist  
Buch H, HMRCP, Endocrinologist; Billing JS, FRCS, Cardiac Surgeon  
Heart and Lung Centre, New Cross Hospital, Royal Wolverhampton Hospitals, Wolverhampton  
**Keywords:** tricuspid valve, pulmonary valve, carcinoid, octreotide  
**Correspondence to:** Raj Sahajanandan, e-mail: rajsahajanandan@gmail.com

### Abstract

There are only few reported cases of carcinoid heart disease caused by ovarian tumours. The main cause of morbidity and mortality in these patients is right heart failure. Most cases of carcinoid heart disease have liver metastases and undergo cardiac surgery, followed by liver resection. Ovarian carcinoids cause heart lesions without liver metastasis. Hence, we managed the primary tumour first under octreotide cover, followed by cardiac surgery with a favourable result.

© Peer reviewed. (Submitted: 2013-03-13. Accepted: 2013-05-29.) © SASA

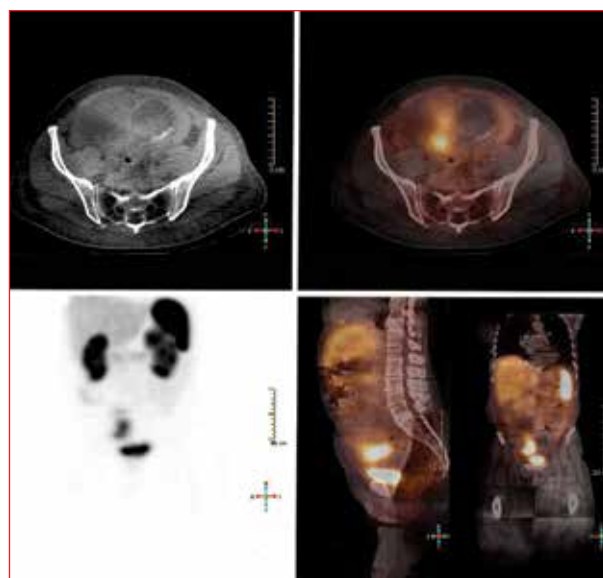
South Afr J Anaesth Analg 2013;19(4):224-226

### Introduction

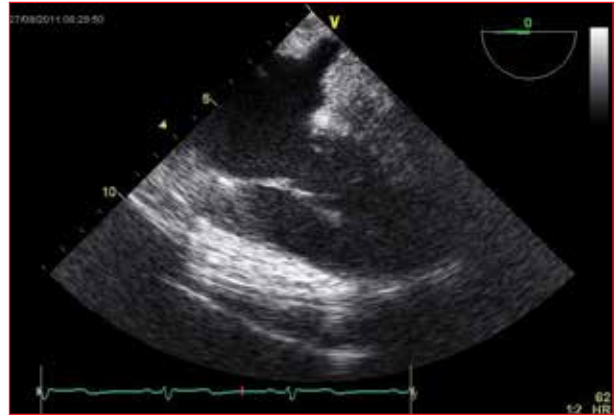
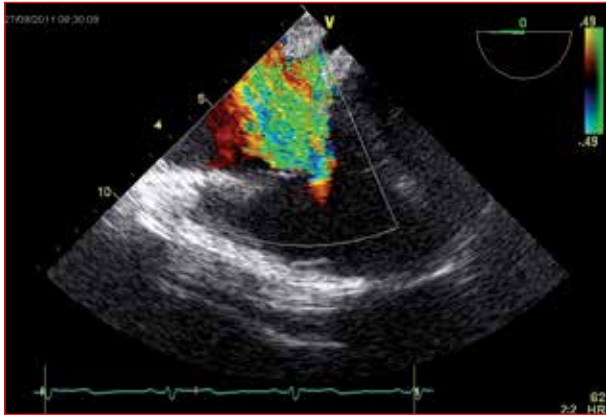
Carcinoid heart disease secondary to ovarian tumours is uncommon. The ovarian carcinoids do not have metastasis in the liver unlike gastrointestinal tumours. Hence the management priorities need to be different. We present a case in which removal of the primary tumour before heart surgery resulted in a successful outcome.

A-69-year old woman presented with a history of weight loss, increased bowel frequency, generalised pruritus and flushing. An examination revealed features of right heart failure. A transthoracic echocardiogram showed severe tricuspid regurgitation and severe pulmonary regurgitation. The severe isolated involvement of right heart valves with the echocardiographic appearances prompted investigations to exclude carcinoid heart disease. The patient's urinary 5-hydroxyindoleacetic acid level (5HIAA) levels were 665 micromol/day (normal is 0-50 mmol/ day), suggesting carcinoid syndrome. Abdominal ultrasound and a computed tomography scan showed a large pelvic mass of 10-15 cm arising from the left ovary, with no evidence of liver metastasis. A preoperative octreotide scan (Figure 1 a-d) confirmed the diagnosis of carcinoid tumour of the ovary, with no evidence of metastasis. She was treated with octreotide, which resulted in a 50% reduction of 5-HIAA levels. Congestive heart failure was optimised with furosemide and spironolactone.

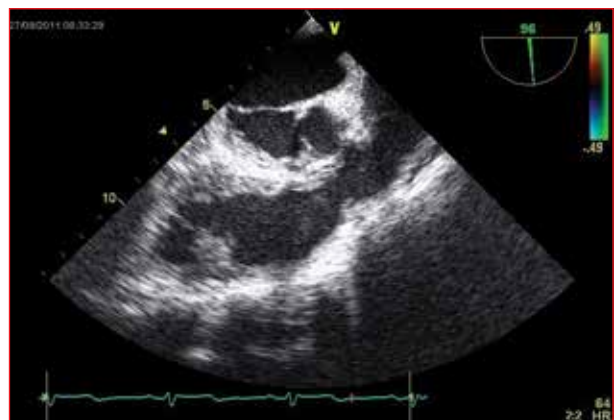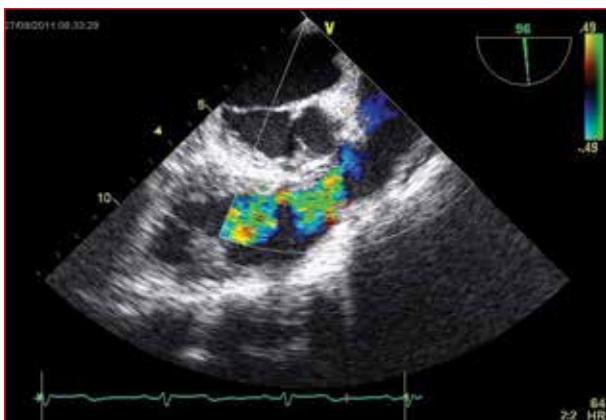
The patient was scheduled for oophorectomy and was electively admitted in the intensive care unit the day before



**Figure 1 a-d:** Octreotide single-photon emission computed tomography. **Figure 1 a:** Computed tomography image showing mixed cystic and mixed solid pelvic mass. **Figure 1 b:** Still in coronal plane from a spinning maximum intensity projection isotope image: normal kidneys, bladder and spleen are seen with low level liver uptake. Uptake that is superior to the bladder is within the pelvis mass. **Figure 1 c and d:** Sagittal and coronal views of fused single-photon emission computed tomography data, all showing the increased isotope uptake centrally in the solid elements of the tumour on the overlying computed tomography images.



**Figure 2 a and b:** Mid-oesophageal four-chamber view, showing fibrosed and destroyed tricuspid valve with severe tricuspid regurgitation



**Figure 3 a and b:** Modified mid-oesophageal long axis view, showing fibrosed and destroyed pulmonary valve with severe pulmonary regurgitation

surgery. Invasive monitoring and an epidural anaesthesia were established preoperatively. She underwent an uneventful trial of positive pressure ventilation [bi-level positive airway pressure (BiPAP)]. An octreotide infusion 50 µg/hour was started 12 hours preoperatively. She was premedicated with hydrocortisone and ranitidine and chlorpheniramine. Surgery was performed in cardiac theatres, with a cardiothoracic team and perfusionist on standby. Anaesthesia was induced with titrated midazolam and etomidate, fentanyl and vecuronium, and maintained with oxygen, air and isoflurane. Apart from normal monitoring, transoesophageal echocardiography (TEE) was inserted to assess cardiac function and guide fluid therapy. A 50 µg bolus of octreotide was given before intubation, and before tumour manipulation. Surgery was performed without incident and the patient had an uneventful recovery.

The histology confirmed a carcinoid tumour within an ovarian cystic teratoma. She made a good recovery with regression of the diarrhoea and pruritus. Octreotide was stopped after three weeks when the urinary 5HIAA levels returned to normal. However, she continued to have New York Heart Association class III dyspnoea, despite maximal medical therapy, even months after oophorectomy. She was admitted for tricuspid and pulmonary valve replacement.

Apart from routine monitoring, a pulmonary artery catheter was inserted. Her pre-bypass TEE revealed severe tricuspid regurgitation with destruction of leaflets (Figure 2 a and b). The right ventricle was dilated, thick (fibrosed) and impaired in function. The pulmonary valve leaflets were destroyed, resulting in severe pulmonary regurgitation (Figure 3 a and b). These findings were comparable to the TEE that was carried out during oophorectomy. The pulmonary valve was replaced with a 23-mm Freestyle® stentless bioprosthesis, inserted as a cylinder up to the level of the pulmonary trunk bifurcation. The leaflets were left in situ in the tricuspid position, and a 27-mm St Jude Epic® bioprosthesis was implanted. The patient was weaned from bypass with the support of milrinone and noradrenaline infusions. Postoperative TEE showed satisfactory replacements of both valves. She made good postoperative recovery and was extubated within four hours. Her subsequent postoperative course was uneventful and she was discharged on the seventh postoperative day.

## Discussion

Carcinoid tumours are rare neuroendocrine tumours that arise from amine precursor uptake and decarboxylase cells.<sup>1</sup> Ninety per cent of these tumours arise from the

gastrointestinal tract. The most common sites are the appendix and terminal ileum.<sup>2</sup> The less common sites are the bronchus and gonads.<sup>2,3</sup> The incidence of carcinoid tumours is 1-2 per 100 000 population,<sup>2</sup> of which 50% develop carcinoid syndrome. Of the patients who develop carcinoid syndrome, 50% will develop carcinoid heart disease, which typically affects the right side of the heart.<sup>2</sup>

Carcinoid syndrome is characterised by flushing, secretory diarrhoea and bronchospasm, and is due to secretory products entering the systemic circulation. The liver normally inactivates these hormones. The venous drainage from gastrointestinal carcinoid tumours is into the portal circulation, so development of the carcinoid syndrome does not generally occur until there are liver metastases.

The most common cardiovascular manifestations of carcinoid heart disease are flushing and palpitations. A potentially serious manifestation is subendocardial fibrosis, which is seen in 60% of patients. This plaque-like thickening typically affects the tricuspid and pulmonary valves, and results in regurgitation and less commonly, stenosis. The valvular lesions, together with endocardial fibrosis, often result in severe right-sided heart failure.<sup>3</sup> The mechanism of the cardiac lesions in carcinoid is unclear, but they are usually caused by paraneoplastic effects of vasoactive substances, like serotonin, histamine, bradykinin and prostaglandin released by liver metastases.<sup>2,3</sup> Rarely, they can cause metastatic disease in the heart. Occasionally, carcinoids can cause valve lesions without liver metastasis when the primary tumour arises in the gonads or bronchus, as they have systemic venous drainage.<sup>3</sup>

Carcinoid tumours are slow-growing tumours. However, the onset of cardiac symptoms heralds a decline in clinical outcome.<sup>2</sup> Surgery is offered to suitable candidates as it has been shown to improve quality of life.<sup>1</sup> It may be advisable to carry out early surgery, as waiting can result in worsening of right heart function, which may increase morbidity.<sup>2</sup>

The perioperative challenges are the risk of carcinoid crisis and right heart failure.<sup>1</sup> Carcinoid crisis can be precipitated by drugs which release histamine, catecholamines, and conditions like hypothermia, hypercapnoea and stress. Stress response to surgery is minimised by the institution of epidural anaesthesia. Use of octreotide has been shown to decrease perioperative haemodynamic instability. Although historically, catecholamines are avoided, the use of these agents in combination with octreotide has been found to be safe, especially in the setting of myocardial depression.<sup>3</sup> TEE is particularly useful in determining the cause of haemodynamic instability.

The institution of positive pressure ventilation is known to cause a reduction in right ventricular preload and an increase in afterload, and could result in right heart failure. However, in our case there were no significant cardiovascular effects during a period of BiPAP, which was used as a preoperative surrogate to assess tolerance to positive pressure ventilation.

The literature shows that most patients have liver metastasis before they present with carcinoid heart disease. Severe hepatic venous congestion, secondary to tricuspid insufficiency, greatly increases the operative risk of liver resection in such patients, and they often undergo corrective cardiac surgery under octreotide cover. However, our patient had an ovarian primary tumour, without involvement of the liver. We removed the tumour first as we felt that the carcinoid-related risks were lower in an operation that did not involve cardiopulmonary bypass. A multidisciplinary approach, meticulous planning, octreotide cover and appropriate perioperative monitoring helped us to manage this situation. Our strategy resulted in normalisation of urinary 5HIAA levels and we could perform the cardiac surgery without the risk of carcinoid crisis and haemodynamic instability.

There have been anecdotal reports on regression of carcinoid heart disease after resection of an ovarian primary tumour.<sup>4</sup> However, our patient had persistent severe symptoms of right heart failure, even three months after resection of the primary tumour. Therefore, we decided to perform cardiac surgery for both symptomatic and prognostic reasons.

Prosthetic valves may potentially be affected by a carcinoid, resulting in valve failure and mortality.<sup>5</sup> We were able to avoid this risk as the primary tumour was removed before the cardiac surgery. We believe that removal of the primary tumour, followed by cardiac surgery, has the most rational sequence in managing carcinoid heart disease secondary to ovarian tumour.

## References

1. Deegan RJ, Furman WR. Cardiovascular manifestations of endocrine dysfunctions. *J Cardiothorac Vasc Anesth*. 2011;25(4):705-720.
2. Fox DJ, Khattar RS. Carcinoid heart disease- presentation diagnosis and management. *Heart*. 2004;90(10):1224-1228.
3. Castillo JG, Filsofi F. Management of patients undergoing multivalvular surgery for carcinoid heart disease. Role of anaesthetist. *Br J Anaesth*. 2008;101(5):618-626.
4. Gonsalez O, Alberca MT. Echocardiographic diagnosis of carcinoid heart disease. Exceptional evolution after ovarian tumour resection without cardiac surgery. *Eur J Echocardiogr*. 2006;8(6):497-500.
5. Ohri SK, Schofield JB. Carcinoid heart disease. Early failure of an allograft valve replacement. *Ann Thorac Surg*. 1994;58(4):1161-1163.