

Intraoperative neurophysiological monitoring for the anaesthetist

Part 1: A review of the theory and practice of intraoperative neurophysiological monitoring

Van Der Walt JJN, MBChB, DA(SA), Registrar

Department of Anaesthesia, Red Cross War Memorial Children's Hospital; University of Cape Town, Cape Town

Thomas JM, BSc, STD(Edu), MBChB, FCA(SA), Associate Professor and Head

Paediatric Anaesthesia, Red Cross War Memorial Children's Hospital, University of Cape Town, Cape Town

Figaji AA, MBChB, MMedFCS, PhD, Professor and Head

Paediatric Neurosurgery, Division of Neurosurgery, University of Cape Town, Cape Town

Correspondence to: Johan van der Walt, e-mail: johanvanderwalt07@gmail.com

Keywords: evoked potentials, intraoperative monitoring, brain mapping

Abstract

Intraoperative neurophysiological monitoring (IONM) has become the gold standard for the monitoring of functional nervous tissue and mapping of eloquent brain tissue during neurosurgical procedures. The multimodal use of somatosensory-evoked potentials and motor-evoked potentials ensures adequate monitoring of anterior sensory and dorsal motor pathways. The use of IONM during spinal orthopaedic surgery has drastically reduced the incidence of postoperative neurological deficit and allowed radical resection of brain tumours. Evoked potentials (EPs) are analysed for increased latency (> 1 millisecond) and decreased amplitude (< 50%). Special considerations have to be made in the paediatric population who present with decreased myelination and morphological changes to the EPs. A thorough knowledge of the physics and physiology behind these techniques will ensure better outcomes and successful implementation in neurosurgical centres. In this two-part article series, we will provide a review of the most recent available literature on IONM. The different modalities that are available, their indications and application are presented in Part 1, while the different anaesthetic options that exist will be discussed and the basic approach to the planning of a successful anaesthetic outlined in Part 2.

© Peer reviewed. (Submitted: 2012-11-15. Accepted: 2013-04-24.) © SASA

South Afr J Anaesth Analg 2013;19(3):139-144

Introduction

Since the early 1990s, the rapid development of neuroimaging and neuronavigation techniques has enabled the neurosurgeon and spinal orthopaedic surgeon to embark on ever-more daring surgeries to correct spinal deformities, resect spinal tumours and burrow into the depths of the brainstem to preserve function and save lives. Functional neurophysiological assessment during spine and spinal cord surgery began in the 1970s with the use of somatosensory-evoked potentials (SSEPs), and, with the addition of corticospinal motor pathway monitoring with motor-evoked potentials (MEPs), has progressed to multimodal use. This allows for more complete monitoring of posterior sensory and anterior motor tracts, and creates a safe and reliable environment for intraoperative neurophysiological monitoring (IONM). IONM could soon become a medico-legal requirement, and satisfy the demand for safe and low-risk surgery from the patient, family and surgical team.¹ In South Africa, although spinal and neurosurgery takes place on a daily basis in various centres around the country, the

use of IONM is still uncommon, and if practised, does not always adhere to the guidelines set out by the international community. Because postoperative neurological deficit is likely if MEPs are absent for more than five minutes, the ability to monitor motor potentials reliably and effectively is critically important.² These reviews aim to inform the anaesthesiologist of the different IONM modalities, and to indicate how the anaesthetic approach may impact on the quality of the evoked potential waveform. The article also aims to help develop a standard of care in South Africa, as well as to inform practitioners of current international standards and consensus on best practice for the perioperative management of patients who require IONM.

Value

IONM is used during complex surgery that involves motor and sensory cortices, the brainstem and cranial nerves, the spinal cord, nerve roots, peripheral roots, brachial and lumbar plexuses, as well as the peripheral nerves. Monitoring of the SSEPs and MEPs during surgery allows for timely

intervention by the surgeon to avoid neurophysiological injury. Mapping and monitoring are two different aspects of IONM. Mapping involves the application of an electrical stimulus directly to brain, brainstem, spinal cord or nerves, to elicit a distal motor response, the aim of which is to identify the position of eloquent tissue. Monitoring is used to continuously or semi-continuously monitor the integrity of the full motor or sensory pathway, while working on the part of that pathway that places the whole system at risk.

Because of incomplete central and peripheral myelination, the paediatric neuroanatomy provides a challenging realm for interpretation of these evoked potentials (EPs). Also, permanent injury may occur from retraction, vigorous suction, thermal injury, and even low blood pressure, when the tissue is distorted and already ischaemic. Early recognition of this, and intervention, may prevent a temporary disturbance from becoming a permanent one. Without electrophysiological data, the health of these pathways during surgery is unknown. This requires the presence of an experienced and knowledgeable neurophysiologist or clinician trained in IONM to guide and advise the surgeon on management.²

The initial use of SSEPs is supported by a multicentre study on scoliosis by Nuwer et al. This study compared the outcomes of patients undergoing scoliosis surgery. The use of somatosensory potential monitoring yielded a false negative predictive rate of 0.063%, with a greater reduction in neurological deficits for monitoring teams with more somatosensory potential monitoring experience.² In the same study, false positive results for SSEPs were 0.983%, or 504 patients, which is additional evidence that SSEPs are valuable, but not always sufficient, when monitoring the corticospinal of the spinal cord.³ Meyer et al showed a decrease in neurological injury rate from 6.9% to 0.7% with SSEP monitoring in patients undergoing spinal stabilisation after trauma.⁴

These studies, especially scoliosis studies, are the tip of the iceberg, given that the risk of a neurological deficit is very low. The risk is much higher in other direct surgery on the brain and spinal cord, and so the value of IONM correspondingly rises substantially.

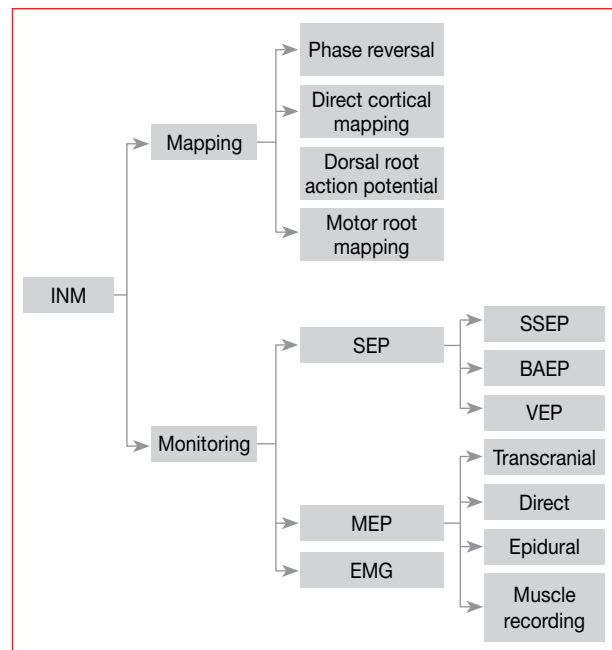
In more recent years, numerous studies have proven multimodal IONM with combined SSEPs and MEPs to be more accurate and to lead to fewer false negative results. SSEPs alone lack specificity for motor pathways, but also rely on averaging techniques, which lead to delays in signal processing.⁵ This is not surprising, given that the motor and sensory systems are independent of each other, although they may be influenced by similar, but not all, factors. SSEPs are also more sensitive to volatile anaesthetics, and patients with pre-existing spinal cord pathology have a low quality of SSEP.⁶ The use of multimodal EPs in orthopaedic

spinal surgery has also replaced the use of the Stagnara wake-up test (testing the integrity of the motor pathways by waking the patient during surgery and requesting foot flexion and extension) in young patients, as well as mentally retarded and uncooperative patients.

Modalities

Depending on the surgical demands, two techniques of IONM are used, i.e. monitoring and mapping techniques. Monitoring techniques include all the continuous functional assessment of the neural pathways and structures. Data are monitored on an ongoing basis, and compared with data at the beginning of surgery, but after induction of anaesthesia.⁵ Mapping techniques aim to identify neural structures accurately in order to avoid injury and identify impaired tissue by stimulation.²

Figure 1 includes a summary of IONM modalities.



BAEP: brainstem auditory-evoked potentials, EMG: electromyography, IONM: intraoperative neurophysiological monitoring, MEP: motor-evoked potentials, SSEP: somatosensory-evoked potentials, VEP: visually evoked potentials

Figure 1: Summary of intraoperative neurophysiological monitoring modalities

Monitoring

EPs measure the electrical potentials produced in response to stimulation of the nervous system. SSEPs are produced by eliciting an electrical signal distally, while recording the reception of that signal by scalp electrodes placed over the sensory cortex area. For SSEPs, this involves eliciting the signal over peripheral nerves, usually median for the arms and posterior tibial for the legs. SSEPs are pathway specific, stimulus specific and event related. Their amplitude is much smaller than the electroencephalography (EEG) amplitude and therefore requires computer averaging to extract SSEPs

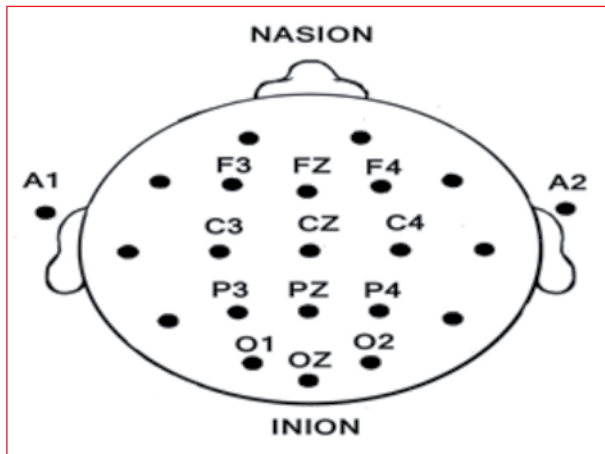


Figure 2: Electrode placement according to the international Ten-Twenty electrode placement system⁷

from background EEG noise.⁴ During spinal surgery, SSEPs assess the function of the dorsal ascending sensory tracts, whereas MEPs elicit a signal over the motor nuclei and record the signal in corresponding muscle groups. Typically, this can be achieved by eliciting the signal through an intact scalp (transcranial MEPs), or directly from the brain during a craniotomy.

As a subgroup, SSEPs consist of many different types of EPs. These include SSEPs that are used during spinal surgery, brainstem auditory-evoked potentials (BAEPs) for posterior fossa and cranial surgery, and visually evoked potentials (VEPs) that are recorded during operations that involve the optic nerve and cranial base surgery. However, VEPs are losing popularity because of the dampening effect of general anaesthesia on amplitude and latency. "Near-field" SSEPs are recorded from electrodes placed near the neural generator of the evoked potential, e.g. the cortical SSEP recorded from scalp electrodes. "Far-field" SSEPs are EPs that arise in peripheral nerves and subcortical structures recorded from scalp electrodes (Figure 2). These evoked potential amplitudes are smaller, require longer times for averaging, and are more affected by general anaesthesia.⁴

Facial nerve monitoring is also increasingly used by ear, nose and throat and plastic surgeons for resection of tumours that affect at-risk areas. Electromyography (EMG) monitors record action potentials from electrodes placed in the orbicularis oris and orbicularis oculi muscles, and are seen on an oscilloscope screen or played through an audio system.⁴ Cranial nerve function can also be mapped and monitored. Corticobulbar monitoring involves stimulation of the motor cortex transcranially over the face area of the homunculus, and detecting the signal in electrodes placed in the facial muscles, masseter, eye muscles, tongue and soft palate. Wraparound electrodes on the endotracheal tube can detect signals over the vocal cords. Free-running EMG is a very basic manoeuvre that has been used for

decades to monitor spontaneous electrical activity in the facial nerve, but is less sensitive than corticobulbar EPs.

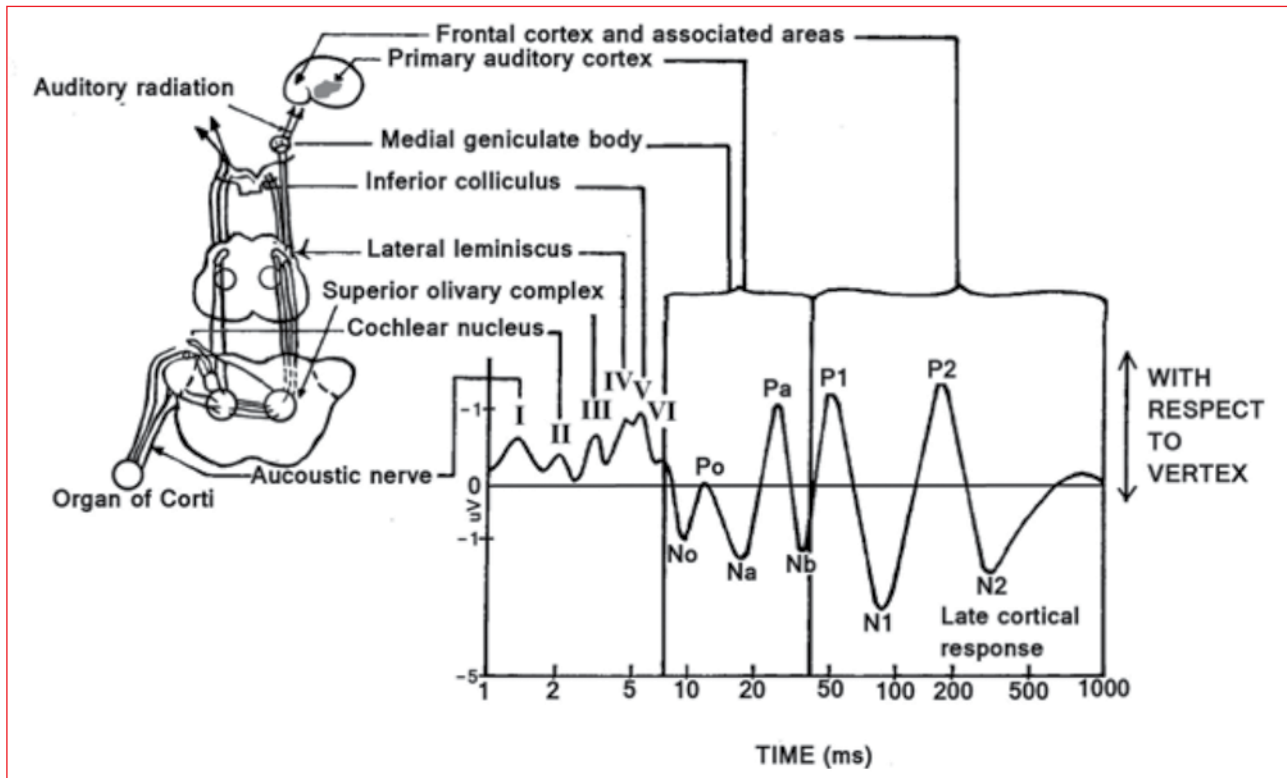
Mapping techniques help the surgeon to preserve function during resection of supratentorial tumours in eloquent brain areas, and to follow motor tracts deep in the brain throughout the internal capsule.⁵ Direct cortical and subcortical mapping with biphasic square wave pulses is often used. However, the motor cortex is relatively unexcitable in children under five years of age. The phase-reversal technique may be helpful in determining the central sulcus between the motor and sensory strips on the cortex. This is used as an alternative mapping technique in these children.⁵ Other mapping techniques include dorsal root action potential mapping, dorsal column mapping and motor root mapping. Direct cortical mapping involves awake craniotomy, but this is not feasible in children.

Preoperative assessment with functional magnetic resonance imaging, magnetoencephalography and positron emission tomography studies allows for mapping of the cortical areas, but these remain inadequate for making critical intraoperative surgical decisions. Most clinicians rely on direct stimulation as the gold standard.

The use of biphasic square wave pulses as a mapping technique requires a generous craniotomy in order to increase the chances of a positive mapping result.⁵ Negative stimulation mapping does not always ensure safety, and can be due to muscular paralysis and hypotension. This technique might also be epileptogenic.⁵ Sartorius et al showed that the incidence of intraoperative simple partial seizures during brain mapping ranged from 5-20%, despite the use of anticonvulsants, and found them to be unrelated to a preoperative history of intractable epilepsy.⁵ The use of transcranial or direct cortical multipulse electrical stimulation allows for a combination of monitoring and mapping techniques with a lower risk of inducing seizures.⁵ However, this risk is dependent on the technique that is used and can be significantly reduced. If adequate preparation is made, there is little risk of a clinical problem occurring.

Indications

The indications for IONM depend on the availability of equipment, and more importantly, the expertise to interpret the EPs correctly. Monitoring guidelines have been documented by the American Electroencephalographic Society, American Academy of Neurology⁴ and the International Society for Intraoperative Neurophysiology.³ Priorities should be defined by any institution's scientific, economic and medico-legal position.⁵ With overwhelming evidence for improved neurological outcome after brain and spinal surgery, it is only a matter of time before IONM is considered to be a medico-legal requirement for spinal orthopaedic and neurosurgical management of at-risk brain and spinal procedures. IONM should be considered to be mandatory whenever the expected neurological



The symbols above the waves represent the standard electrophysiological nomenclature.⁴ Note the short-latency evoked potentials (< 10 milliseconds) from the brainstem structures. These are the most reliable, since they are less affected by general anaesthesia and physiological changes

Figure 3: Neuroanatomical correlates of the auditory-evoked response⁸

complication is determined by a known pathophysiological mechanism that can only be prevented by IONM.⁵

Some of the most common indicated paediatric neurosurgical procedures for IONM include:

- Brain surgery in the central region, and along the subcortical motor pathways.
- Posterior fossa and brainstem surgery.
- Spinal cord surgery.
- Conus-cauda surgery, e.g. tethered cord syndrome and tumour resection.
- Rhizotomy for relief of spasticity.⁵
- Resection of intramedullary and extramedullary tumours.
- Functional disturbance of the cauda equina and/or individual nerve roots.¹

In spinal orthopaedic surgery, the use of IONM during scoliosis surgery has been found to be especially useful. The incidence of neurological complications associated with the placement of pedicle screws has been noted to be as high as 11%.⁵ The European consensus group on spinal surgery recommended the following pathologies as indications for the use of IONM:

- Correction of spinal deformities with scoliosis greater than 45 degrees.
- Correction of congenital spine anomalies.
- Extensive anterior and posterior decompression in spinal stenosis, and cervical, thoracic and lumbar spine lesions, causing myelopathies.

The same consensus group agrees, that, with the current available modalities, the Stagnara wake-up test to monitor the correction of spinal deformities should be regarded as obsolete.¹

Clinical application

EPs are described in terms of post-stimulation latency in milliseconds. This is the time between the application of the stimulus and the occurrence of a peak in the EPs waveform. The peak-to-peak amplitude of individual waveforms is also monitored in millivolts or nanovolts.⁴ The specific peaks and waves of the EPs waveform correlate with specific neural generators⁴ (Figure 3). The short-latency EPs of the BAEPs (< 10 milliseconds) correlates with brainstem structures, mid-latency EPs with subcortical structures and long-latency EPs (> 100 milliseconds) with cortical structures. The short-latency EPs are used more often intraoperatively because they are less affected by anaesthetic depth. Activity arising in the cerebral cortex, subcortical structures, cranial nerve, spinal cord, nerve root, plexus and peripheral nerves can be recorded noninvasively from electrodes fixed to the skin or scalp. The location of the electrodes is placed according to the international Ten-Twenty electrode placement system (Figure 2). A significant change in EPs is defined as a change in latency > 1 milliseconds or a decrease in amplitude of > 50%.

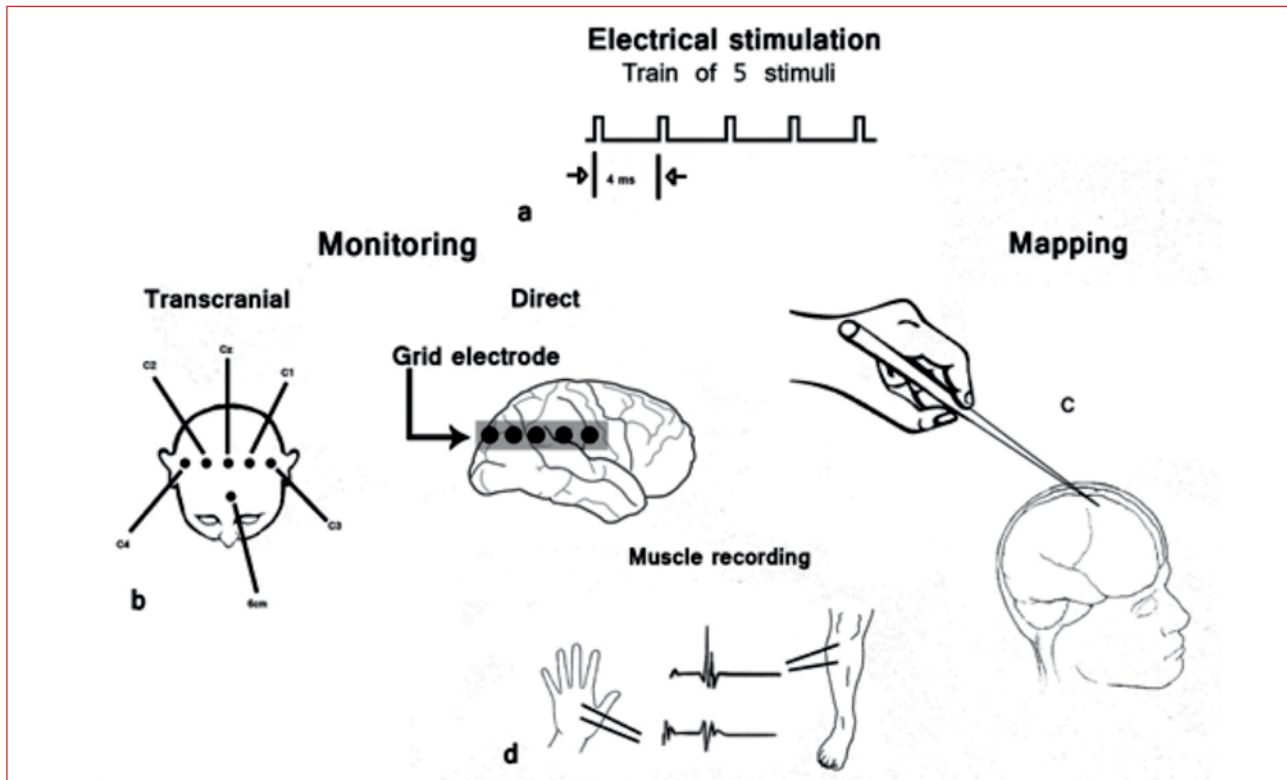


Figure 4 a-d: Motor-evoked potentials for brain surgery⁹

a: Electrical stimulation with multipulse train of 5 technique and interstimulus interval of 4 milliseconds b: Transcranial stimulation or direct cortical stimulation

c: Direct cortical stimulation using a hand-held monopolar probe as a cortical mapping technique d: Recording of motor-evoked potentials from the controlateral thenar and tibialis anterior muscles

During SSEP, a square wave stimulus of 0.2- to 2-millisecond duration is delivered to a peripheral nerve (mixed motor and sensory nerve) and the intensity is adjusted to produce a minimal muscle contraction (motor threshold) at 2-3 Hz.

The common sites of stimulation are the median nerve at the wrist, the common peroneal nerve at the knee and the posterior tibial nerve at the ankle. The pudendal and trigeminal nerve, as well as the tongue, have also been studied.⁴ Recording electrodes are placed over the popliteal fossa, cervical spine and the vertex.³ Because of the sensitivity of the cortical responses to anaesthetic depth, direct stimulation or recording techniques of the spinal cord have been developed. These are less sensitive to anaesthetic effects. Recent studies have demonstrated that epidural recording and stimulation is superior to peripheral nerve stimulation because it can record well-defined responses.⁴ The induction of anaesthesia causes a large variability in EP because of physiological changes, as do bolus doses of anaesthetic drugs. Baseline EPs should be obtained after induction and compared with ongoing responses elicited throughout the procedure.³

BAEPs are less sensitive to intraoperative changes and are easier to monitor. They can be divided into transient and steady-state potentials. Transient BAEPs represent the processes of transduction, transmission and processing of auditory information from the cochlea to the brainstem, primary auditory cortex and frontal cortex. They are recorded

with an electrode placed on the mastoid or ear, with a reference electrode at the top of the head and a ground electrode on the forehead. Ear headphones deliver a series of clicks at 1 000-4 000 Hz to each ear intraoperatively, while changes in the amplitude and latency of the EPs (mostly short-latency EPs representing brainstem structures), are monitored.⁴

Because of a lack of consistency and the effect of general anaesthesia, VEPs are of limited use intraoperatively. VEPs are recorded after visual stimulation with flashing light-emitting diode goggles, or smaller stimulators, such as scleral caps or contact lenses. Some authors believe VEPs to be of value in skull base surgery.⁴ A normal VEP consist of two positive peaks at 100 milliseconds and 200 milliseconds observed after a 1-3 Hz flash stimulation of 3-5 milliseconds duration. Optic neuritis and lens defects, like cataracts, can also affect the quality of responses.⁴

The peripheral responses of MEPs are recorded by measuring compound muscle action potentials (CMAPs) over muscles innervated by the motor nerve with surface electrodes, or within muscles with fine wire electrodes after stimulating the nerve in the operative field.⁴ Neurogenic MEPs are recorded transcranially or by direct stimulation of the spinal cord, with electrodes placed in vertebral bodies cephalad to the surgical site. Pure motor-tract monitoring can be achieved by motor cortex stimulation using transcranial electrical or magnetic stimulation. Responses are recorded

in the spinal cord, the peripheral nerve, or as CMAPs. The use of epidural recordings prevents the anaesthetic effect on anterior horn cells and neuromuscular junctions from interfering with the motor response in the nerve. The most frequently used intraoperative MEP modality is transcranial electrical stimulation (TES).² It involves TES over the motor cortex using a train of 3-7 stimuli, while recording CMAPs from the limbs (Figure 4). EEG corkscrew electrodes are often used and placed over the motor cortex on the international 10/20 EEG system. These electrodes prevent displacement during surgery and decrease impedance over the scalp. However, care should be taken in children with open fontanelles, typically those who are < 18 months and with an open ventricular-peritoneal shunt. EEG disk electrodes may be used in these cases.² Recording electrodes are placed in appropriate muscle groups that have a large cortical spinal tract distribution.

Electromyographic monitoring with recording of those muscles innervated by lumbar and sacral nerves is performed during surgery with potential injury to these structures, such as tethered spinal cord and conus level operations. It includes monitoring of the S1 and S2 nerve roots at the anal sphincter. EMG potentials are monitored and when nerve root irritability arises, bursts of discharges, or high-frequency single, double or multiplex discharges can be observed. When these discharges are seen, the surgeon may need to limit the area of surgical manipulation.²

Issues in paediatrics

The nervous system is still relatively immature below three years of age. This leads to morphological changes of the EP waveform, requiring expert neurophysiologist review. Stimulation parameters that are used for cortical mapping in adults may be inadequate in cortical stimulation in young children.⁵ The excitability of the motor cortex in young children makes bipolar 60 Hz stimulation less reliable for cortical mapping.⁵ Issues with regard to placement of electrodes and types of electrodes must be borne in mind, as well as an understanding of certain surgical procedures that are performed more frequently in children, such as tethered cord release, lipoma and myelomeningocele. The Stagnara wake-up test is no longer appropriate for use in very young children and in mentally challenged patients.¹ The use of MEPs in these children should become a mandatory part of surgical management to identify early neurological injury.³

Conclusion

Very few specialist centres in South Africa employ the use of dedicated intraoperative neurophysiologists for IONM,

and currently only one training centre exists. However, their presence in European and American spinal and neurosurgical units is becoming mandatory. The current body of evidence will necessitate tertiary institutions in South Africa to develop training facilities and enrol candidates to fulfill the role of neurophysiologists. Currently, these individuals are either neurologists, neurosurgeons, neuroscientists or neuroanaesthetists who have been specifically trained in IONM.⁵ In future, all neurophysiologists may be required to be medical doctors themselves. The medico-legal implications and coverage that these individuals will require, will need to be appropriately adjusted. The advantages to be gained from implementing IONM will have to be recognised by the relevant surgical disciplines, and anaesthetic management during these procedures will need to be tailored to enable the surgeon and neurophysiologist to make accurate and timely intervention possible. However, it must be emphasised that there is no place for IONM to be carried out by those who are not thoroughly trained in its use, and with the requisite experience. Apart from the direct harm that this may cause in the operating room, major risks include inappropriate monitoring being conducted for specific pathologies, as well as misinterpretation of signals that leads to potentially disastrous advice being given to the surgeon. This may harm the patient and increase the medico-legal risk.

References

1. Sutter M, Deletis V, Dvorak J, et al. Current opinions and recommendations on multimodal intraoperative monitoring during spine surgeries. *Eur Spine J.* 2007;16 Suppl 2:S232-S237.
2. Galloway GM, Zamel K. Neurophysiologic intraoperative monitoring in pediatrics. *Pediatr Neurol.* 2011;44(3):161-170.
3. Deletis V. Intraoperative neurophysiology and the motor-evoked potentials methodology. *US Neurology.* 2008;4(1):73-74.
4. Kumar A, Bhattacharya A, Makhija N. Evoked potential monitoring in anaesthesia and analgesia. *Anaesthesia.* 2000;55(3):225-241.
5. Sala F, Krzan MJ, Deletis V. Intraoperative neurophysiological monitoring in pediatric neurosurgery: why, when, how? *Childs Nerv Syst.* 2002;18(6-7):264-287.
6. Deletis V. Basic methodological principles of multimodal intraoperative monitoring during spine surgeries. *Eur Spine J.* 2007;16 Suppl 2:S147-S152.
7. Jasper HH. The Ten-Twenty electrode system of the international federation. *Electroencephalography and Clinical Neurophysiology.* 1958;10:371-375.
8. Thornton C, Newton DEF. The auditory evoked response: a measure of depth of anaesthesia. *Bailliere's Clinical Anaesthesiology.* 1989;3:559-585.
9. Kothbauer K, Deletis V, Epstein FJ. Intraoperative neurophysiological monitoring. In: Crockard A, Hayward R, Hoff JT, editors. *Neurosurgery: the scientific basis of clinical practice.* 3rd ed. Oxford: Blackwell Science, 2000; p.1042.