

Anaesthesia and Pentalogy of Cantrell

Adrian Bösenberg

Department of Anaesthesia, University of Cape Town, Cape Town, South Africa

Patient summary

A two day old, 2.2 kg male was referred for further management and closure of a large exomphalos (Figure 1). The defect, which initially contained part of the heart, had been diagnosed by ultrasound in utero. The pregnancy was uncomplicated. He had been delivered by elective C-section at the referral hospital. Initial Apgars were low (5 and 7) and he was intubated because of poor respiratory effort. Decreased breath sounds were noted bilaterally. Hypoplasia of both lungs was suspected on the chest x-ray (Figure 2). He remained in respiratory distress and was stabilised before transfer. In addition to the large exomphalos, a prominent cardiac pulsation was noted in the epigastrium "as if the heart was subcutaneous" and the sternum was described as short. The ears were low set and rotated posteriorly. A neck swelling was noted on the right side.

Soon after arrival in the intensive care unit, ventilation became difficult. A blocked endotracheal (ET) tube was sus-

pected. The ET tube was replaced but there was no improvement. Further desaturation and bradycardia ensued. Although air entry was poor bilaterally it was thought to be worse on the right. The exomphalos made assessment of the epigastrium difficult and no hepar was palpable. With further deterioration, ongoing bradycardia and absent peripheral pulses a pneumothorax was suspected. Before a chest x-ray could be taken to confirm the suspicion, a right thoracocentesis was performed. Air was released under tension but the baby remained

Figure 2: Chest X-ray showing crowded ribs suggestive of underlying pulmonary hypoplasia and an abnormal cardiac shadow. The sternal defect is not visible.

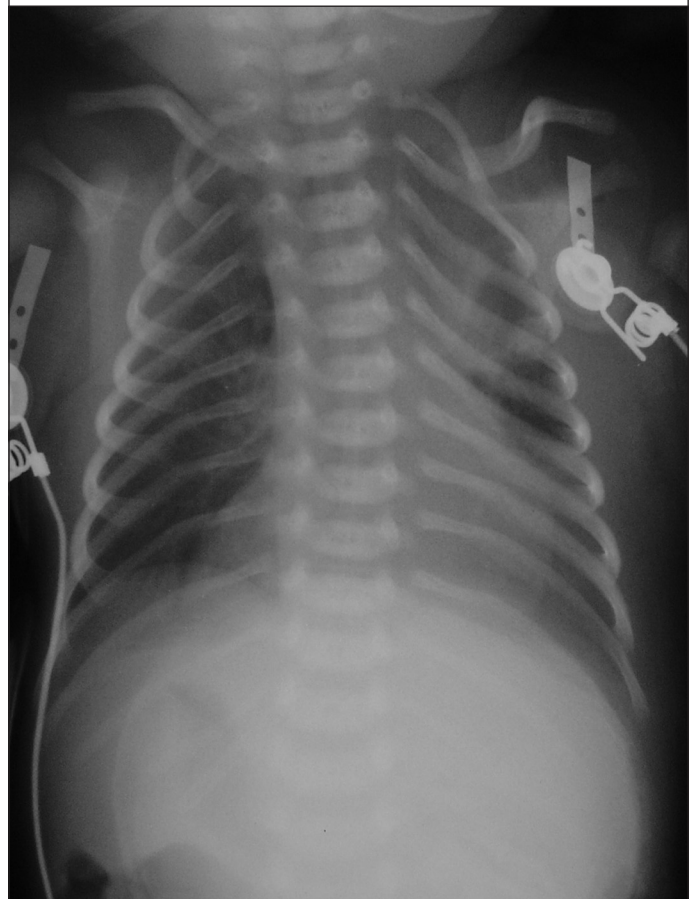
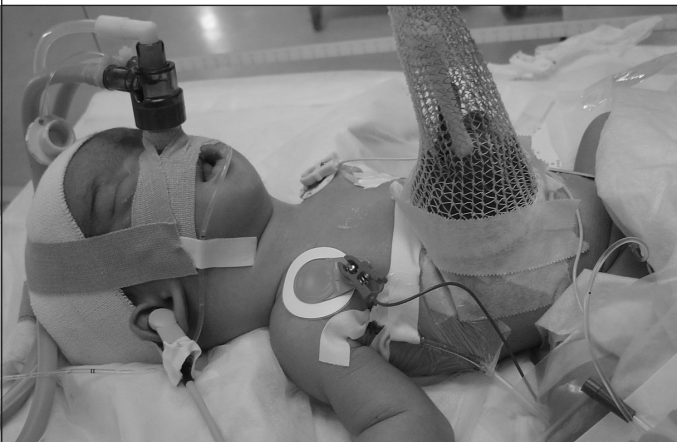


Figure 1: Neonate with an obvious exomphalos (suspended to reduce the pressure on the abdominal contents) requiring ventilatory support for pulmonary hypoplasia. A cystic hygroma is present on the right side of the neck.



Correspondence:

Prof Adrian Bösenberg
email: bosie@cormack.uct.co.za

difficult to ventilate with minimal improvement. Air entry on the left was significantly less than on the right. A left thoracocentesis released air under tension and the infant stabilised rapidly after two doses of intravenous adrenaline to his pre-referral status. At this stage bilateral pneumoscrotum was noted.

Evaluation for the associated anomalies suggested a pentalogy of Cantrell and in view of the pulmonary hypoplasia it was decided to treat the exomphalos conservatively. The ultrasound of the head and kidneys was normal. Echocardiography was difficult and a VSD could not be excluded. The subsequent course in intensive care was stormy, and characterised by profound hypercapnia ($p_a\text{CO}_2$ 7.8kPa) and difficulty with ventilation. High frequency oscillation proved the only method of ventilation that could achieve relative normocarbica. The baby died in ICU 10days after admission.

PENTALOGY OF CANTRELL

Pentalogy of Cantrell¹ is a complex thoraco-abdominal wall defect. Characteristically the abnormality has five components: a supra-umbilical abdominal wall defect; a lower sternal defect; an anterior diaphragmatic defect; a diaphragmatic pericardial defect and a cardiac defect. All these defects may individually be life threatening. Varying degrees of incomplete expression have been described.²

Carmi et al³ described a similar malformation syndrome mostly confined to males, not unlike the neonate described above, which included ventral and diaphragmatic hernias, hypoplastic lungs and cardiac anomalies. These malformations are grouped together under the synonym – Thoraco-abdominal syndrome (TAS).

TAS is thought to be due to a ventral midline developmental field defect⁴ involving a fault in embryogenesis between 14 and 18 days post conception. It is postulated that the lateral mesodermal folds fail to migrate to the midline, causing sternal and abdominal defects, and failure of the septum transversum to develop, causing defects in the anterior diaphragm and pericardium.^{1,5}

Incidence

Pentalogy of Cantrell is an extremely rare disorder but should be excluded in any child born with an exomphalos, especially one that tends to lie above the umbilicus. Inheritance is thought to be X-linked dominant (gene locus Xq25-q26.1)³ but sporadic mutations may occur. The malformation syndrome was first described by Cantrell in 1958.¹ The incidence is in the order of 1:200000 live births and only 90 odd cases have been described in the modern literature. The author has seen two cases (unreported) in two decades of paediatric anaesthesia.

Prenatal ultrasound diagnosis is possible. The size and position of an anterior abdominal wall defect, its contents, and its association with other anomalies are features that are sought. However, the defects range from subtle to severe, and thus the ability to make the diagnosis varies. Even at birth the full extent of the syndrome may not be apparent.⁵

Surgery

Surgical repair of the defect is complex and requires a multidisciplinary approach. It is often difficult because of the poorly developed thoracic cage and the inability to enclose the ectopic heart. Early surgical intervention is important in

order to minimise the risks of spontaneous rupture, arrhythmias and thrombus formation in the ventricular appendage.⁶ Similarly, closure of the exomphalos will reduce the risk of infection and early fluid loss.

Closure of each defect may severely compromise the function of the underlying organ. The complexity of the defect usually dictates a staged surgical approach, particularly in those with multi-organ involvement. Anaesthesia can be a major challenge.⁷

Anaesthetic considerations

- **Abdomen:** The abdominal defect is the most obvious, and comprises an exomphalos which is often positioned more cephalad than usual. Closure of the exomphalos may cause herniation of the abdominal contents through the diaphragmatic defect and pericardial defect which may compromise cardiac and respiratory function. In the absence of a diaphragmatic hernia, high intra-abdominal pressures will splint the diaphragm and compromise respiratory function. High intra-abdominal pressures may also compromise renal perfusion and function. This is particularly important if renal abnormalities (horseshoe kidney, renal agenesis) are present.
- **Respiratory function** may be compromised for a number of reasons. Pulmonary hypoplasia with or without a diaphragmatic hernia may be present. In these patients pulmonary inflation pressures must be kept as low as possible so as to reduce the risk of a pneumothorax. High frequency oscillation may be the most suitable mode of ventilation. The failure of the sternum to fuse may, in its severest form, result in ectopia cordis or a cosmetic defect in its mildest form. The defect is usually mild involving the xiphisternum only. The thoracic cage may be hypoplastic.
- **Cardiac function:** Apart from ectopia cordis, which is the severest form of the malformation, a number of intracardiac defects may be present. These include ventricular or atrial septal defects, tetralogy of Fallot, and classically a left ventricular diverticulum or appendage. The pericardium may be absent anteriorly.

Closure of either the abdominal wall, sternal, diaphragmatic or pericardial defect may severely compromise cardiac function and output. This must be carefully monitored throughout the surgical closure. Surgeons in their enthusiasm may not realise the disastrous consequences of a tight closure.

- **Airway:** Intubation may be challenging in some. The presence of other midline defects such as orofacial clefts, cleft lip or palate or of a cystic hygroma involving the oropharynx have all been described.
- **Other isolated anomalies:** A host of isolated anomalies have been described in association with Pentalogy of Cantrell. These range from renal (agenesis or horseshoe kidney) to cranial and facial anomalies (hydrocephalus, anencephaly, orofacial clefts). Most of these may be obvious but should be investigated when indicated.

Chromosomal defects

An important consideration when an ultrasound diagnosis has been made or when surgery is envisaged are chromosomal defects. Chromosomal analysis should be performed to exclude trisomy 18⁹, trisomy 13 and Turners syndrome. All have been reported in association with this syndrome.¹⁰

Prognosis

Overall the prognosis is dismal and is related to the severity of the defects. Three of Cantrell's five patients survived but none had true ectopia cordis.¹ Toyama reported a 20% survival in his review.² Ghidini et al⁸ reported no survival in his series of 17 prenatally diagnosed cases (6 were terminated, 4 stillborn, 4 died in the first 4 days and the remainder within 4 months).

Conclusion

Although rare, the management of a neonate with a Pentalogy of Cantrell is a multidisciplinary challenge. The anaesthetic considerations are significant and fraught with potential pitfalls. A thorough preoperative assessment and an understanding of the planned surgical procedure and its impact on vital organ function are essential. Although historically the outcome has been dismal, we should not allow a poor anaesthetic to propagate this.

References

1. Cantrell JR, Haller JA, Ravitch MM. A syndrome of congenital defects involving the abdominal wall, sternum, diaphragm, pericardium and heart. *Surg. Gynec Obstet* 1958; 107: 602-14.
2. Toyama WM. Combined congenital defects of the anterior abdominal wall, sternum, diaphragm, pericardium and heart: a case report and review of syndrome. *Pediatrics* 1972; 50: 778-92.
3. Carmi R, Barbash A, Mares AJ. The thoracoabdominal syndrome (TAS): a new X linked dominant disorder. *Am J Med Genet* 1990;36: 109-114
4. Carmi R, Boughman JA. Pentalogy of Cantrell and associated midline anomalies: a possible ventral midline developmental field. *Am J Med Genet* 1992;42: 90-5
5. Haynor DR, Shuman WP, Brewer DK. Imaging of fetal ectopia cordis: roles of sonography and computed tomography. *J Ultrasound Med* 1984;3: 25-7
6. Halbertsma FJ, Van Oort A, van der Staak F. Cardiac diverticulum and omphalocele: Cantrell's pentalogy or syndrome. *Cardiol Young* 2000;12:71-4.
7. Laloyaux P, Veyckemans F, van Dyck M. Anaesthetic management of a prematurely born infant with Cantrell's Pentalogy. *Paediatr Anaesth* 1998; 8; 163-66
8. Ghidini A, Sirtori M, Romero R, Hobbins JC; Prenatal diagnosis of Pentalogy of Cantrell. *J Ultrasound Med* 1988 7; 567-72.
9. Fox JE, Gloster ES, Mirchandani R. Trisomy 18 with Cantrell pentalogy in a stillborn infant. *Am J Med Genet* 1988;31: 391- 4
10. Bryke CR Breg WR. Pentalogy of Cantrell in Buyse ML(ed); *Birth Defects Encyclopaedia*. Blackwell Science publications 1990 p 1375-76.