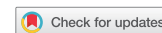

# Bardet–Biedl syndrome: expect the unexpected, suspect the unsuspected

Larissa Cronjé\* 

Perioperative Research Group, Department of Anaesthesiology and Critical Care, Nelson R. Mandela School of Medicine, University of KwaZulu-Natal, King Edward VIII Hospital, Durban, South Africa

\*Corresponding author, email: [lallipop@mweb.co.za](mailto:lallipop@mweb.co.za)



This is the first reported description of Bardet–Biedl syndrome (BBS) with the combination of a malacic bifid epiglottis and anterior laryngeal web. Anaesthesia for BBS has numerous concerns and these are reviewed, focusing on features that manifest not only in BBS but across a spectrum of syndromes that impact airway management. Congenital laryngeal anomalies (CLA) are rare and usually present preoperatively with upper airway obstruction and stridor. In asymptomatic infants, CLA may cause unexpected airway problems under anaesthesia which can be mistaken for more common occurrences, such as laryngospasm. Preoperative dysphonia may be the only clue to suspecting the presence of a CLA. The combination of obesity, polysyndactyly/brachydactyly and even subtle craniofacial abnormalities should always alert the anaesthetist to the possibility of a CLA and difficult airway.

**Keywords:** anterior laryngeal web, Bardet–Biedl syndrome, bifid epiglottis, laryngeal anomalies, paediatric anaesthesia, paediatric obesity, stridor, craniofacial syndromes, upper airway obstruction

## Introduction

Bardet–Biedl syndrome (BBS) is a rare autosomal recessive ciliopathy (MIM 209900),<sup>1,2</sup> distinct from Laurence–Moon–Biedl syndrome.<sup>3,4</sup> Renal disease<sup>3,5–10</sup> and cardiovascular manifestations<sup>6,9,11–13</sup> account for the greatest morbidity and mortality in BBS. Patients with BBS may present for multiple surgical procedures, the majority related to manifestations or complications of the disease.<sup>13,14</sup>

Craniofacial and airway abnormalities are not considered diagnostic in BBS,<sup>3</sup> yet there is increasing recognition of the pattern, frequency, associated morbidity and anaesthetic challenges.<sup>9,12,13,15</sup> We describe the unexpected finding of a bifid epiglottis and anterior laryngeal web in a 15-month-old child with BBS who developed upper airway obstruction (UAO) and stridor during anaesthesia for club foot correction. A clinical review of BBS is provided, highlighting features that may occur across a spectrum of syndromes and have implications for airway management.

## Case report

The patient presented with dysmorphism at birth and was diagnosed with Bardet–Biedl syndrome. Abnormalities included: hypogonadism, bilateral hydronephrosis with multiple cortical cysts, polydactyly of the left hand and both feet, syndactyly of the right little toe, and bilateral club feet (Figure 1a–b). Renal function, cardiac echocardiography and ophthalmic assessment were normal. The patient was noted to have micrognathia, but no other dysmorphic facial features.

Assessment at one year identified no new abnormalities but indicated developmental delay, although he was able to crawl and 'say words'. Birth weight was on the 5th percentile (2.49 kg) but by one year this had increased to > 95th percentile (13 kg), whilst he was on only the 25th percentile for height (73 cm).

At the current admission, he was 15 months old and had no respiratory, airway or feeding problems although he was noted to have a 'soft cry'. Renal function and cardiorespiratory examination were normal. He weighed 14.4 kg (> 95th percentile)

with significant truncal, limb, facial and neck adiposity. He had subtle facial dysmorphism including a round face, bitemporal narrowing and deep-set eyes. Although previously reported, examination did not confirm significant micrognathia.

The patient was booked for a bilateral club foot repair and received 300 mg of paracetamol syrup and clear sweet fluids two hours preoperatively. The primary airway plan was inhalational induction and airway maintenance with a supraglottic airway device (SGAD) and pressure support ventilation (PSV). A difficult airway management cart was available in the theatre complex, including a paediatric flexible fibre-optic bronchoscope (FOB) and an Airtraq® Size 1 (Prodol Meditec S.A., Vizcaya, Spain).

Routine monitoring was placed in theatre and the child was induced on the mother's lap with oxygen, air and sevoflurane. After transfer to the operating table he developed UAO and stridor, assumed to be laryngospasm due to light anaesthesia. A jaw thrust plus continuous positive airway pressure (CPAP) manoeuvres were ineffective but intravenous access was gained without difficulty and signs abated after 10 mg of propofol and insertion of an SGAD (size 2 iGel® [Intersurgical, Wokingham, UK]). Antibiotic prophylaxis and ketamine 0.2 mg/kg were administered, and a caudal block was performed in the right lateral with 14 mL of 0.25% bupivacaine. On PSV the child developed two additional episodes of stridor and inadequate tidal volumes, which were attributed to a dislodged SGAD and accumulation of airway secretions. No episode was associated with desaturation, haemodynamic instability or aspiration.

Direct laryngoscopy (DL) was performed at the end of surgery to ascertain whether there were any abnormalities of the upper airway. A size 2 straight blade obtained a Cormack–Lehane (CL) grade 2 view, with a percentage of glottic opening score<sup>16</sup> (POGO) of < 20%. This revealed a bifid epiglottis with features of laryngomalacia (malacic), which was folded down over the larynx and prolapsing into the laryngeal inlet on inspiration and which could not be lifted, as the blade kept slipping through the defect. After changing to a curved blade and with significant external laryngeal manipulation (ELM) a CL grade 1 view, POGO

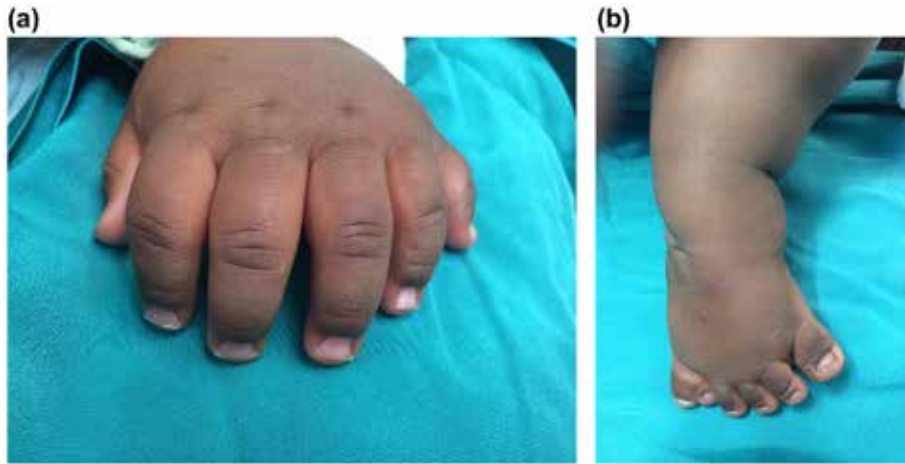


Figure 1: (a) Left hand showing polydactyly and (b). Right foot showing polydactyly, club foot and syndactyly of the 5th and 6th digits.

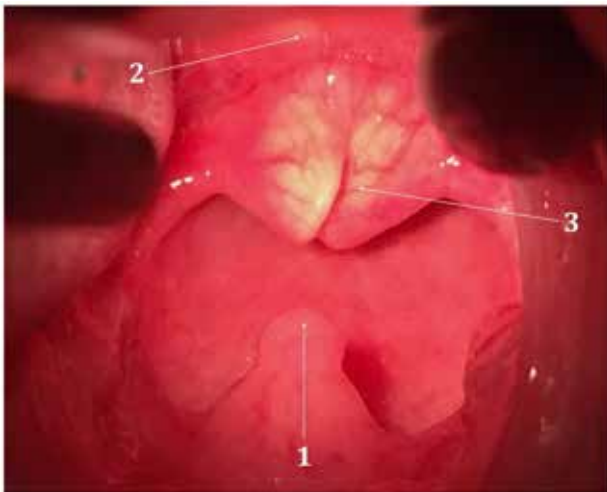


Figure 2: View of the malacic bifid epiglottis obtained with a curved blade. 1 = uvula, 2 = base of tongue, 3 = bifid epiglottis with separate right and left leaflets prolapsing into glottic opening.

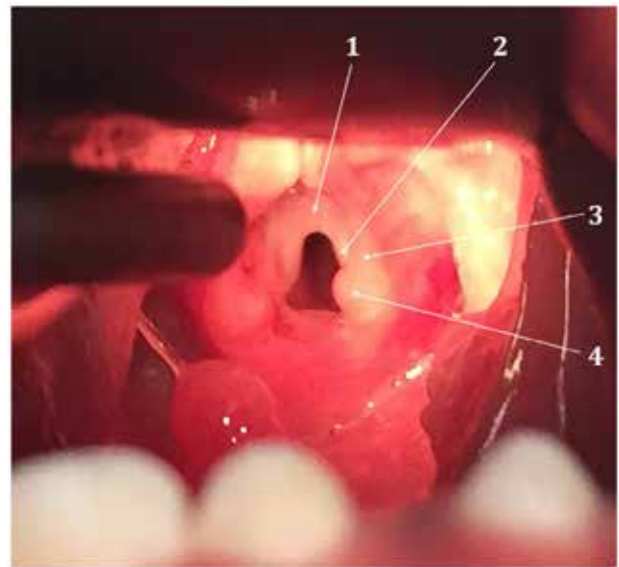


Figure 4: Best view of the supraglottis demonstrating the anterior laryngeal web (obtained with a curved blade and EML). 1 = anterior laryngeal web, 2 = small right true vocal cord, 3 = shortened aryepiglottic fold, 4 = prolapsing right arytenoid cartilage.

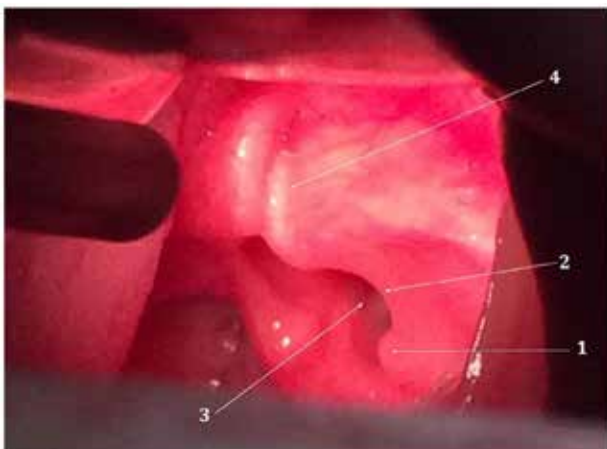


Figure 3: Best view of the glottis obtained with a straight blade and EML (POGO < 20%). 1 = arytenoid cartilage, 2 = shortened right aryepiglottic fold, 3 = glottic opening, 4 = right leaflet of bifid epiglottis.

100% score was obtained and a Grade 1 anterior laryngeal web was identified (see Figures 2 to 4).

The patient was awakened uneventfully with no further episodes of airway obstruction, stridor or respiratory distress in the recovery room or overnight in a high care observation unit. The mother was counselled regarding the findings and the patient was referred for otorhinolaryngology (ENT) consultation. He was discharged well on day three postoperatively.

**Clinical review of BBS**

**Molecular mechanisms, genetics and diagnostic criteria**

Advances in molecular research have identified dysfunction of cilia (micro-tubule based intracellular organelles), as causative in all six cardinal features of BBS.<sup>1,2,17</sup> Cilia are responsible for transduction of molecular signals between cells during development and are implicated in the aetiology of a variety of

different craniofacial syndromes that share features with BBS, leading to the proposal of a new classification of 'craniofacial ciliopathies'.<sup>18</sup>

Twenty-one genes<sup>19</sup> have been identified, and testing confirms the diagnosis in 80% of patients, improving surveillance and earlier interventions to minimise complications.<sup>2,8,11,12</sup> As a pleiotropic disease, genotypes and related phenotypes vary widely in expression, onset and clinical severity.<sup>2,6,9,12,19-21</sup> As not all features are congenital, diagnosis may be delayed, especially in the absence of polydactyly.<sup>2</sup> The disease or full extent of the abnormalities may therefore be unrecognised when patients present to theatre.

Diagnosis remains primarily clinical and Beale's modified diagnostic criteria, comprising primary and secondary features, have been widely adopted (Table 1).<sup>3</sup> Numerous additional non-diagnostic features are described, although the association may be unreliable in some.<sup>2-5,9,12,13,15,22-24</sup>

### Anaesthetic challenges

Anaesthetic concerns for BBS patients have been reviewed<sup>13,14</sup> and are summarised with additional source material in Table 2. Anaesthetic morbidity is related to the manifestation of BBS rather than the disease per se,<sup>13,14</sup> hence references from BBS patients and non-BBS paediatric patients with similar phenotypic manifestations are reviewed. Further discussion will focus on features, especially rare airway anomalies, that may result in difficult airway management.

Table 1: BBS modified diagnostic criteria and frequency<sup>2,3,5,6,9,10,12,15,25,26</sup>

Feature	Prevalence (%)
Primary features:	
Rod-cone dystrophy	90-100
Obesity	72-100
Polydactyly	63-93
Hypogonadism in males/genital anomalies	59-98
Learning disabilities	50-61
Renal anomalies	20-80
Secondary features:	
Brachydactyly/syndactyly	46-100
Developmental delay	50-91
Speech disorder/delay	54-81
Ataxia/poor coordination/imbalance	40-86
Left ventricular hypertrophy/congenital heart disease (including ventricular septal defects and aortic valve lesions) <sup>6,9,11</sup>	10-50
Diabetes mellitus	6-48
Hepatic fibrosis	53 <sup>15</sup>
Dental crowding/hypodontia/small roots/high arched palate	51
Strabismus/cataracts/astigmatism	
Polyuria/polydipsia (nephrogenic diabetes insipidus)	
Mild spasticity (especially lower limbs)	

Notes: Four primary features are required to be present, or three primary plus two secondary features.

Modified from Beales *et al.*<sup>3</sup>

### Diagnostic features with potential for difficult airway management

#### Obesity

Obesity >95th percentile for age and gender significantly increases the risk of co-morbidities.<sup>36</sup> Obesity has been associated with 79 genetic syndromes.<sup>37</sup> There is increased risk of airway events in older obese children, but data on difficult intubation are conflicting,<sup>29,30,32,33,36</sup> and studies on anaesthetic implications in children aged under two years are lacking.<sup>31</sup> Obesity in BBS usually manifests by 2-3 years of age,<sup>2,9,15</sup> but rapid weight gain may occur in the first year of life<sup>13</sup> as demonstrated in our case. Obesity is central in adults<sup>2,3</sup> but diffusely distributed in children.<sup>2,13</sup> Intravenous access is more difficult in BBS and obese children in general,<sup>14,38</sup> but was not problematic in the case presented. Obesity did impact in the following ways: (i) difficulty with identification of traditional landmarks for caudal block although our block was successful; (ii) degree of craniofacial dysmorphism was obscured by facial and neck adiposity; and (iii) airway adiposity may have contributed to upper airway obstruction. Similar problems are confirmed in the literature.<sup>2,13,14,29</sup>

#### Orthopaedic manifestations

Polydactyly is often the only sign present at birth and clue to the diagnosis of BBS.<sup>2,21</sup> Of interest is that our patient's mother had chosen not to have the extra digits removed as she said it made her child 'unique'. There are many additional orthopaedic manifestations including club foot, although this association may be incidental.<sup>2,3,9,12,13,23</sup> Frequencies of polydactyly/brachydactyly/syndactyly vary widely in different BBS populations but are common.<sup>3,5,9,15</sup> These features are associated with several other syndromes which have craniofacial or airway abnormalities, especially bifid epiglottis,<sup>18,28,39-41</sup> and if present in an undiagnosed child should alert the anaesthetist to an underlying syndrome with potential airway problems.

### Non-diagnostic features with potential for difficult airway management

#### (1) Craniofacial features:

A 'typical' BBS facies has been described,<sup>25</sup> but marked phenotypic variation exists (Table 3).<sup>3,9,12,15,18,25</sup> Preoperative abnormalities were identified in this case, but malar hypoplasia and mild retrognathia were underestimated. These features are likely to have contributed to upper airway obstruction and difficulty in obtaining a full glottic view. Craniofacial features may be subtle and therefore missed.<sup>2,9,12</sup>

#### (2) Laryngeal anomalies (rare):

Acquired lesions occur more frequently than congenital laryngeal anomalies (CLA) and are usually secondary to infection, surgery or intubation and are not reviewed here.<sup>42-44</sup> CLA are mostly glottic but can be supraglottic, infraglottic, or involve synchronous lesions. Laryngomalacia (LM) is the commonest lesion, occurring in 60-70% of cases.<sup>43,45-50</sup> Laryngeal webs (5% of cases), and specifically bifid epiglottis (BE), are exceedingly rare,<sup>43,45-50</sup> and almost always associated with a syndrome, craniofacial abnormalities or other organ (especially cardiac) defects.<sup>28,43,45-54</sup>

#### Bifid epiglottis

BE may have two separate leaflets (more commonly associated with syndromes) or a submucous cleft.<sup>24,45,54</sup> BE has been described in only six children with BBS, half of whom were

Table 2: Anaesthetic concerns related to diagnostic features of Bardet–Biedl syndrome

Feature(s)	Implications
Blindness/learning disabilities/cognitive impairment/developmental delay/deafness/behaviour problems <sup>3,14,27</sup>	Multidisciplinary perioperative medical and allied team <sup>27</sup> Reduced patient ability to cooperate or communicate Emotionally labile Difficult to establish rapport Difficulty with anaesthesia induction Ophthalmic/ENT surgery
Polydactyly Brachydactyly/syndactyly	Placement of lines if operating on hands/feet Difficulty with intravenous access Association of brachydactyly/polysyndactyly with bifid epiglottis <sup>24,28</sup>
Obesity <sup>17,29–33</sup>	Preoperative: screen for comorbidities Snoring/obstructive sleep apnoea (OSA) (OR 4.0) <sup>32</sup> Dyslipidaemia, <sup>6</sup> metabolic syndrome <sup>34</sup> Accelerated cardiovascular disease Asthma (higher in both obesity and BBS) <sup>3,9,32</sup> Intraoperative: Difficult airway management including: <sup>29,32</sup> airway obstruction major (OR 1.8) bag mask ventilation (OR 4.5) bronchospasm (OR 3.3) desaturation, critical airway events (OR 1.9) Divergent information on intubation difficulty Difficult intravenous access <sup>14</sup> Difficult landmarks for regional anaesthesia <sup>14</sup> Altered drug kinetics and dose calculations Opioid sensitivity with OSA Postoperative Unexpected hospital admission High care if co-morbidities significant
Renal anomalies <sup>6–8</sup>	Preoperative Renal ultrasound Renal function tests Intraoperative Chronic kidney disease and attendant problems Urogenital surgery including kidney transplant Avoid nephrotoxic drugs Polyuria/polydipsia (nephrogenic diabetes insipidus)
Cardiovascular: <sup>6,11,15</sup> Congenital heart disease Hypertension <sup>12</sup> Left ventricular hypertrophy Cardiomyopathy	Preoperative: Cardiology cardiac evaluation, check blood pressure, electrocardiogram and echocardiogram and lipid profile Cardiac/hypertensive medication Intraoperative considerations for: Anaesthesia for congenital cardiac surgery or

(Continued)

Table 2: (Continued)

Feature(s)	Implications
Ischaemic heart disease <sup>9</sup>	Non-cardiac surgery with uncorrected cardiac lesion e.g. haemodynamic monitoring, antibiotic prophylaxis Postoperative High care or intensive care
Endocrine Diabetes mellitus <sup>35</sup>	Preoperative: screen for abnormal glucose metabolism Check HbA1c, glucose, electrolytes, and ketones Exclude complications, e.g. autonomic neuropathy Short fasting time, intravenous access in ward Manage diabetic medication Intraoperative: Monitor glucose hourly: keep at 5–10 mmol/L Hemodynamic instability possible Reduce stress response to limit hyperglycaemia Postoperative: Early oral intake or maintain intravenous fluids Strict glucose monitoring
Speech disorder/delay <sup>24</sup> Dental crowding/hypodontia/small roots/high arched palate	Difficulty with: Communication Airway management Dental or ENT surgery
Hepatic fibrosis, hypothyroidism <sup>3,9,15</sup>	Perform liver function and thyroid function tests

OR = odds ratio.

Table 3: Craniofacial features in BBS patients

Feature	Prevalence
Brachycephaly	92%
Frontal balding in adult males	92%
High-arched palate	86%
Narrow palpebral fissures	81%
Short palpebral fissures	77%
Bitemporal narrowing	65%
Long ears	61%
Macrocephaly	58%
Downturned mouth	58%
Thin upper lip	54%
Small mouth	38%
Shallow philtrum	35%
Long philtrum	35%
Ptosis	27%
Characteristic facies: <sup>15,25</sup> retrognathia/micrognathia, wide forehead, downward palpebral fissure, malar hypoplasia, low nasal bridge, large nose, small mouth, thin upper lip and slightly everted lower lip	

Modified from Moore *et al.*<sup>9</sup>

Table 4: Grading of anterior laryngeal webs and subglottic stenosis

Condition	Grading			
	Grade I	Grade II	Grade III	Grade IV
Anterior laryngeal webs <sup>38</sup> % glottic area affected (Cohen grading)	0–35%	35–50%	50–75%	75–90%
Subglottic stenosis <sup>50</sup> % luminal narrowing (Meyer– Cotton grading) <sup>60</sup>	0–50%	51–70%	71–99%	Absent lumen

asymptomatic and half of whom had significant symptoms and morbidity related to the BE.<sup>22,24,45,55,56</sup> Stevens *et al.*<sup>45</sup> reviewed all cases of BE reported in the literature ( $n = 23$ ) and suggest that BE may be under-recognised in BBS either as the disease had not been appropriately diagnosed or remained unrecognised in asymptomatic patients.<sup>45,54</sup>

**Congenital laryngeal webs (CLW) (previously undescribed in BBS)**

Congenital laryngeal webs, estimated to occur in 1:10 000 births,<sup>57</sup> are part of a spectrum of abnormalities, including laryngeal atresia and stenosis, which result from failed embryological recanalisation of the laryngeal lumen.<sup>50,53</sup> Some 75% occur at the glottic level, the majority being anterior and graded by the percentage of glottic area affected.<sup>43,46,50,53,58</sup> Anterior webs (ALW) are occasionally complicated by subglottic stenosis, which may cause additional difficulties with intubation or airway management (Table 4).<sup>42,43,59</sup>

**Presentation in non-anaesthetised patients**

Laryngeal anomalies present with:

- (i) *respiratory signs*: most commonly stridor and UAO,<sup>43,47,61</sup> but also distress, hypoxia, apnoea, OSA, chronic wheezing, and repeated chest infections;<sup>22,24,28,45,46</sup>
- (ii) *swallowing problems*: resulting in gastro-oesophageal reflux disease (GERD), accumulation of secretions, feeding difficulties, failure to thrive and repeated aspiration;<sup>22,24,28,45,46</sup>
- (iii) *voice abnormalities*.<sup>43,46,62,63</sup> Symptomatic patients are often mislabelled as non-responsive asthma or GERD, whilst asymptomatic patients may never be diagnosed or be discovered incidentally.<sup>22,24,28,45,46,63</sup> Surgery is indicated for symptomatic lesions and ranges from emergency surgery for life-threatening airway obstruction to semi-elective procedures for GERD, failure to thrive, or OSA, or later elective procedures to improve voice quality.<sup>43,46,48,53,63</sup>

**Obstructive sleep apnoea**

The combination of obesity, craniofacial features and CLA predisposes to sleep disorder breathing in children; thus OSA should always be sought in BBS and all children with similar features.<sup>32,37,64-66</sup> Safe anaesthetic management of children with OSA includes anticipation of airway events, close respiratory monitoring, avoidance of sedative premedication and opioid-sparing analgesic techniques.<sup>67</sup>

**Differentiating voice disorders from stridor and laryngospasm**

Stridor is an obvious sign of pathological narrowing or obstruction of the airway resulting in turbulent airflow and is exacerbated by crying, feeding or the supine position.<sup>44,46</sup> Acute or worsening stridor may indicate an impending airway emergency.<sup>44,68</sup> Laryngospasm (LS) is an exaggerated response of the laryngeal closure reflex to a stimulus, causing sustained glottic closure<sup>69</sup> with partial or total cessation of airflow.<sup>69,70</sup> (See Table 5 for voice descriptions and grading of stridor and LS.)

An abnormal voice has been described in BBS and is thought to be due to a combination of neurological and anatomical dysfunction with uncoordinated movement of palate, tongue and lips.<sup>24</sup> Dysphonia is a disorder of voice and the commonest cause in older children is overuse of the voice rather than laryngeal pathology.<sup>62,71,72</sup> Subtle or persistent dysphonia in neonates and infants should always raise the suspicion of an underlying laryngeal anomaly, even in the absence of stridor or respiratory distress.<sup>62,63,71</sup>

**Discussion**

**UAO and stridor under anaesthesia**

Even normal infants and neonates are at greater risk of airway events, including UAO and laryngospasm, which may result in significant morbidity.<sup>69,70,74,75</sup> UAO occurs due to an imbalance of anatomical structures and neural mechanisms under anaesthesia, favouring airway collapse and increasing turbulent airflow.<sup>75,76</sup> Children with abnormal craniofacial or airway anatomy are critically reliant on intact neural mechanisms and protective reflexes to maintain airway patency, making UAO and stridor common under anaesthesia.<sup>76</sup>

The work of breathing and airway resistance in spontaneously breathing children under anaesthesia is greatest with mask anaesthesia but improved by SGAD or tracheal tube.<sup>77</sup> Management of UAO and stridor (including LS) is beyond the scope of the review, but correct mask technique, adequate depth of anaesthesia, correct head and neck position and sequential manoeuvres, including (in increasing order of effectiveness) chin lift, jaw thrust, or either of these with CPAP, are essential to maintain airway patency.<sup>69,70,74,77-80</sup>

Table 5: Voice/sound quality and stridor grading

Condition	Quality	
Bardet-Biedl syndrome <sup>3,24</sup>	Breathy, high-pitched and hypernasal speech is slow with misarticulation	
Congenital laryngeal abnormalities <sup>46,63</sup>	High-pitched, soft, weak cry, but may be hoarse or aphonic	
Stridor <sup>44,73</sup>	High-pitched or harsh, often exaggerated during crying or feeding	
	Grading:	
	Grade I	Inspiratory
	Grade II	Inspiratory and expiratory
	Grade III	Inspiratory and expiratory plus pulsus paradoxus
	Grade IV	Silent, respiratory arrest
	Phase:	Anatomic position:
	Muffled	Upper airway obstruction
	Inspiratory	Pharynx, supraglottic, extrathoracic
	Expiratory	Trachea, lower airways, intrathoracic
Biphasic	Glottic or infraglottic	
Laryngospasm <sup>69,70</sup>	High-pitched, initially grade I stridor, which progresses to silent with complete obstruction	

### **Airway management in BBS, and laryngeal anomalies**

Intubation by DL has been reported as successful in all paediatric patients with BBS, albeit occasionally difficult (CL Grade 3).<sup>13,14,22,24,45,55,56,81</sup> In contrast, 67% of adults required an awake FOB or videolaryngoscopy-aided intubation (VL).<sup>13</sup> The difference may be partly due to lack of paediatric videolaryngoscopes in the earlier cases described; intubation trends may change with currently available equipment.<sup>13,14,82–84</sup>

Intubation in patients with BBS and with a BE may be difficult but has been described as 'unexpectedly easy ... through the separate leaflets'.<sup>56</sup> Airway management in symptomatic laryngeal anomalies may be extremely challenging, and may require a tracheostomy.<sup>85,86</sup> Asymptomatic webs may also cause unexpected difficulty at intubation,<sup>57,87</sup> or may be confused with other symptoms such as airway obstruction, stridor or bronchospasm if a mask or SGAD is used.<sup>88</sup>

### **The expected versus the unexpected difficult airway in children**

The expected difficult airway is infrequently encountered in paediatric anaesthesia, and recommendations regarding management are based primarily on case reports/series rather than large trials.<sup>74,75,89</sup> Such cases must be referred to specialist centres with requisite expertise and equipment.<sup>74,89</sup> The current gold standard for elective intubation remains the FOB; however, VL is expected to impact on these recommendations as evidence for their use is increasing in children, including those with a predicted difficult airway.<sup>13,82–84,89–94</sup> VL may not always be successful, either because of restricted mouth opening or

inability to pass the tube in a very anterior larynx,<sup>75,95</sup> thus FOB skills still need to be maintained.

SGADs have an established role in emergency airway rescue or as a conduit for intubation.<sup>75</sup> Elective use of an SGAD as the primary airway in an expected difficult airway may be more controversial, although the literature supports its use.<sup>96–98</sup> Provisos would include availability of alternative rescue devices or intubating strategies, low risk of aspiration, adequate oral access and practitioner experience.<sup>89,98</sup> As all these criteria were met, primary use of an SGAD in the case presented was considered justified.

### **Airway management in the case presented**

All patients with craniofacial abnormalities should be considered potentially difficult. Our patient was otherwise well; his soft cry and subtle dysmorphism did not raise significant concerns about airway management. His voice was in keeping with that described in BBS, which masked the dysphonia associated with the web. A combination of obesity, craniofacial pathology and malacic BE led to UAO and airflow turbulence, causing grade 1 stridor through the laryngeal web. Difficult PSV was due to the combination of laryngeal anomalies. Signs were initially mistaken for common paediatric airway problems but failure to resolve after following the recommended steps mandated direct laryngoscopy. Curved and straight blades have been shown to be equivalent in attaining an optimal laryngeal view in children <2 years;<sup>99</sup> however, the curved blade achieved a better POGO score in this case. Difficult DL demonstrated the impact even mild retrognathia has on obtaining the full glottic view essential to identify all possible lesions. Clinical recommendations and insights gained from this case and review are presented in Table 6.

Table 6: Clinical insights and recommendations

Factor	Considerations
Obesity	<ul style="list-style-type: none"> <li>Risk for co-morbidities, airway events and syndrome</li> <li>Syndrome examples: BBS, Noonan, Prader-Willi, and DiGeorge (beware neonatal hypocalcaemia)</li> </ul>
Polydactyly/brachydactyly/syndactyly	<ul style="list-style-type: none"> <li>Suspect craniofacial syndromes and CLA</li> <li>Syndrome examples: Trisomies 13, 18, 21; Apert Carpenter, Pfeifer, Saethre-Chotzen, Muenke, BBS</li> </ul>
Craniofacial patterns	<ul style="list-style-type: none"> <li>Recognise subtle craniofacial patterns to anticipate difficult airway</li> </ul>
Congenital laryngeal anomalies (BE, ALW)	<ul style="list-style-type: none"> <li>May be asymptomatic</li> <li>Associated with craniofacial syndromes and organ (cardiac) abnormalities e.g. 22q11.2 deletion syndrome</li> <li>BE associated syndromes: Pallister-Hall, Joubert, BBS</li> </ul>
Obstructive sleep apnoea	<ul style="list-style-type: none"> <li>Increases perioperative risk</li> <li>Exclude in obesity, craniofacial syndromes and CLA</li> </ul>
Voice/dysphonia	<ul style="list-style-type: none"> <li>Subtle dysphonia clue to laryngeal pathology</li> <li>Voice in BBS may mask laryngeal pathology</li> </ul>
UAO and stridor under anaesthesia	<ul style="list-style-type: none"> <li>Suspect missed congenital lesions</li> <li>View larynx</li> </ul>
Glottic view:	<ul style="list-style-type: none"> <li>POGO score describes views better than CL, aiding communication between physicians/researchers</li> <li>100% POGO required view to identify all lesions</li> <li>Curved or straight blades are effective in infants</li> </ul>
POGO score	
Blade shape	
Expected difficult airway	<ul style="list-style-type: none"> <li>FOB remains the 'gold standard'</li> <li>VL has an increasing role in paediatric difficult airway management but is not fail-safe</li> <li>SGAD may be used as the primary airway in expected difficult airway with strict provisos</li> </ul>

## Conclusion

This is the first description of a case of Bardet-Biedl syndrome with the combination of a malacic bifid epiglottis and anterior laryngeal web. Few anaesthetists will encounter a patient with BBS or the even rarer associated anomalies discussed. However, as a 'model' craniofacial ciliopathy, BBS provides insights into a range of syndromes and the case and review has highlighted several important lessons that are applicable to the paediatric anaesthetist, especially those anaesthetising syndromic children. Unexpected difficulties with airway management should always be anticipated, and unsuspected lesions should always be considered.

## Consent

Signed consent was obtained from the mother for publication of this case.

**Acknowledgements** – Thanks are offered to Murray, Ted, Lavinia and Nokukhanya for their assistance; Professor Rasool for his incredible knowledge and interesting Tuesdays; and to a mother who delights in her son.

**Disclosure statement** – No potential conflict of interest was reported by the authors.

## ORCID

Larissa Cronjé  <http://orcid.org/0000-0001-5508-7471>

## References

- Zaghloul NA, Katsanis N. Mechanistic insights into Bardet-Biedl syndrome, a model ciliopathy. *J Clin Invest*. 2009;119(3):428–37. <https://doi.org/10.1172/JCI37041>
- Forsythe E, Beales PL. Bardet-Biedl syndrome. *Eur J Hum Genet*. 2013;21(1):8–13. <https://doi.org/10.1038/ejhg.2012.115>
- Beales P, Elcioglu N, Woolf A, et al. New criteria for improved diagnosis of Bardet-Biedl syndrome: results of a population survey. *J Med Genet*. 1999;36(6):437–46.
- Forsythe E, Beales PL. Bardet-Biedl syndrome. [Initial posting] 2003 Jul 14 [Updated 2015 Apr 23], pg 1–70. In: Adam MP, Ardinger HH, Pagon RA, et al., editors. *GeneReviews*(R). Seattle (WA): University of Washington, Seattle; 1993–2017.
- Green JS, Parfrey PS, Harnett JD, et al. The cardinal manifestations of Bardet-Biedl syndrome, a form of Laurence-Moon-Biedl syndrome. *NEJM* 1989;321(15):1002–9. <https://doi.org/10.1056/NEJM198910123211503>
- Imhoff O, Marion V, Stoetzel C, et al. Bardet-Biedl syndrome: a study of the renal and cardiovascular phenotypes in a French cohort. *Clin J Am Soc Nephrol*. 2011;6(1):22–29. <https://doi.org/10.2215/CJN.03320410>
- O'Dea D, Parfrey PS, Harnett JD, et al. The importance of renal impairment in the natural history of bardet-biedl syndrome. *Am J Kidney Dis*. 1996;27(6):776–783. [https://doi.org/10.1016/S0272-6386\(96\)90513-2](https://doi.org/10.1016/S0272-6386(96)90513-2)
- Forsythe E, Sparks K, Best S, et al. Risk factors for severe renal disease in Bardet-Biedl syndrome. *J Am Soc Nephrol*. 2017;28(3):963–970. <https://doi.org/10.1681/ASN.2015091029>
- Moore SJ, Green JS, Fan Y, et al. Clinical and genetic epidemiology of Bardet-Biedl syndrome in Newfoundland: A 22-year prospective, population-based, cohort study. *Am J Med Genet A*. 2005;132A(4):352–360. [https://doi.org/10.1002/\(ISSN\)1552-4833](https://doi.org/10.1002/(ISSN)1552-4833)
- Forsythe E, Sparks K, Best S, et al. Risk factors for severe renal disease in Bardet-Biedl syndrome. *J Am Soc Nephrol*. 2017;28(3):963–70. <https://doi.org/10.1681/ASN.2015091029>
- Forsythe E, Sparks K, Hoskins BE, et al. Genetic predictors of cardiovascular morbidity in Bardet-Biedl syndrome. *Clin Genet*. 2015;87(4):343–9. <https://doi.org/10.1111/cge.2015.87.issue-4>
- Castro-Sánchez S, Álvarez-Satta M, Cortón M, et al. Exploring genotype-phenotype relationships in Bardet-Biedl syndrome families. *J Med Genet*. 2015;52(8):503–13. <https://doi.org/10.1136/jmedgenet-2015-103099>
- Smith BB, Barbara DW, Hyder JA, et al. Anesthetic considerations for patients with Bardet-Biedl syndrome: a case series and review of the literature. *Paediatric Anaesthesia*. 2016;26(4):429–37. <https://doi.org/10.1111/pan.2016.26.issue-4>
- Low J, Brown T. Bardet-Biedl syndrome: review of anaesthetic problems. *Pediatric Anesthesia*. 1992;2(3):245–8. <https://doi.org/10.1111/pan.1992.2.issue-3>
- Fieggen K, Milligan C, Henderson B, et al. Bardet Biedl syndrome in South Africa: a single founder mutation: the new millennium. *S Afr Med J*. 2016;106(6):72–4. <https://doi.org/10.7196/SAMJ.2016.v106i6.11000>
- Levitan RM, Ochroch EA, Rush S, et al. Assessment of airway visualization: validation of the percentage of glottic opening (POGO) scale. *Acad Emerg Med*. 1998;5(9):919–23. <https://doi.org/10.1111/j.1553-2712.1998.tb02823.x>
- Guo D-F, Rahmouni K. Molecular basis of the obesity associated with Bardet-Biedl syndrome. *Trends Endocrinol Metab*. 2011;22(7):286–93.
- Brugmann SA, Cordero DR, Helms JA. Craniofacial ciliopathies: A new classification for craniofacial disorders. *Am J Med Genet A*. 2010;152A(12):2995–3006. <https://doi.org/10.1002/ajmg.a.33727>
- BARDET-BIEDL SYNDROME 1; BBS1. OMIM®. Online Mendelian Inheritance in Man®. An Online Catalog of Human Genes and Genetic Disorders [Internet]. Available from: <https://www.omim.org/entry/209900>
- M'hamedi O, Ouertani I, Chaabouni-Bouhamed H. Update on the genetics of Bardet-Biedl syndrome. *Mol Syndromol*. 2014;5(2):51–6. <https://doi.org/10.1159/000357054>
- Khan SA, Muhammad N, Khan MA, et al. Genetics of human Bardet-Biedl syndrome, an updates (sic). *Clin Genet* 2016 Jul;90(1):3–15. Singapore.
- Copenhaver E, Hanna S, Mulhearn N, et al. Bifid epiglottis as a cause of recurrent pneumonia in a patient with Bardet-Biedl syndrome, a ciliopathy. *Int J Pediatr Otorhinolaryngol Extra*. 2015;10(4):94–5. <https://doi.org/10.1016/j.pedex.2015.10.001>
- Ramirez N, Marrero L, Carlo S, et al. Orthopaedic manifestations of Bardet-Biedl syndrome. *J Pediatr Orthop*. 2004;24(1):92–96.
- Urban SL, Baugh RF. Otolaryngologic features of Laurence-Moon-Bardet-Biedl syndrome. *Otolaryngology—Head and Neck Surgery*. 1999;120(4):571–4.
- Lorda-Sanchez I, Ayuso C, Sanz R, et al. Does Bardet-Biedl syndrome have a characteristic face? *J Med Genet* 2001;38(5):14e–14. <https://doi.org/10.1136/jmg.38.5.e14>
- Elbedour K, Zucker N, Zalstein E, et al. Cardiac abnormalities in the Bardet-Biedl syndrome: Echocardiographic studies of 22 patients. *Am J Med Genet*. 1994;52(2):164–9. [https://doi.org/10.1002/\(ISSN\)1096-8628](https://doi.org/10.1002/(ISSN)1096-8628)
- Barnett S, Reilly S, Carr L, et al. Behavioural phenotype of Bardet-Biedl syndrome. *J Med Genet* 2002;39(12):76e–76. <https://doi.org/10.1136/jmg.39.12.e76>
- Tsurumi H, Ito M, Ishikura K, et al. Bifid epiglottis: syndromic constituent rather than isolated anomaly. *Pediatrics Int*. 2010;52(5):723–8. <https://doi.org/10.1111/ped.2010.52.issue-5>
- Tait AR, Voepel-Lewis T, Burke C, et al. Incidence and risk factors for perioperative adverse respiratory events in children who are obese. *Anesthesiology*. 2008;108(3):375–80. <https://doi.org/10.1097/ALN.0b013e318164ca9b>
- Setzer N, Saade E. Childhood obesity and anesthetic morbidity. *Pediatric Anesthesia* 2007;17(4):321–6. <https://doi.org/10.1111/pan.2007.17.issue-4>
- Mortensen A, Lenz K, Abildstrøm H, et al. Anesthetizing the obese child. *Pediatric Anesthesia* 2011;21(6):623–9. <https://doi.org/10.1111/pan.2011.21.issue-6>
- El-Metainy S, Ghoneim T, Aridae E, et al. Incidence of perioperative adverse events in obese children undergoing elective general surgery. *Br J Anaesth*. 2011;106(3):359–63. <https://doi.org/10.1093/bja/aeq368>



33. Nafiu OO, Reynolds PI, Bamgbade OA, et al. Childhood body mass index and perioperative complications. *Pediatric Anesthesia*. 2007;17(5):426–30. <https://doi.org/10.1111/pan.2007.17.issue-5>
34. Keskin M, Atabek ME, Kurtoğlu S. Bardet-Biedl syndrome with syndrome X: a patient report. *J Pediatr Endocrinol Metab*. 2004;17(6):914–6.
35. Rhodes ET, Gong C, Edge JA, et al. Management of children and adolescents with diabetes requiring surgery. *Pediatric Diabetes*. 2014;15(S20):224–31. <https://doi.org/10.1111/pan.2014.15.issue-S20>
36. Owen J, John R. Childhood obesity and the anaesthetist. *Continuing Education in Anaesthesia Critical Care & Pain*. 2012;12(4):169–75. <https://doi.org/10.1093/bjaceaccp/mks015>
37. Kaur Y, de Souza R, Gibson W, et al. A systematic review of genetic syndromes with obesity. *Obesity Reviews*. 2017;18(6):603–34. <https://doi.org/10.1111/obr.v18.6>
38. Nafiu OO, Burke C, Cowan A, et al. Comparing peripheral venous access between obese and normal weight children. *Pediatric Anesthesia*. 2010;20(2):172–6. <https://doi.org/10.1111/pan.2010.20.issue-2>
39. Castilla EE, da Fonseca RL, da Graça Dutra Maria, et al. Epidemiological analysis of rare polydactylies. *Am J Med Genet* 1996;65(4):295–303. [https://doi.org/10.1002/\(ISSN\)1096-8628](https://doi.org/10.1002/(ISSN)1096-8628)
40. Garagnani L, Smith GD. Syndromes associated with syndactyly. *The Pediatric Upper Extremity*. 2015;1:297–324.
41. Panigrahi I. Craniosynostosis genetics: the mystery unfolds. *Indian J Hum Genet*. 2011;17(2):48. <https://doi.org/10.4103/0971-6866.86171>
42. Stephenson KA, Wyatt ME. Glottic stenosis. *Semin Pediatr Surg*. 2016;25(3):132–7. <https://doi.org/10.1053/j.sempedsurg.2016.02.003>
43. Nicollas R, Triglia J. The anterior laryngeal webs. *Otolaryngol. Clin. North Am*. 2008;41(5):877–88. <https://doi.org/10.1016/j.otc.2008.04.008>
44. Maloney E, Meakin GH. Acute stridor in children. *Continuing Education in Anaesthesia, Critical Care & Pain*. 2007;7(6):183–6. <https://doi.org/10.1093/bjaceaccp/mkm041>
45. Stevens CA, Ledbetter JC. Significance of bifid epiglottis. *Am J Med Genet Part A*. 2005;134A(4):447–449. [https://doi.org/10.1002/\(ISSN\)1552-4833](https://doi.org/10.1002/(ISSN)1552-4833)
46. Rutter MJ. Congenital laryngeal anomalies. *Braz J Otorhinolaryngol*. 2014;80(6):533–9. <https://doi.org/10.1016/j.bjorl.2014.08.001>
47. Dobbie AM, White DR. Laryngomalacia. *Pediatr Clin North Am*. 2013;60(4):893–902. <https://doi.org/10.1016/j.pcl.2013.04.013>
48. Bedwell J, Zalzal G. Laryngomalacia. *Semin Pediatr Surg*. 2016;25(3):119–22. <https://doi.org/10.1053/j.sempedsurg.2016.02.004>
49. Thorne MC, Garetz SL. Laryngomalacia: review and summary of current clinical practice in 2015. *Paediatr Respir Rev*. 2016;17:3–8. <https://doi.org/10.1016/j.prrv.2015.02.002>
50. Windsor A, Clemmens C, Jacobs I. Rare upper airway anomalies. *Paediatr Respir Rev*. 2016;17:24–8. <https://doi.org/10.1016/j.prrv.2015.07.001>
51. Papay FA, McCarthy VP, Eliachar I, et al. Laryngotracheal anomalies in children with craniofacial syndromes. *J Craniofac Surg*. 2002;13(2):351–64. <https://doi.org/10.1097/00001665-200203000-00036>
52. McElhinney DB, Jacobs I, McDonald-McGinn DM, et al. Chromosomal and cardiovascular anomalies associated with congenital laryngeal web. *Int J Pediatr Otorhinolaryngol*. 2002;66(1):23–7. [https://doi.org/10.1016/S0165-5876\(02\)00184-2](https://doi.org/10.1016/S0165-5876(02)00184-2)
53. deTrey L, Lambercy K, Monnier P, et al. Management of severe congenital laryngeal webs—a 12 year review. *Int J Pediatr Otorhinolaryngol*. 2016;86:82–6. <https://doi.org/10.1016/j.ijporl.2016.04.006>
54. Caron JD. Bifid epiglottis revisited. *Int J Pediatr Otorhinolaryngol*. 2006;1(2):115–8. <https://doi.org/10.1016/j.pedex.2006.01.008>
55. Chittoodan S, Crowe S. Day care general anaesthesia for a child with Bardet-Biedl syndrome. *Case Reports in Med*. 2010;2010:1–2. <https://doi.org/10.1155/2010/239239>
56. Katsika E, Aslanidis T, Charitidou S. Renal transplantation in a patient with Bardet-Biedl syndrome, situs inversus totalis and bifid epiglottis: anesthetic management. *Hippokratia*. 2011;15(4):376.
57. Chong ZK, Jawan B, Poon YY, et al. Unsuspected difficult intubation caused by a laryngeal web. *Br J Anaesth*. 1997;79(3):396–7. <https://doi.org/10.1093/bja/79.3.396>
58. Cohen SR. Congenital glottic webs in children: a retrospective review of 51 patients. *Ann Otol Rhinol Laryngol*. 1985;94(6\_suppl):2–16. <https://doi.org/10.1177/000348948509405601>
59. Hannallah R, Rosales J. Laryngeal web in an infant with tracheoesophageal fistula. *Anesthesiology*. 1975;42(1):96–7. <https://doi.org/10.1097/00000542-197501000-00014>
60. Myer III CM, O'Connor DM, Cotton RT. Proposed grading system for subglottic stenosis based on endotracheal tube sizes. *Ann Otol Rhinol Laryngol*. 1994;103(4):319–23. <https://doi.org/10.1177/000348949410300410>
61. Pflieger A, Eber E. Management of acute severe upper airway obstruction in children. *Paediatr Respir Rev*. 2013;14(2):70–7. <https://doi.org/10.1016/j.prrv.2013.02.010>
62. Rodriguez H, Cuestas G, Zanetta A. Dysphonia in children due to congenital laryngeal web. Case series. *Archivos argentinos de pediatria*. 2012;111(4):e82–5.
63. Shah J, White K, Dohar J. Vocal characteristics of congenital anterior glottic webs in children: a case report. *Int J Pediatr Otorhinolaryngol*. 2015;79(6):941–5. <https://doi.org/10.1016/j.ijporl.2015.04.008>
64. Hahn SS, Greenberg H, Steinberg H. Obstructive sleep apnea in Bardet-Biedl syndrome. B65 things that go bump in the night: sleep case studies and NON-OSA sleep: *Am Thoracic Soc*. 2016; A4216–A.
65. Viggiano D, Santoriello C, Ferretti A, et al. First description of obstructive sleep apnea and its clinical consequences on quality of life in Bardet-Biedl syndrome. *Respir Med CME*. 2008;1(2):182–4. <https://doi.org/10.1016/j.rmedc.2008.04.006>
66. Luna-Paredes C, Antón-Pacheco JL, García Hernández GG, et al. Screening for symptoms of obstructive sleep apnea in children with severe craniofacial anomalies: assessment in a multidisciplinary unit. *Int J Pediatr Otorhinolaryngol* 2012;76(12):1767–70. <https://doi.org/10.1016/j.ijporl.2012.08.020>
67. Patino M, Sadhasivam S, Mahmoud M. Obstructive sleep apnoea in children: perioperative considerations. *Br J Anaesth*. 2013;111(suppl 1):i83–i95. <https://doi.org/10.1093/bja/aet371>
68. Ida JB, Thompson DM. Pediatric Stridor. *Otolaryngol Clin North Am*. 2014;47(5):795–819. <https://doi.org/10.1016/j.otc.2014.06.005>
69. Orliaguet GA, Gall O, Savoldelli GL, et al. Case scenario: perianesthetic management of laryngospasm in children. *Anesthesiology*. 2012;116(2):458–71. <https://doi.org/10.1097/ALN.0b013e318242aae9>
70. Gavel G, Walker RW. Laryngospasm in anaesthesia. *Continuing Education in Anaesthesia Critical Care & Pain*. 2014;14(2):47–51. <https://doi.org/10.1093/bjaceaccp/mkt031>
71. Possamai V, Hartley B. Voice disorders in children. *Pediatr Clin North Am*. 2013;60(4):879–92. <https://doi.org/10.1016/j.pcl.2013.04.012>
72. Martins RH, Hidalgo Ribeiro CB, Fernandes de Mello BM. Dysphonia in children. *J Voice*. 2012;26(5):e17–20.
73. Parker G, Vyas H. Management of upper-airway obstruction in children. *Paediatrics and Child Health*. 2009;19(6):276–81. <https://doi.org/10.1097/00001665-200903.005>
74. Engelhardt T, Weiss M. A child with a difficult airway *Curr Opin Anaesthesiol*. 2012;25(3):326–32. <https://doi.org/10.1097/ACO.0b013e318283532ac4>
75. Schmidt AR, Weiss M, Engelhardt T. The paediatric airway. *Eur J Anaesthesiol*. 2014;31(6):293–9. <https://doi.org/10.1097/EJA.0000000000000023>
76. Isono S. Developmental changes of pharyngeal airway patency: implications for pediatric anesthesia. *Pediatric Anesthesia* 2006;16(2):109–22. <https://doi.org/10.1111/pan.2006.16.issue-2>
77. Keidan I, Fine GF, Kagawa T, et al. Work of breathing during spontaneous ventilation in anesthetized children: a comparative study among the face mask, laryngeal mask airway and endotracheal tube. *Anesthesia & Analgesia*. 2000;91(6):1381–8. <https://doi.org/10.1097/00000539-200012000-00014>
78. Von Ungern-Sternberg BS, Erb TO, Reber A, et al. Opening the upper airway—airway maneuvers in pediatric anesthesia. *Pediatric Anesthesia*. 2005;15(3):181–9. <https://doi.org/10.1111/pan.2005.15.issue-3>

79. Chua C, Schmölzer GM, Davis PG. Airway manoeuvres to achieve upper airway patency during mask ventilation in newborn infants—An historical perspective. *Resuscitation*. 2012;83(4):411–6. <https://doi.org/10.1016/j.resuscitation.2011.11.007>
80. Meier S, Geiduschek J, Paganoni R, et al. The effect of chin lift, jaw thrust, and continuous positive airway pressure on the size of the glottic opening and on stridor score in anesthetized, spontaneously breathing children. *Anesthesia & Analgesia*. 2002;94(3):494–9. <https://doi.org/10.1097/00000539-200203000-00004>
81. Bhat MT, Santhosh MCB, Hegde HV, et al. Anesthetic management of a child with Bardet-Biedl syndrome undergoing post-auricular dermoid excision. *J Anaesthesiol Clin Pharmacol* 2014;30(1):117–8. <https://doi.org/10.4103/0970-9185.125732>
82. Vlatten A, Soder C. Airtraq optical laryngoscope intubation in a 5-month-old infant with a difficult airway because of Robin Sequence. *Pediatric Anesthesia* 2009;19(7):699. <https://doi.org/10.1111/pan.2009.19.issue-7>
83. Wallace C, Engelhardt T. Videolaryngoscopes in paediatric anaesthesia. *Curr Treat Options Psychiatry* 2015;1(1):25–37. <https://doi.org/10.1007/s40746-014-0007-z>
84. Holm-Knudsen R. The difficult pediatric airway—a review of new devices for indirect laryngoscopy in children younger than two years of age. *Pediatric Anesthesia*. 2011;21(2):98–103. <https://doi.org/10.1111/j.1460-9592.2010.03487.x>
85. Mahfouz A, Rashid M, Reddy P. Anaesthetic management of congenital laryngeal web presenting with acute upper airway obstruction. *Middle East J Anaesthesiol*. 2010;20(5):719–21.
86. Reena AK, Singh SK, Agrawal V. Unsuspected subglottic web in a child managed for severe respiratory obstruction. *Saudi J Anaesth*. 2017;11(1):99. <https://doi.org/10.4103/1658-354X.197336>
87. Kamal K, Jaju PB, Jaju R, Paliwal B. Incidental laryngeal web: Look before you leap. *The Indian Anaesthetists Forum* 2016; 2016; 17:68–9. Medknow Publications.
88. Singh P, Khanna P. Incidental laryngeal web simulating intra-operative refractory bronchospasm. *Indian J Anesthesia*. 2013;57(1):82–3. <https://doi.org/10.4103/0019-5049.108580>
89. Russo SG, Becke K. Expected difficult airway in children. *Curr Opin Anaesthesiol* 2015;28(3):321–6. <https://doi.org/10.1097/ACO.0000000000000198>
90. Sola C, Saour A-C, Macq C, et al. Children with challenging airways: What about GlideScope® video-laryngoscopy? *Anaesth Crit Care Pain Med*. 2016; Article in press.
91. Karsli C, Armstrong J, John J. A comparison between the GlideScope® Video Laryngoscope and direct laryngoscope in paediatric patients with difficult airways—a pilot study. *Anaesthesia*. 2010;65(4):353–7. <https://doi.org/10.1111/j.1365-2044.2010.06294.x>
92. Kim J-T, Na H-S, Bae J-Y, et al. GlideScope(R) video laryngoscope: a randomized clinical trial in 203 paediatric patients. *Br J Anaesth*. 2008;101(4):531–4. <https://doi.org/10.1093/bja/aen234>
93. Nienaber L. Video laryngoscopy in paediatric anaesthesia in South Africa. *South. Afr. J. Anaesth. Analg*. 2011;17(6):363–9. <https://doi.org/10.1080/22201173.2011.10872807>
94. Abdelgadir I, Phillips R, Singh D, et al. Videolaryngoscopy versus direct laryngoscopy for tracheal intubation in children (excluding neonates). *Cochrane Database Syst Rev*. 2017, (5): Art. No.: CD011413.
95. Holm-Knudsen RJ, White J. The Airtraq may not be the solution for infants with difficult airways. *Pediatric Anesthesia*. 2010;20(4):374–5. <https://doi.org/10.1111/pan.2010.20.issue-4>
96. Jagannathan N, Sequera-Ramos L, Sohn L, et al. Elective use of supraglottic airway devices for primary airway management in children with difficult airways. *Br J Anaesth*. 2014;112(4):742–8. <https://doi.org/10.1093/bja/aet411>
97. Jagannathan N, Ramsey MA, White MC, et al. An update on newer pediatric supraglottic airways with recommendations for clinical use. *Pediatric Anesthesia*. 2015;25(4):334–45. <https://doi.org/10.1111/pan.2015.25.issue-4>
98. Asai T. Is it safe to use supraglottic airway in children with difficult airways? *Br J Anaesth*. 2014;112(4):620–2. <https://doi.org/10.1093/bja/aeu005>
99. Passi Y, Sathyamoorthy M, Lerman J, et al. Comparison of the laryngoscopy views with the size 1 Miller and Macintosh laryngoscope blades lifting the epiglottis or the base of the tongue in infants and children <2 yr of age†. *Br J Anaesth*. 2014;113(5):869–74. <https://doi.org/10.1093/bja/aeu228>

Received: 05-06-2017 Accepted: 12-09-2017