

A broken fenestrated tracheostomy tube fragment removed from the right main bronchus

Nic James Procter^{a*} and Caro Louw^a

^aFaculty of Health Sciences, Department of Anaesthesiology, School of Medicine, University of Free State, Bloemfontein, South Africa

*Corresponding author, email: nicprocteris@yahoo.co.uk

Aspiration of a broken tracheostomy tube fragment is a relatively rare complication with the potential to result in serious airway complications. Case reports of tracheal fragment aspiration have been documented infrequently in the past, with the earliest documented case in 1960. What follows is a case report of an 80-year-old male patient whose tracheostomy was replaced a year ago. While at home, the tracheostomy broke and the fragment lodged in his right main bronchus. He was unable to recall when the tracheostomy broke and only presented to the ear, nose and throat clinic for his annual follow-up appointment. The discussion highlights similar reported cases and emphasises some concerns regarding the long-term use of tracheostomies.

Keywords: airway, aspiration, complication, foreign body, tracheostomy tube

Case report

An 80-year-old male patient presented to the Ear, Nose and Throat (ENT) Clinic for an annual follow-up appointment. He is known to have a history of chronic smoking and obstructive pulmonary disease. Subsequently, a laryngeal carcinoma developed which was treated with chemo- and radiotherapy and a tracheostomy was inserted in 2005. Annual clinic visits proceeded without incident and a new size 6 fenestrated non-cuffed tracheostomy tube was issued at each clinic visit. At the current clinic visit, no new problems were reported and only a new tracheostomy tube was requested.

On examination, he appeared asymptomatic, had a hyper-inflated chest with bilateral equal air entry and was maintaining a saturation of 90% on room air. On removal of the tracheostomy tube, it was noted that the bottom segment of the tube had broken off. He was uncertain when the tracheostomy had severed. He did not report to any medical facility as his residence is far from any medical facility and the separated fragment did not appear to cause any problems. The removed broken tracheostomy was discarded; a new tracheostomy was inserted and chest radiographs were requested.

Chest radiographs postero-anterior view (Figure 1) and lateral view (Figure 2) revealed the end piece of the tracheostomy tube lodged in his right main bronchus. A bronchoscopy was attempted in the ENT clinic without success due to the patient coughing. Theatre was then booked for removal of the tracheostomy tube fragment under general anaesthesia.

Theatre was prepared for a difficult airway and it was confirmed that experienced assistance was immediately available if necessary. On arrival in theatre, the patient was placed in a Trendelenburg position with some right lateral tilt. An inhalation induction was administered through the tracheostomy and a quick look with the C-MAC[®] video laryngoscope (Karl Storz GmbH, Tuttlingen, Germany) revealed a fibrous trachea with an enlarged epiglottis. The vocal cords could not be viewed due to the enlarged epiglottis. The volatile anaesthetic was stopped and a total intravenous anaesthetic was begun followed by a

muscle relaxant. Adequate oxygenation was maintained with intermittent jet ventilation. The tracheostomy tube was removed, the stoma sealed with a gauze dressing and a rigid bronchoscope was inserted via the oral route. Due to scarring and fibrosis in the trachea from the radiotherapy, the carina could not be reached. After several unsuccessful attempts with manipulations of the head and the bronchoscope, an attempt was made to pass the rigid bronchoscope through the tracheostomy stoma. The carina and tracheostomy fragment could easily be viewed and the tracheostomy fragment was successfully removed. A relook with the bronchoscope after the fragment was removed revealed some inflammation with granulation tissue and no signs of sepsis. A new tracheostomy was inserted and the recovery of anaesthesia proceeded uneventfully. The patient was discharged from hospital the following day.

Discussion

A tracheostomy can be a lifesaving procedure. The first depiction of tracheostomy use occurs on Egyptian tablets dating back to approximately 3600 BC.¹ Many complications of tracheostomies have been reported and can be subdivided into three main categories: immediate, early and late. Late complications include: tracheal stenosis, tracheomalacia, tracheoinnominate-artery erosion, tracheoesophageal fistula, pneumonia and aspiration.² Cases of tracheostomy fragments that have broken off and migrated into the bronchus have also been reported, although more rarely, with the first report in 1960 by Bassoe and Boe.³ The youngest reported age at which a tracheostomy tube broke and migrated into the bronchus is reported in a baby of 12 months.⁴ A similar case documented a tracheostomy breaking 8 hours after insertion in a 14-month-old girl following a bout of coughing.⁵

The clinical presentation of patients with aspirated tracheostomy tube may vary. The most severe presentation is acute respiratory distress and usually manifests as a result of the tube blocking the carina or bronchus or the tube itself becoming blocked. A case has been reported where ventilation was stabilised after pushing the tube fragment into the left main bronchus.⁶ In most of the reported cases patients were asymptomatic. This could be

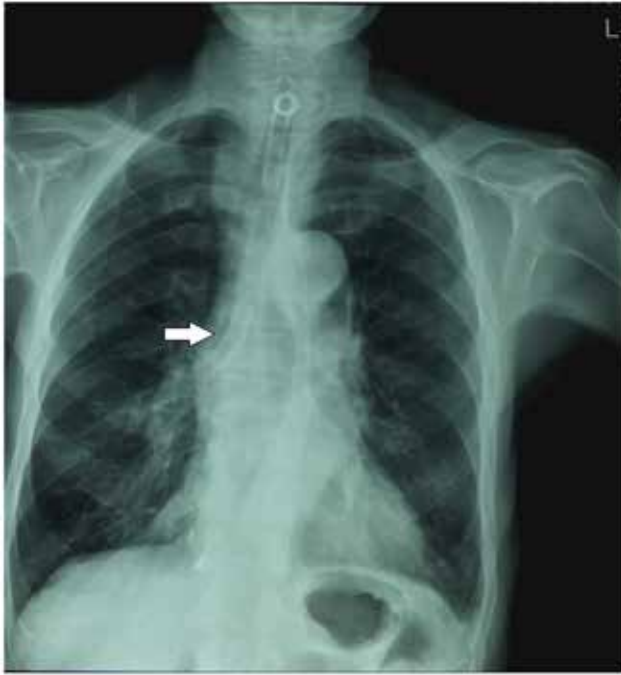

Figure 1: Chest X-ray postero-anterior view showing the fragment of the tracheostomy in the right main bronchus.

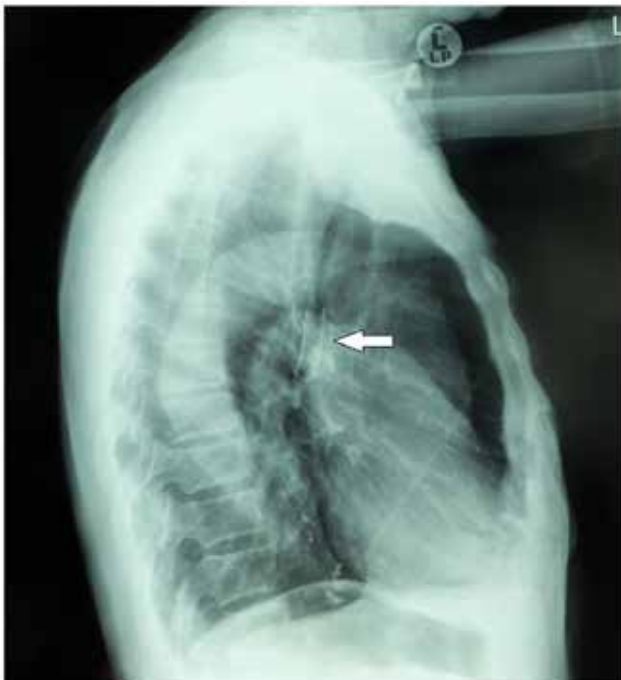


Figure 2: Chest x-ray lateral view showing the fragment of the tracheostomy tube and signs of chronic obstructive lung disease.

attributed to the tubular nature of the tracheostomy. Some prolonged cases have been reported with tracheostomy fragments being in situ for up to eight years.⁷ Most patients in whom the tracheostomy tube fractured were reported to have been using their tracheostomy tubes for a prolonged period of time. In our case, the tracheostomy tube had lodged in the right main bronchus for an unknown duration and had not obstructed the entry to the right upper lobe of the lung, which is usually situated 2.3 ± 0.7 cm from the carina in males.⁸

Tracheostomy tubes are composed of various materials: metals – copper, silver, steel, nickel, zinc, polyvinyl chloride (PVC) and silicone.⁹ Multiple factors contribute to the weakening and breaking of tracheostomy tubes. Chemical factors include corrosive cleaning solutions and weakly corrosive alkaline bronchial secretions. Basic carbonates are formed by the action of the alkaline bronchial secretions which result in green deposits on the metal tracheostomy tubes and cause erosion. Mechanical factors include repeated removal and reinsertion, cleaning and boiling. Other factors include manufacturing defects and failure to inspect the tube adequately by the patient or caregiver and missing follow-up appointments to change the tube.^{4,10} The majority of case reports of fractured tracheostomy tubes have been metallic tubes, which are washed and boiled making them more suitable for prolonged use.⁹

Potential sites of weakness in the tracheostomy tube include the junction between the tracheostomy neck plate and the tracheostomy tube, and at the site of the tracheostomy tube fenestration.¹¹ In most of the cases of a fractured tracheostomy tubes, the fracture occurred at the junction site between the neck plate and the tracheostomy tube (Figure 3), with very few reports occurring at the fenestration site.¹¹ The purpose of the fenestration is to permit air flow through the vocal cords, allowing the patient to speak when the tracheostomy opening is occluded. In our case, it can be seen from the fragment that was removed that the outer tracheostomy sheath had broken at the fenestration site and the inner tube had broken at the junction of the tracheostomy tube and the neck plate (Figure 4).

In cases in which the tracheostomy has been used for a prolonged period of time, a high index of suspicion is necessary for the diagnosis as the patient can often be misdiagnosed as having an airway infection. Confirmation of the position of the fragment can be done with chest radiograph – tracheostomy tubes are radio-opaque – or by computed tomography.

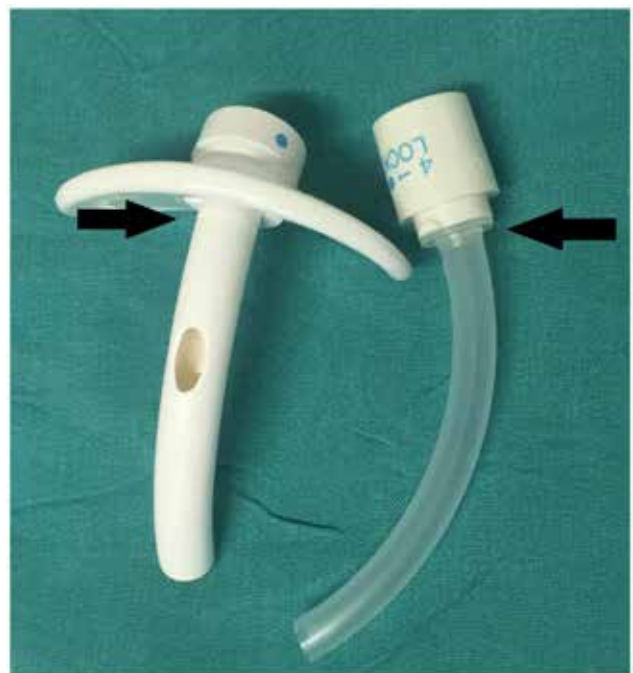

Figure 3: A PVC fenestrated non-cuffed tracheostomy tube similar to the one which fractured. Arrows indicate the junction site between the neck plate and tracheostomy tube, where a fracture is most likely to occur.

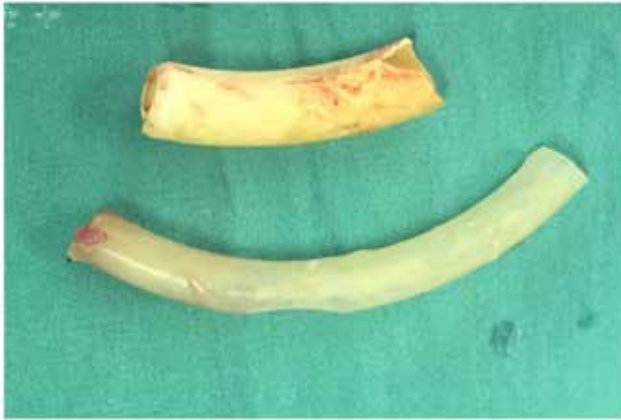

Figure 4: The fragment of the tracheostomy tube removed consisting of two fragments: the outer sheath, which fractured at the site of the fenestration, and the inner tracheostomy tube, which fractured at the junction of the neck plate and tracheostomy tube.

Various techniques have been described regarding the removal of a tracheostomy fragment; the ideal technique is by direct vision, with the use of a bronchoscope. In most cases, general anaesthesia was performed and one case reported using conscious sedation.¹¹ If the fragment is still in the upper trachea, it may be removed with a pair of forceps through the tracheostomy stoma. Deeper fragments may require a rigid bronchoscopy, which may be inserted orally or through the tracheostomy stoma site. In one case, a technique was described using a Foley catheter to remove a tracheostomy fragment and in another case a thoracotomy was required as the fragment had eroded through the trachea.¹² Femorofemoral cardiopulmonary partial bypass can be considered in patients with failure to oxygenate if the situation permits. One case was reported where a child died before it was possible to remove the tracheostomy fragment as the child had a severe tracheal stenosis and the aspirated fragment occluded the carina.¹⁰

It is not uncommon for patients with chronic conditions to be discharged home with tracheostomy tubes in situ. A fractured tracheostomy tube is a preventable complication and patient education is key in avoiding such a complication. New tracheostomy tubes should be inspected for manufacturing faults before insertion and reused tubes should be inspected routinely for signs of wear and tear and replaced when necessary.¹¹ A spare tube should be available for the patient to change at home if there are signs of ageing on the tube. In cases where a general anaesthetic is necessary for tracheostomy fragment removal, there should be good cooperation from the patient, sufficient pre-oxygenation before induction of anaesthesia and the presence of experienced personnel.¹⁰

Funding – No funding offered or received

Acknowledgements – The authors would like to thank Dr Tammy Daniller and Dr Cherice Ferris, the ear nose and throat surgeons who performed the case.

Authors contributions

NP: literature review, clinical and anaesthesia information retrieval, conduct of anaesthesia, writing of manuscript; CL: conduct of anaesthesia, review of clinical and anaesthetic data and editing the manuscript.

Declaration of interests

None declared.

References

1. Chung NH, Napolitano LM. Tracheostomy: epidemiology, indications, timing, technique and outcomes. *Respir Care*. 2014 Jun;59(6):895–9.
2. Epstein SK. Late complications of tracheostomy. *Respir Care*. 2005;50(4):542–9.
3. Bassoe H, Boe J. Broken tracheostomy tube as foreign body. *Lancet*. 1960 May;1(1732):1006–7.
4. Parida PK, Kalaiarasi R, Gopalakrishnan S, et al. Fractured and migrated tracheostomy tube in the tracheobronchial tree. *Int J Pediatr Otorhinolaryngol*. 2014;78:1472–5. <http://dx.doi.org/10.1016/j.ijporl.2014.06.011>
5. Chang-Teng W, Jainn-Jim L, Reming Y. Migration of fragmented tracheostomy tube into left main bronchus. *Int J Pediatr Otorhinolaryngol*. 2007;2:58–60.
6. Kantar B, Uzumcugil F, Ankey Yilbas A, et al. Emergency management of aspirated tracheostomy cannula. *Eur J Anaesthesiology*. 2014 June; 31:269.
7. Agarwal N, Agarwal R. Fractured tracheostomy tube migrating into the tracheobronchial tree: a rare complication. *Indian J Chest Diseases Allied Sci*. 2011;53:111–2.
8. Barash PG, Cullen BF, Stoelting RK, et al. editors. *Clinical anaesthesia*. 7th ed. Philadelphia: Wolters Kluwer; Lippincott Williams & Wilkins Publishing; 2013.
9. Krishnamurthy A, Vijayalakshmi R. Broken tracheostomy tube: a fractured mandate. *J Emergencies Trauma Shock*. 2012 Jan–Mar;5(1):97–9.
10. Lynrah ZA, Goyal S, Goyal A, et al. Fractured tracheostomy tube as foreign body bronchus: our experience with three cases. *Int J Pediatr Otorhinolaryngol*. 2012;76:1691–5. <http://dx.doi.org/10.1016/j.ijporl.2012.07.033>
11. Krempel GA, Otto RA. Fracture at fenestration of synthetic tracheostomy tube resulting in a tracheobronchial airway foreign body. *South Med J*. 1999 May;92(5):526–8.
12. Rajesh MS, Bisht SS, Aggarwal V, et al. Foley's catheter technique for removal of fractured polyvinyl chloride tracheostomy tube in a difficult case. *Int J Otorhinolaryngology*. 2006;5(2):111–2.

Received: 26-04-2016 Accepted: 30-09-2016