

Human immunodeficiency virus and the airway

Analee Milner

University of the Witwatersrand

Department of Anaesthesia, Charlotte Maxeke Johannesburg Academic Hospital, Johannesburg

Author e-mail: analee.milner@iafrica.com

Seventy-five to one hundred per cent of patients with human immunodeficiency virus (HIV)/acquired immune deficiency syndrome (AIDS) have a head and neck manifestation. These manifestations may impact on anaesthetic management, but more importantly often allow the anaesthetist to diagnose the disease before the patient or the surgeon may be aware of possible contagion. Immune compromise, arising from the onslaught of CD4 cells, results in severe infections (overwhelming fungal and bacterial) and cancers. Vasculitides also become prevalent, resulting in bizarre unpredictable manifestations such as aneurysmal formation in the vessels of young patients, and bleeding or clotting diathesis in all ages. The World Health Organization classification, based on specific pathology, allows for accurate clinical staging of the disease. Grave concerns for the anaesthetist are the constant threat of needle-stick injuries and the contraction of tuberculosis, which is becoming resistant to treatment. It should be noted that many of the signs and symptoms described herein will be attenuated or absent once the patient is on antiretroviral therapy (ART). However, in South Africa, only 500 000 of an estimated five million patients infected with HIV are receiving ART. Therefore, it is still of value to recognise and understand the pathology caused by degrees of immune compromise from HIV/AIDS. Ironically, ART may impact on the airway owing to immune reconstitution inflammatory syndrome and lipodystrophy.

Keywords: AIDS, ART, airway, head and neck manifestation, HIV, human immunodeficiency virus

Introduction

Sub-Saharan Africa and other areas of the world are facing the biggest chronic pandemic known to modern man. The estimated infected number of patients with human immunodeficiency virus (HIV)/acquired immune deficiency syndrome (AIDS) is growing, although the rate has now peaked.¹ At any stage of the disease, 75–100% of patients with HIV/AIDS have a head and neck manifestation.² Anaesthetists are especially vulnerable, as they come into contact with contaminated blood and body fluids, but they also have to manipulate and maintain a compromised airway. Therefore, it is imperative to note and recognise important clinical signs. Although gloves and masks should be worn routinely when administering anaesthesia, a knowledge or high index of suspicion of HIV/AIDS infection is preferable to protect healthcare workers in theatre.^{3,4} The immune-compromised patient also benefits from stricter asepsis control.

HIV is a lentivirus of the retrovirus family. It is unique as it contains two enzymes, reverse transcriptase and viral integrase, which allow for incorporation of the host's DNA into the virus' mRNA, allowing replication of the invader virus. In the process, the host CD4 cells, which normally augment and orchestrate an immune response in the host, are destroyed. It follows that the lower the CD4 count, the worse the patient's overall immunity. This means that there is overgrowth of opportunistic and other infections, as well as vasculitis and the exacerbation of cancer. Therefore, a CD4 count may be used to stage the severity of the disease (not reliable in children) (Table 1).⁵

It is not always possible to obtain laboratory confirmation of either the disease, or a CD4 count, in the developing world. Oral fungal colonisation, one of the most common opportunistic observed infections in adults and children with HIV, is of more prognostic value.⁶ Oral mucosal lesions alone are poor

Table 1: Health of immune system correlated with CD4 cells²

CD4+ positive cell count/l	CD4+ percentage	The immune system
> 500	> 29	Normal immune system
200–499	14–28	Moderate immune suppression
< 200	< 14	Advanced immune suppression
< 50		Severe

predictors of HIV infection in populations where the prevalence of HIV is low. But oral lesions indicate HIV infection and enable staging of the disease in areas of high prevalence. These lesions parallel a decline in the number of CD4 cells and an increase in the viral load, and are independent indicators of the presence of HIV infection.⁷ Oral lesions may also be used to evaluate the entry or end-points in therapy and/or vaccine trials. The World Health Organization (WHO) has staged this disease according to clinical severity (Table 2). For the sake of simplicity, this article will only discuss head and neck pathology. Table 3 highlights the pathology that will be discussed in more detail.

Infections

Cutaneous

Severe facial rashes are commonly seen in HIV/AIDS patients. These manifestations range from severe acne to other dermatitides, and probably relate to the degree of immunocompromise. Seborrhoeic dermatitis is very common and involves the face and scalp, and can also affect the external ear.⁸ Candidiasis in the corners of the mouth (cheilitis or perleche) is almost pathognomonic in South African practice (Figure 1). The only relevance to the anaesthetist is that the anaesthetic face mask may cause the skin to further excoriate and bleed.

Table 2: The World Health Organization clinical staging system for human immunodeficiency virus⁸

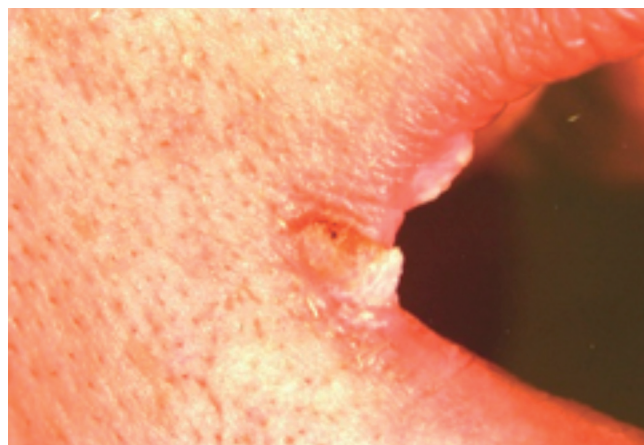
WHO stage 1	Acute retroviral infection Asymptomatic infection Persistent generalised lymphadenopathy* <i>Performance scale 1: Asymptomatic with normal activity</i>
WHO stage 2	Weight loss < 10% of body weight Minor mucocutaneous manifestations* Herpes zoster shingles* Recurrent upper airway infections* <i>Performance scale 2: Symptomatic with normal activity</i>
WHO stage 3	Weight loss > 10% of body weight Unexplained chronic diarrhoea > 1 month Oral candidiasis* Vulvovaginal candidiasis Oral hairy leukoplakia* Pulmonary tuberculosis* Severe bacterial infections* <i>Performance scale 3: In bed < 50% of normal daytime during the past month</i>
WHO stage 4	AIDS-defining conditions Cancers Lymphoma* Kaposi's sarcoma* Invasive cervical carcinoma Bacteria Extrapulmonary tuberculosis* Atypical mycobacteriosis* <i>Pneumocystis carinii</i> pneumonia* Recurrent pneumonia* <i>Salmonella</i> septicaemia Toxoplasmosis Fungal infections Candidiasis of the trachea and oesophagus, bronchi and lungs* Cryptosporidiosis Other systemic mycosis Viral infections Cytomegalovirus Herpes simplex virus ulceration > 1 month* HIV encephalopathy Vasculitis Atypical multiple aneurysms* Other Progressive multifocal leukoencephalopathy HIV wasting <i>Performance scale 4: In bed > 50% of daytime during the past month</i>

AIDS: acquired immune deficiency syndrome

HIV: human immunodeficiency virus

WHO: World Health Organization

* Head and neck pathology

**Figure 1:** Cheilitis at the corners of the mouth (Source: Department of Maxillo-Facial Surgery, University of Pretoria)**Table 3:** Classification of resultant head and neck manifestations

Infections
Cutaneous
Oropharyngeal
Respiratory tract infections
Expanding head and neck manifestations
Lymphadenopathy
Cancers
Ludwig's angina
Aneurysms

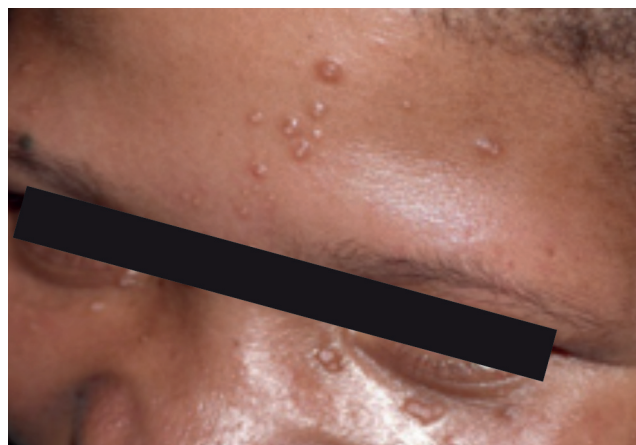As the name suggests, *Molluscum contagiosum* is extremely contagious, and the face may be heavily infected. Hand gloves are essential during contact with these patients (Figure 2).

Oropharyngeal manifestations

Oral candidiasis

A clinic in Lesotho reports that 75% of patients with HIV/AIDS have oral lesions.⁹ Oral candidiasis has been consistently reported as the most prevalent HIV-associated oral lesion (54%) in all age groups.^{7,10,11} Oral candidiasis may be a presenting sign of HIV, and becomes grossly exaggerated as the immune system is further compromised.¹² Children have immature immune systems and potential suppressed cellular immunity. Therefore, candidial overgrowth may become so extensive around the laryngeal framework that upper airway obstruction may necessitate intubation and ventilation in the intensive care unit.^{13,14} Children and adults may also develop epiglottitis. It should also be noted that even seemingly innocuous oral presentation, structures such as the larynx, trachea, bronchi and oesophagus (in 20-40% of AIDS patients), can be heavily contaminated (Figure 3). These patients often present with intense dysphagia, severe odynophagia, chest pain and hoarseness, and sometimes stridor and aspiration.¹⁵ This pain is caused by pseudomembranes, erosions and ulcers on the oesophageal and bronchial mucosa. Strictures of both the bronchi and oesophagus are common in these patients, and the pathogenesis of the fibrosis is thought to be due to a chronic inflammatory response within the mucosa from toxins and enzymes secreted by the fungus.¹⁵

Oral hairy leukoplakia (OHL) on the lateral side of the tongue is caused by the Epstein-Barr virus (EBV). These lesions cannot be scraped off the mucosa. OHL is not seen often in South Africa,

**Figure 2:** Molluscum contagiosum (Source: Department of Maxillo-Facial Surgery, University of Pretoria)

but is prevalent in the USA. South Africa is thought to have a different strain of HIV. OHL signifies a poorer prognosis, as it usually heralds a lower CD4+ count and a sharp increase in viral load. Eighteen per cent of patients will seroconvert to full blown AIDS within 18 months.¹⁰

Oral ulcers

These ulcers are common, manifesting because of either infection (herpes simplex and varicella zoster) or an abnormal immune response (giant aphthous ulcers). Aphthous ulcers are precipitated by psychological and socio-economic trauma and nutritional deficiencies.^{6,7,11} It is relevant to the anaesthetist that when these ulcers are giant and multiple, they signal disease progression. Patients presenting in theatre may be debilitated and dehydrated as eating and drinking may cause extreme pain. Long-standing herpetic ulcers that persist for one month or more are also indicative of advanced disease.^{10,16}

Human immunodeficiency virus-associated gum disease

HIV-associated gingivitis is prevalent. The final stage of gingivitis is periodontal disease with bone re-absorption, resulting in loose teeth. A straightforward endotracheal intubation may result in teeth simply falling out of their sockets.⁹ The patient often also presents to the doctor because of bleeding gums and petechiae on the entire oral mucosa. Ten per cent of HIV patients and 33% of AIDS patients have chronic thrombocytopenia. The pathogenesis of thrombocytopenia in HIV is multifactorial, involving both defects in platelet production (late disease) and accelerated platelet destruction (early disease).^{17,18} Clinically, HIV-related thrombocytopenia (HIV-TP) is similar to immune thrombocytopenia, but only 8% of patients with HIV-TP have severe bleeding, despite very low platelet counts.¹⁷ The reason for this may be the presence of thrombotic microangiopathy in HIV disease.¹⁹⁻²² Therefore, in endemic areas, the anaesthetist should always check for oral petechiae prior to placing nasoendotracheal tubes or neuraxial blocks. Major elective surgery should not be performed in thrombocytopenic patients unless platelets are available.

Upper respiratory tract infections

Inflammation in lymphoid tissue in Waldeyer's ring

Hypertrophy of lymphoid tissue in Waldeyer's ring (adenoidal, tonsillar and lingual tonsillar lymph tissue) is very prevalent in children with HIV/AIDS, and may cause dysphagia and obstructive sleep apnoea, as well as total airway obstruction in some cases.²³ Adults rarely have adenoidal tissue, but in the early stages of HIV infection the prevalence ranges from

56–88%. As the disease progresses, patients are no longer able to mount an immune response and the adenoids disappear. Care should be taken with the passing of nasogastric, endotracheal and temperature probes through the nose.

Sinusitis

Sinusitis is prevalent and may be severe. It may be acute or chronic, with or without mucopurulent postnasal discharge. Aggressive sinonasal disease may be caused by opportunistic infections of aspergillosis and mucormycosis, both of which have the affinity to invade blood vessels. Chronic sinusitis is defined as a persistent infection lasting 12 weeks or more, and correlates with a CD4+ count of below 200/mm³. The placement of nasogastric and nasal endotracheal tubes should be avoided.²⁴

Laryngeal tuberculosis

Co-infection with HIV and tuberculosis is not uncommon. Patients with laryngeal tuberculosis usually present with hoarseness. As tuberculosis is known as the "great masquerader", these lesions often appear to be a malignancy, and direct laryngoscopy is scheduled for theatre. This is a threat to the entire team, as the usually untreated lesion is highly contagious.

Laryngeal tuberculosis lesions are not uniform. However, the posterior commissure is often affected. The entire region may be oedematous, with bulky arytenoids and a greyish exudate over the vocal cords which appears to be moth-eaten. Granulomatous lesions are also frequently seen²⁵ (Figure 4).

Deep cervical neck abscesses (Ludwig's angina)

Deep cervical neck abscesses are discussed in the section on expanding neck masses.

Lower respiratory tract infections

Pulmonary tuberculosis

Pulmonary tuberculosis is the scourge of our time, and the explosion of cases in recent years is undoubtedly a consequence of the uncontrolled HIV epidemic in the last two decades of the previous century. South Africa has one of the highest infectivity rates of *Mycobacterium tuberculosis* in the world. The spread of *M. tuberculosis* in the general population has exponentially risen with increased immunosuppression from HIV.²⁶ In addition, *Mycobacterium* resistance [multidrug-resistant tuberculosis (MDR-TB) or extensively drug-resistant tuberculosis (XDR-TB)] is increasing.^{27,28} Co-infection with HIV

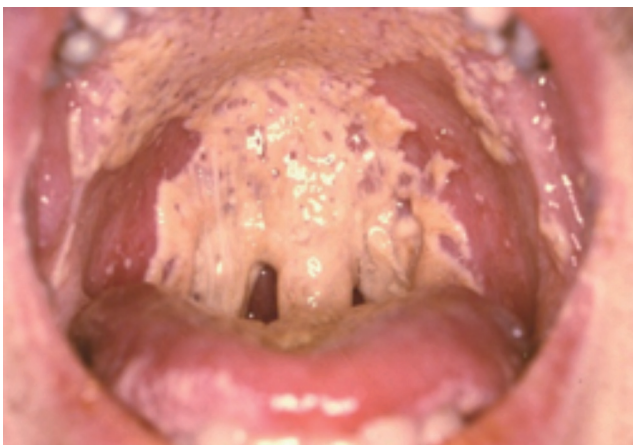

Figure 3: Candidiasis of the mouth (Source: Department of Maxillo-Facial Surgery, University of Pretoria)

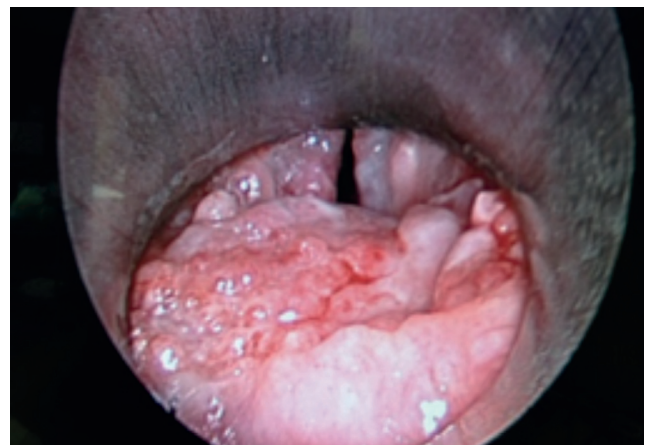

Figure 4: Laryngeal tuberculosis (Source: Department of Maxillo-Facial Surgery, University of Pretoria)

and tuberculosis causes the exacerbation of both diseases, while the toxic effects and interactions of drug therapy may add to mortality and morbidity.²⁹⁻³³ Healthcare workers in South Africa who have been exposed to MDR-TB and XDR-TB appear to have a higher infectivity rate than the general population. Coughing is a physiological reflex designed to clear the respiratory tract of debris, including infectious material, and is an extremely efficient way of initiating an aerosol-airborne infection.³⁴ The cough-generated aerosol particles of patients with open untreated pulmonary tuberculosis may be > 10 colony-forming units (CFUs), and as these bacilli are large, with a short trajectory, they may remain suspended in the atmosphere for up to six hours or longer. Possibly, tuberculosis bacilli may accumulate around the patient's head where the anaesthesiologist, surgeon and nurses are standing. An additional concern is that tuberculosis has always been known as the "great masquerader", and cases that have been assumed to be malignancies or simple infections have been proved to be "open" pulmonary tuberculosis. Personal protective equipment, such as N95[®] face masks, may not be in place or effective. Therefore, theatre air conditioning units and filters need to adhere to strict WHO guidelines, and research should be carried out on additional filtering in theatre.^{35,36}

The chest X-ray picture of a patient with pulmonary tuberculosis, co-infected with HIV may not appear to be similar to that traditionally seen with tuberculosis.³⁷

Expanding head and neck masses

Ninety-one per cent of HIV-infected patients have an enlarged neck mass. The evaluation of neck mass in this population is complicated by the frequent presence of opportunistic pathogens and neoplasms that are unique to HIV infection. These masses can be classified into four categories, namely HIV lymphadenopathy and parotid disease; infectious processes resulting in deep cervical neck abscesses (Ludwig's angina); neoplasms; and aneurysms caused by vasculitis.²⁴

Lymphadenopathy and parotid enlargement

In the early stages of the disease, persistent generalised lymphadenopathy and parotid enlargement may be seen. Persistent generalised lymphadenopathy is classified as the presence of lymphadenopathy in two sites other than inguinal for a period longer than six months. Initially, in early HIV infection, a prodromal flu-like illness occurs, but during the seroconversion phase, 70% of patients develop persistent generalised lymphadenopathy.^{2,24} Lymph nodes may be visible in the posterior triangle and the submental areas. The lymphadenopathy disappears as the immunity progressively weakens and the architecture of the lymph nodes becomes destroyed in the later stages of the disease. Obvious lymphadenopathy (scrofula) may also be an extrapulmonary tuberculosis manifestation.

Uni- or bilateral parotid enlargement, also an early presenting sign in HIV, occurs because of exaggerated lymphoepithelial cyst formation within the capsule of the gland, and is strongly associated with persistent generalised lymphadenopathy.⁹ The resultant square-looking face has no clinical significance other than alerting clinicians to possible HIV infection, and the possibility of this being cosmetically unacceptable to the patient (Figure 5).²⁴

Infectious processes

Deep cervical abscesses in the neck (Ludwig's angina)

Ludwig's angina is always a concern, even in healthy patients, as gross swelling around the face and neck may make endotracheal intubation hazardous. However, the problem may be compounded by massive abscesses extending to the arm and chest wall in immune-compromised patients. A review by Ovassapian et al³⁸ recommends that adults with cervical abscesses undergo an awake tracheal intubation using a flexible bronchoscope. The experience in our institution confirms the success of this technique. These patients often have a copious amount of pus and saliva pouring from their mouths. These secretions not only impede visualisation with the flexible bronchoscope, but also dilute the local anaesthetic, resulting in inadequate topicalisation of the oral, pharyngeal and laryngeal mucosa. Aggressive suctioning and the use of an antisialagogue, at least 15 minutes prior to topicalisation, is essential. Technically, an awake tracheostomy is usually difficult as up to 15 cm of indurated tissue may overlie the trachea.

Bulk tumours

Tumours around the head and neck are not uncommon, and invariably threaten airway patency and management. The reason may be that HIV replicates, using a DNA intermediate that integrates into the host's chromosomal DNA, and therefore makes the virus inherently mutagenic. Existing tumours are also exacerbated owing to poor immunity.

Lymphomas, sarcomas and carcinomas are commonly mentioned in HIV/AIDS literature. The incidence of lymphomas may be increased 60- to 200-fold in HIV-positive individuals. Non-Hodgkin's lymphoma, although only present in 4% of infected patients, is an AIDS-defining illness. The pathogenesis of non-Hodgkin's lymphoma remains obscure, but there has been considerable interest in the role of the EBV as 50% of AIDS-related tumours demonstrate EBV genomes. Survival rates are low.^{39,40} Although only 3% of all non-Hodgkin's lymphoma occurs in the oral cavity, the impact on the airway may be extreme. The clinical appearance varies, but often presents as a rapidly enlarging mass associated with bony destruction.

Classical Burkitt's lymphoma, which accounts for 30% of AIDS-related lymphomas, is the other relatively common lymphoma seen around the head and neck region. In contrast to other AIDS-related lymphomas, it often occurs early in the course of the HIV infection. These tumours grow to an enormous size, and the bulk mass around the jaw may cause major airway management problems.⁴¹

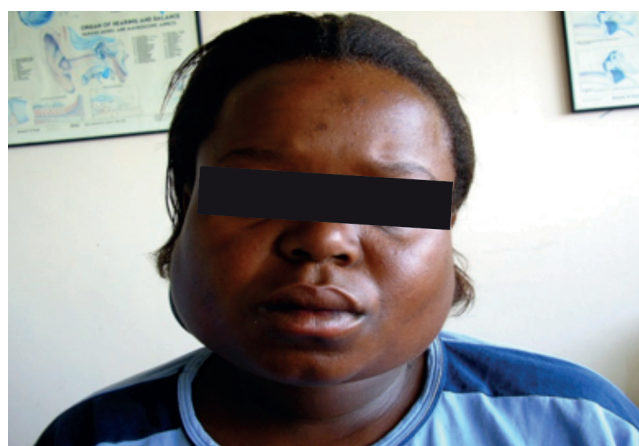

Figure 5: Bilaterally enlarged parotid glands result in a square-shaped face (Source: Department of Maxillo-Facial Surgery, University of Pretoria)

Kaposi's sarcoma

This is the most common malignancy observed in patients with AIDS. Kaposi's sarcoma may start off as a flat lesion, and rapidly grow into a large haemorrhagic tumour.⁴²⁻⁴⁴ Other cutaneous Kaposi's sarcoma may be a clue to respiratory tract involvement. Two thirds develop around the head and neck, and 20% in the respiratory tract where 65% occur around the supraglottic area, 47% around the glottis, and 18% infraglottically. Therefore, airway impairment and compromise depends on the location of the lesion. The anaesthetist may be unable to view the larynx owing to the bulk mass effect or due to uncontrollable bleeding resulting from instrumentation. Awake tracheostomy is advisable if the tumour is causing respiratory distress, or if potential haemorrhage is a consideration (Figure 6).

An otolaryngoscopy consultation is advisable, as well as a detailed upper and lower respiratory tract history and examination. An attempt should be made to shrink the tumour prior to an elective procedure using chemotherapy, thalidomide and radiation.^{45,46}

Other carcinomas may grow and disseminate more rapidly in infected patients. Compared to the general population, HIV-infected patients are more likely to develop basal cell and squamous carcinomas. Squamous cell carcinomas seem to have a predilection for developing in the head and neck region and present later in HIV. Basal cell carcinomas present more frequently on the trunk, and are seen throughout the disease.

Vasculitis^{4,6}

The relationship between vascular disease and HIV infection is well documented. The precise pathogenesis of the vasculitis is still unclear. HIV-related aneurysms have several histological features that distinguish them from degenerative and infective aneurysms. The principal feature is occlusion of the *vasa vasorum* by inflammatory cell infiltrate. However, the precise mechanism for HIV-related disease is still unclear. A hypothesis exists of bacteraemia resulting in immune depression, with secondary mycotic aneurysms or weakening of the arterial wall, caused by the direct action of the virus itself or by immune-complex mechanisms, or by ischaemia of the vessel wall resulting from occlusion of the *vasa vasorum*.⁴⁷

Clues that are suggestive of vasculitis are:

- Younger patients presenting with HIV-related vascular disease.
- The absence of risk factors for atherosclerosis.
- Multiple aneurysms and other features of immunodeficiency.

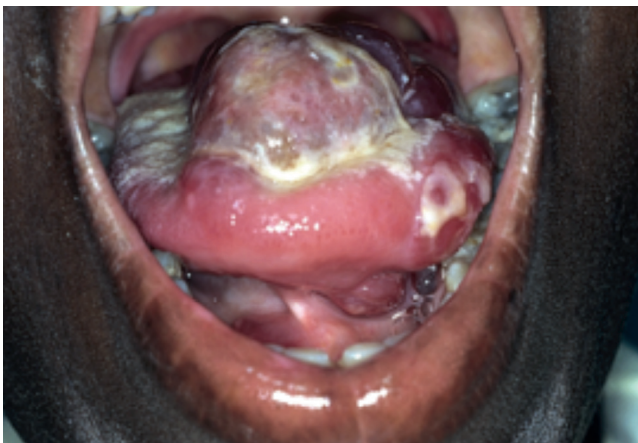

Figure 6: Kaposi's sarcoma of the tongue (Source: Department of Maxillo-Facial Surgery, University of Pretoria)

Vessel wall aneurysms appear to have a predilection for carotid arteries (Figure 7), and there is a danger that these patients will be booked for incision and drainage for what appears to be a bacterial abscess.

Airway compromise resulting from HIV treatment with antiretroviral therapy

Although ART has unequivocally saved millions of lives, paradoxically it may cause airway compromise.⁴⁸ After the initiation of ART, the CD4+ cell count begin to rise, reactivating the immune system. This results in rapid lymph node enlargement in the neck, which may cause airway embarrassment. This phenomenon is known as immune reconstitution inflammatory syndrome.^{49,50}

ART is also known to cause lipodystrophy or abnormal fat distribution.⁵¹ This pathology occurs in ~ 33% of patients.

Factors that influence the onset are:

- The duration of the drug therapy.
- Stavudine therapy.
- Zidovudine therapy.
- Protease inhibitors: These cause dyslipidaemia, but rarely morphological changes.

It is common for facial wasting to occur, making it difficult for the face mask to be placed. The extreme buffalo hump that forms at the base of the neck may hamper endotracheal intubation.

Declaration — Patients who receive treatment from the Department of Maxillo-Facial Surgery, University of Pretoria, have to sign consent allowing photographs of their pathology to be used for teaching.

Conclusion

The anaesthetist is uniquely positioned to detect manifestations of HIV/AIDS around the head and neck. Although the anaesthetic course is unlikely to change for most patients, the manifestations may provide a clue with regard to the patient's HIV status. Airway management may be difficult in some patients owing to bulk masses, such as tumours, infections and aneurysms. At times, it may even be life threatening. It has to be remembered that this disease has other systemic effects, such as cardiac, pulmonary, haemopoietic and central nervous system manifestations, and that these may influence the outcome of anaesthesia.

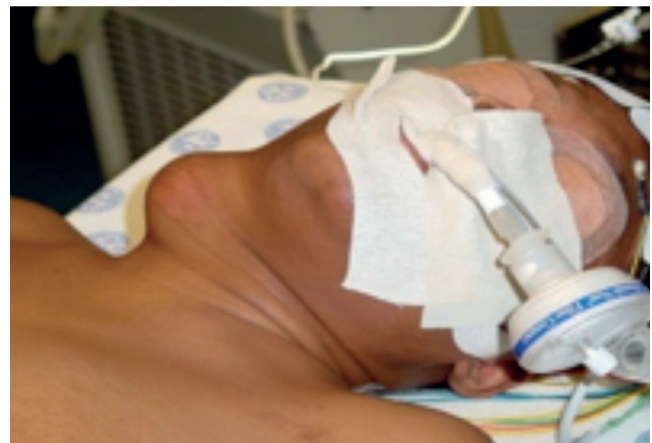

Figure 7: Carotid artery aneurysm in a young woman (Source: Department of Maxillo-Facial Surgery, University of Pretoria)

The risk of contracting tuberculosis is the most pressing concern for the modern-day anaesthetist. This disease is exponentially rising and becoming resistant to treatment. Traditional methods of protection that rely on circulating air (air conditioning) with filters may now no longer be adequate. Particulate respirators (N95[®]) masks, if appropriately sized and positioned correctly, will filter 99.5% of mycobacteria. However, these masks require a "fit test" to ensure a tight seal, and are extremely uncomfortable to wear for a prolonged period.⁵²

References

- Sheldon JD, Halperin DT, Wilson D. Has global HIV incidence peaked? *Lancet*. 2006;367(9517):1120–1122.
- Wald E. Airway complications in patients with infection caused by HIV. *Int Anaesthesiol Clin*. 1997;35(3):159–169.
- Avidan MS, Jones N, Posniak AL. Review: the implications of HIV for the anesthetist and intensivist. *Anaesthesia*. 2000;55(4):344–354.
- Berry A. Needle stick injuries and other safety issues. *Anesthesiology Clin North Am*. 2004;22(15):493–508.
- Botes ME. Review: the management of HIV: a practical approach. *Professional Nursing Today*. 2004;8(1):14.
- Rabnis C. Looking into the mouth -Oral manifestations of HIV infection. *Professional Nursing Today*. 2003;7(4):13–17.
- Coogan M, Greenspan J, Chalacombe SJ. Oral lesions in infection with human immunodeficiency virus. *Bull World Health Organ*. 2005;83(9):700–706.
- Moazzez AH, Alvi A. Head and neck manifestations of AIDS in adults. *Am Fam Physician*. 1998;57(8):1813–1822.
- Kamuri HH, Naidoo S. Oral HIV lesions and oral health behaviour in HIV-positive patients attending the Queen Elizabeth II Hospital, Maseru, Lesotho. *SADJ*. 2002;57(11):479–482.
- Adendorf TM, Bredekamp B, Cloete CA, Sauer G. Oral manifestations of HIV infection in 600 South African patients. *J Oral Pathol Med*. 1998;27(4):176–179.
- Chapple IL, Hamburger J. The single significance of oral health in HIV disease. *Sex Transm Inf*. 2000;76(4):236–243.
- Feller L, Buskin A, Blignaut E. A review of candida and periodontal disease in immunocompetent and HIV-infected subjects. *SADJ*. 2005;60(4):152–154.
- Lal S, Chusid S. Oral candidiasis in paediatric HIV patients. *N Y State Dent J*. 2005;71(2):28–31.
- Sharma N, Berman DM, Scott GB, Josephson G. Candida epiglottitis in an adolescent with acquired immunodeficiency syndrome. *Pediatr Infect Dis J*. 2005;24(1):91–92.
- Patton LL, Phelan JA, Ramoz-Gomez FJ, et al. Prevalence and classification of HIV-associated oral lesions. *Oral Dis*. 2002;8 Suppl 2:98–109.
- Itin PH, Lautenschlager S. Viral lesions in the mouth of HIV-infected patients. *Dermatology*. 1997;194(1):1–7.
- Scaradavou A. HIV-related thrombocytopenia. *Blood Rev*. 2002;16(1):73–76.
- Torre D, Pugliese A. Platelets and HIV-1 infection: old and new aspects. *Curr HIV Res*. 2008;6(5):411–418.
- Brecher ME, Hay SN, Pank YA. Is it HIV-associated thrombotic microangiopathy? *J Clin Apher*. 2008;23(6):186–190.
- Copelovitch L, Kaplan BS. The thrombotic microangiopathies. *Paediatr Nephrol*. 2008;23(10):1761–1767.
- Masot-Dupuch K, Quillard J, Meyohas MC. Head and neck lesions in the immunocompromised host. *Eur Radiol*. 2004;14 Suppl 3:E155–E167.
- Tighe P, Rimsza LM, Christensen MD, et al. Severe thrombocytopenia in a neonate with congenital HIV infection. *J Paediatr*. 2005;146(3):408–413.
- Jeena PR, Bobat R, Kindra G, et al. The impact of human immunodeficiency virus 1 on laryngeal airway obstruction in children. *Arch Dis Child*. 2002;87(3):212–214.
- Truitt TO, Tami TA. Otolaryngologic manifestations of human immunodeficiency virus infection. *Otolaryngology for the Internist*. 1999;83:303–315.
- Bhat VK, Latha P, Upadhyaya D, Hedge J. Clinicopathological review of tubercular laryngitis in 32 cases of pulmonary Kochs. *Am J Otolaryngol*. 2009;30(5):327–330.
- Wood R, Lawn SD, Johnstone-Robertson S, Bekker LG. Tuberculosis control has failed in South Africa: time to reappraise strategy. *S Afr Med*. 2011;101(2):111–114.
- Banerjee R, Schechter GT, Flood J, Procol C. Extensively drug resistant tuberculosis, new strains, new challenges. *Expert Rev Anti Infect Ther*. 2008;6(5):713–724.
- Bolognesi N, Reuter H. Taking XDR TB seriously in South Africa. *S Afr Fam Pract*. 2007;47(10):3–4.
- El-Sadr WM, Tsiouris S. HIV-associated tuberculosis: diagnostic and treatment challenges. *Semin Respir Crit Care Med*. 2008;29(5):525–531.
- Escombe AR, Moore DA, Gilman RH, et al. The infectiousness of tuberculosis patients co-infected with HIV. *PLoS Med*. 2008;5(9):e188.
- Shankar EM, Vignesh R, Ellegard R, et al. HIV-Mycobacterium tuberculosis co-infection: A "danger-couple model" of disease pathogenesis. *Pathog Dis*. 2014;70(2):110–118.
- WJ, B. Issues of management of HIV-related TB. *Clin Chest Med*. 2005;26:10.
- Warnke D, Barreto J, Temergen Z. Antiretroviral drugs. *J Clin Pharmacol*. 2007;47(12):1570–1579.
- Fennelly KP, Martyny JW, Fulton KE, et al. Cough generated aerosols of Mycobacterium tuberculosis. *Am J Respir Crit Care Med*. 2004;169(5):604–609.
- Escombe AR, Moore DA, Gilman RH, et al. Upper room ultraviolet light and negative air ionization to prevent tuberculosis transmission. *PLoS Med*. 2009;6(3):e43.
- LoBue P. Extensively drug-resistant tuberculosis. *Curr Opin Infect Dis*. 2009;22(2):167–173.
- Burman WJ, Jones BE. Clinical and radiographic features of HIV-related tuberculosis. *Semin in Resp Infect*. 2003;18(4):263–271.
- Ovasapian A, Tuncbilek M, Weitzel EK, Joshi CW. Airway management of adult patients with deep neck infections. A case series and review of the literature. *Anesth Analg*. 2005;100(2):585–589.
- Carbone A. Emerging pathways in the development of AIDS-related lymphoma. *Lancet Oncol*. 2003;4(1):22–29.
- Butt FM, Chindia ML, Rana F, Machigo FG. Pattern of head and neck malignant neoplasms in HIV-infected patients in Kenya. *Int J Oral Maxillofac Surg*. 2008;37(10):907–911.
- Jarrett R. Viruses and lymphoma/leukemia. *Journal of Pathology*. 2006;208(2):176–186.
- Feller L, Wood NH, Lemmer J. HIV-associated Kaposi's sarcoma: pathogenic mechanisms. *Oral Surg Oral Med Oral Pathol Oral Radiol Endod*. 2007;104(4):521–529.
- Hosam A, HH.e.a., Characteristics of HIV-1 associated Kaposi's sarcoma among women and men in South Africa. *Int J STD AIDS*. 2008;19(16):5.
- Miner JE, Egan TD. An AIDS-associated cause of the difficult airway: supraglottic Kaposi's sarcoma. *Anesth Analg*. 2000;90(5):1223–1226.
- Sitas F, Newton R. Kaposi's sarcoma in South Africa. *J Natl Cancer Inst Managr*. 2001;28:1–4.
- Wood NH, Feller L. The malignant potential of HIV-associated Kaposi's sarcoma. *Cancer Cell Int*. 2008;8:14.
- Van Marle J, Tudhope L, Weir G, Botes K. Vascular disease in HIV/AIDS patients. *S Afr Med*. 2002;92(12):974–978.
- Schulenberg E, Le Roux PJ. Antiretroviral therapy and anaesthesia. *South Afr J Anaesth Analg*. 2008;14(2):31–38.
- Dhasmana DJ, Dheda K, Ravyn P, et al. Immune reconstitution inflammatory syndrome in HIV-infected patients receiving antiretroviral therapy: pathogenesis, clinical manifestations and management. *Drugs*. 2008;68(2):191–208.
- Hirsch HH, Kaufmann G, Sendi P, Battegay M. Immune reconstitution in HIV-infected patients. *Clin Infect Dis*. 2004;38(8):1159–1166.
- Piloya T, Bakeera-Kitaka S, Kekitiinwa A, Kanya MR. Lipodystrophy among HIV-infected children and adolescents on highly active antiretroviral therapy in Uganda: a cross-sectional study. *J Int AIDS Soc*. 2012;15(2):17427.
- Will California lead the way? Airborne rule could lead to state and national standards. *Hospital Employee Health*. 2008;27(11):4.