

The LMA Classic™ as a conduit for tracheal intubation in adult patients: a review and practical guide

Alberts ANJ, MBChB, DA, DIPPEC, MMED, FCA, Head, Clinical Unit, Department of Anaesthesiology and Critical Care Kalafong Hospital; Faculty of Health Sciences, University of Pretoria, Pretoria

Correspondence to: Andrie Alberts, e-mail: andrie.alberts@up.ac.za

Keywords: laryngeal mask airway, intubation, intubating conduit, bougie, catheter, guidewire, failed intubation, difficult airway

Abstract

Unexpected difficulty in maintaining an open airway following induction of anaesthesia remains an ever-present hazard. Repetitive attempts at direct laryngoscopy and intubation are generally acknowledged to be inappropriate. The LMA Classic™ is recognised as a rescue ventilation device in failed intubation scenarios and its specific role is well defined in international airway management protocols. Should clinical conditions dictate the need for tracheal intubation following placement of an LMA Classic™, it may be retained to serve as a conduit for intubation. Utilising the LMA Classic™ as a conduit for intubation is considered a rescue manoeuvre, only resorted to when conventional methods such as direct laryngoscopy have failed. Therefore, it is important that this approach to intubation has a high success rate and that airway management specialists are familiar with the different available options, the relevant limitations and the pitfalls. A short description of the components of the LMA Classic™, specifically relating to its function as an intubating conduit, is provided in this review. Its limitations as a conduit are then listed, followed by a description of the most popular techniques of intubation via the LMA Classic™. By adhering to a number of basic principles outlined in this review, limitations may be overcome, pitfalls avoided, and an escape conduit added for the anaesthetist who is faced with a difficult-to-intubate airway.

© Peer reviewed. (Submitted: 2013-07-16. Accepted: 2013-10-21.) © SASA

South Afr J Anaesth Analg 2014;20(1):77-88

Introduction

The Difficult Airway Society (DAS) guidelines on management of “unanticipated difficult tracheal intubation during routine induction of anaesthesia in an adult patient” recommend use of either the LMA Fastrach™ [intubating laryngeal mask airway (ILMA™)] or the LMA Classic™ in Plan B (the secondary tracheal intubation plan).¹ The selected device (LMA Fastrach™ or LMA Classic™), is then used as a conduit for fibre-optic tracheal intubation. The American Society of Anesthesiologists (ASA) difficult airway algorithm likewise recommends the use of the LMA Classic™ or LMA Fastrach™ as an intubating conduit (with or without fibre-optic guidance) in the non-emergency pathway of its difficult airway algorithm in the case of failed intubation.² An observational study reports that the LMA Classic™ provides successful rescue ventilation in 94.1% of patients who cannot be mask ventilated or intubated.³ Although currently the LMA Fastrach™ remains the gold standard as a conduit for tracheal intubation, it might not be readily

available in operating theatres and many anaesthetists are not familiar with its use.⁴ The LMA Classic™ was not primarily designed as a conduit for tracheal intubation, and has noticeable limitations when employed for this purpose. Despite these limitations, and in view of its role as an airway rescue device, on occasion it is still relied on as a conduit for tracheal intubation.

In addition to the LMA Fastrach™, a number of supraglottic devices have become available that are designed specifically for tracheal intubation, most notably the Cookgas air-Q® and the LMA Classic Excel.™ Further reference to these devices falls beyond the scope of this review.

LMA Classic™ characteristics

Developed primarily as an alternative to the face mask during general anaesthesia, a prototype laryngeal mask airway (LMA) was first used clinically in August of 1981.⁵ Introduced into clinical anaesthesia in the UK in 1988 and in the US in 1992, the LMA Classic™ was first sold

in South Africa in April 1990 (Marland Medical, personal communication, December 2012). A number of device components directly impact on its role as a conduit for tracheal intubation (Figure 1). From proximal (furthest away from the patient) to distal (closest to the patient) these components are a connector, a tube, aperture bars and a cuff. The connector fits into the proximal aperture (opening) of the tube, and the distal aperture of the tube fits to the convex side of an elliptically shaped bowl at an angle of close to 30 degrees, based on the optimal angle for tracheal intubation via the LMA in anatomical studies.⁶ Two parallel epiglottic aperture bars, also referred to as “mask aperture bars”⁷ or “grille”, stretch across the distal tube aperture. The bowl is lined by an inflatable rim or cuff, and an inflation line connects the cuff to the pilot balloon and valve. Composed of medical-grade silicone rubber, the LMA Classic™ is latex free and is sterilised by steam autoclaving. Manufacturer recommendations are for all reusable LMA devices to be discarded after 40 uses.⁸ However, the clinical performance of the size 3-5 LMA Classic™ has been shown to be unaffected over 60 autoclave cycles.⁹ In a study on the lifespan of the LMA Classic™, one device was used at least 195 times.¹⁰ Recent in vitro work (simulated clinical use cycle) suggests that the LMA Classic™ may be reused 133 times before failing pre-use tests. Discarding reusable LMA devices only when they fail the pre-use check tests, rather than after a specific number of uses, has subsequently been recommended.¹¹ Three mechanisms have been described by which supraglottic devices are thought to seal the upper airway. In this regard, the LMA Classic™ has been classified as a cuffed perilaryngeal sealer without directional sealing.¹²

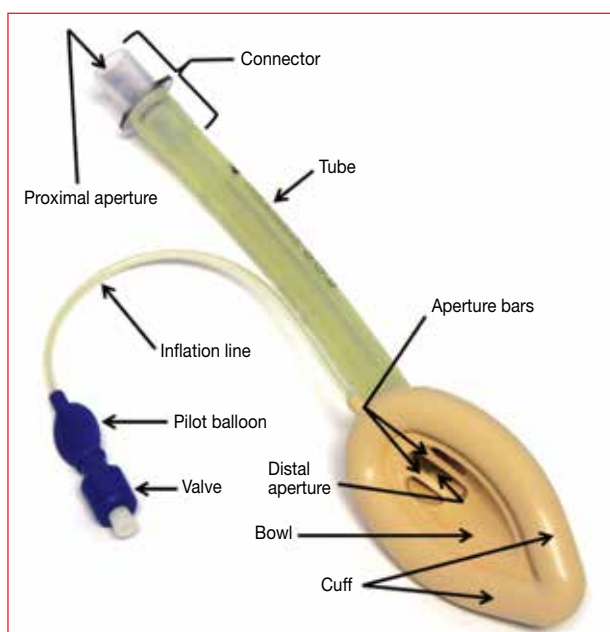


Figure 1: LMA Classic™

Inherent limitations to the LMA Classic™ as a conduit for tracheal intubation

At least six structural characteristics potentially complicate the use of the LMA Classic™ as an intubation conduit:

- The distal end of the standard 15-mm outer-diameter connector fits inside the proximal tube, leaving a sharp rim. Tracheal tube cuff damage is likely at this rim during withdrawal of the tracheal tube, especially when lubrication is omitted or tracheal tube cuff deflation is incomplete. Hence the tracheal tube cuff must be rechecked prior to each subsequent use in the case of repetitive attempts at tracheal intubation.
- The bars may obstruct the passage of a tracheal tube, but do not limit the size of tracheal tube allowed. The gaps between the bars of the commonly used size 4 single-use LMA Unique™ are smaller than those of a size 4 LMA Classic™.¹³
- A step, resulting from the manufacturing process, at the bowl to tube attachment ring may hamper the passage of an intubating guide.¹⁴
- The tube and connector diameter¹⁵ restrict the range of tracheal tube that may be employed for direct tracheal intubation. The connector consists of two segments: proximal and distal. The proximal segment internal diameter measures 13 mm proximally, and reduces to 11 mm distally at the flange, i.e. it is internally tapered. These dimensions are identical for sizes 3, 4 and 5 LMA Classic™. From this, the imprudence of forcing a tracheal tube down the funnel-shaped connector should be clear. The internal diameter of the distal segment of the connector (the part that passes into the proximal aperture of the tube) is 10 mm for sizes 3 and 4, and 11.5 mm for size 5 LMA Classic™. The internal diameter of the tube for sizes 3 and 4 is 10.2 mm, and 11.6 mm for size 5 LMA Classic™. Recommendations regarding tracheal tube size are a cuffed size 6 for sizes 3 and 4 LMA Classic™, and a cuffed size 7 for size 5 LMA Classic™.¹⁶ The relevant diameters of two tracheal tubes commonly used in South Africa have been summarised in Table I. Converting from a dedicated¹⁷ (LMA Classic™) to a definitive (tracheal tube) airway under emergency conditions is not the time to experiment with the most appropriate LMA Classic™ to tracheal tube match. This match, as well as the technique, should rather be rehearsed in the normal non-emergency airway.
- Tube and connector length¹⁵ may result in the tracheal tube cuff positioned between the vocal cords with a subsequent incomplete seal or possible damage to the larynx when inflated. The mean distance between the bars and the vocal cords in males is 3.6 cm (2.5-4.7 cm), and 3.1 cm (2-4.2 cm) in females.¹⁸ Practically, this implies that the tracheal tube cuff proximal inflation point needs to pass beyond the bars by at least 3.6 cm

Table I: The internal diameter of the LMA Classic™ versus the outer diameter of two commonly utilised tracheal tubes

LMA Classic™			Tracheal tubes	
			Parker Flex-Tip™/LMA Fastrach™ ETT	
Size	Connector ID (mm)	Tube ID (mm)	Size	OD (mm)
3	Proximal 11/distal 10	10.2	6	8.2/8.8
4	Proximal 11/distal 10	10.2	6.5	8.7/9.4
5	Proximal 11/distal 11.5	11.6	7	9.3/10

ETT: endotracheal tube, ID: internal diameter, LMA: laryngeal mask airway, OD: outer diameter

and 3.1 cm in male and female patients, respectively, for the cuff to safely inflate beyond the vocal cords. Measured from the proximal aperture (connector removed), the distance to the cuff proximal inflation point of the commonly utilised 6.5-mm internal-diameter Mallinckrodt™ tracheal tube is ~ 24.5 cm. In view of the ~ 21.5 cm distance between the bars and connector proximal aperture of a size 5 LMA Classic™, the cuff proximal inflation point will protrude ~ 3 cm beyond the bars. With a required distance of 3.6 cm, but up to 4.7 cm,¹⁸ this specific combination in some patients will not assure positioning and inflation of the cuff safely beyond the vocal cords. Additionally, with the proximal apertures of connector and tracheal tube flush, safe removal of the LMA Classic™, especially when dealing with a rescue airway, adds the ill afforded hazard of inadvertent extubation.¹⁹ Risks associated with suboptimal tracheal tube to LMA Classic™ matching may be reduced by selecting a longer tracheal tube (not stocked by many anaesthesia departments), by removing the connector (and gaining 2 cm), or simply by cutting the tube shorter.²⁰ The suggested optimum length of the tube to be cut off is equal to the specific size LMA Classic™ selected, i.e. 5 cm for size 5 LMA.

- The angle at which a tracheal tube exits from the tube distal aperture naturally guides it posteriorly from the laryngeal inlet towards the oesophagus.

Relative contraindications to the use of the LMA Classic™ as a conduit for tracheal intubation

The use of any supraglottic device is relatively contraindicated in the presence of supraglottic pathology, i.e. tumours, abscesses, oedema and/or haematoma. Under these circumstances, blind tracheal intubation with the LMA Classic™ as a conduit would be ill advised and is strongly discouraged.

Prerequisites for successful use of the LMA Classic™ as a conduit for tracheal intubation

The tube distal aperture and laryngeal aperture must be well aligned. Satisfactory LMA Classic™ ventilation in

children does not necessarily imply proper alignment.²¹ The ideal position, defined as the epiglottis and oesophagus being outside, and the laryngeal aperture being totally within the confines of the cuff, is obtained in only 45-60% of placements. Inclusion of the epiglottis within the cuff boundaries may be commonplace without clinical evidence of airway compromise, which emphasises the ability of the LMA Classic™ to provide a clinically perfect airway, even when the seating is less than ideal.²²⁻²⁴ A potentially useful strategy may be to use size 5 in all adults, or size 5 in adults ≥ 165 cm in height, and size 4 in adults < 165 cm. An algorithm for optimal laryngeal mask size selection in adults has been proposed.⁹

There must be a relatively unobstructed path between the tube distal aperture and the laryngeal aperture. This prerequisite renders contraindicated attempts at blind placement of a tracheal tube through an LMA Classic™ in a patient with supraglottic pathology, as mentioned. Persistence along this avenue will inevitably transform a compromised airway to an obstructed airway.

The vocal cords must be open and nonreactive. Therefore, sufficient depth of anaesthesia in the spontaneously breathing patient is required. Glottic reflexes may be further decreased by topical spraying, but awareness of the risk of aspiration is required. Neuromuscular blocking agents effectively paralyse the cords. However, their administration needs to be weighed against the risk of a failed airway in an apnoeic patient.

The tracheal tube must be of sufficient diameter, length, flexibility and durability to pass through the tube, enter the larynx, change direction towards the trachea, and advance adequately for the cuff proximal inflation point to safely pass beyond the vocal cords.

Intubating guides used for tracheal intubation with the LMA Classic™

Intubating guides specifically designed to find the laryngeal aperture during difficult laryngoscopy, and then to pass a tracheal tube over, are referred to as introducers or bougies. The use of hollow and solid introducers has been described. Hollow introducers (e.g. the Frova® Intubating Introducer) allow for oxygenation during intubation. Intubating guides

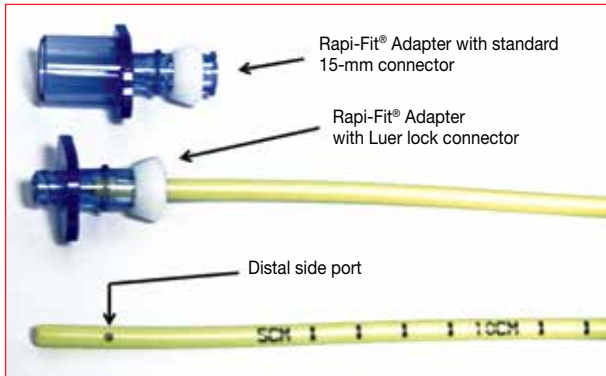


Figure 2: Cook® Airway Exchange Catheter

specifically designed for the exchange of airway devices (e.g. tracheal tubes or supraglottic devices) are known as airway exchange catheters. A basic appreciation of the range of available devices, as well as the specific characteristics thereof, is required for a better understanding of the variety of techniques described for tracheal intubation through the LMA Classic™.

Use of one of the following five devices, all of which are readily available in South Africa, is described in the vast majority of publications on this topic:

- The 83-cm Fr 19 Cook® Airway Exchange Catheter is an intubating guide specifically designed for tracheal tube exchange (Figure 2). Use of a removable Rapi-Fit® Adapter (either with a standard 15-mm connector or Luer lock connector) permits oxygenation and ventilation, while distal side ports improve airflow. A 100-cm AEC is also available, both in Fr 11 and 14.
- The 56-cm Fr 19 Aintree® Intubation Catheter is an intubating guide specifically designed for fibre-optic tracheal intubation (Figures 3 and 8). With an internal diameter of 4.7 mm (which allows the passage of a 4.5-mm fibrescope), and an outer diameter of 6.3 mm (which allows railroading of tracheal tube size 6.5 or greater), it fits snugly over the length of a standard adult fibrescope, leaving the controllable distal tip uncovered. Use of a removable Rapi-Fit® Adapter (either with a standard 15-mm connector or Luer lock connector) permits oxygenation and ventilation. It has been shown to be effective and easy to use in facilitating fibre-optic tracheal intubation via the LMA Classic™.²⁵
- The 60-cm Eschmann Introducer®, commonly known as “gum-elastic bougie”, is a solid introducer (Figure 4) with a coudé tip (with a 40-degree bend). Although the Eschmann Introducer® can be used to direct the tracheal tube towards an “anterior” or narrow larynx, its real strength lies as a tool to facilitate intubation when the laryngeal aperture cannot be seen during laryngoscopy (e.g. Cormack-Lehane grade 3 view). There is a historical explanation for the inaccurate and confusing terminology relating to the “bougie”.²⁶ For example, concern has

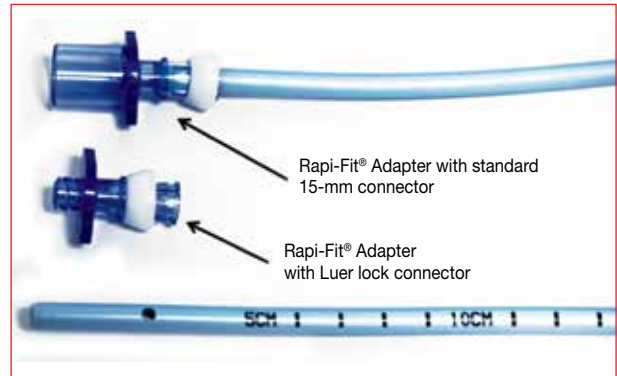


Figure 3: Aintree® Intubation Catheter



Figure 4: Eschmann Introducer®

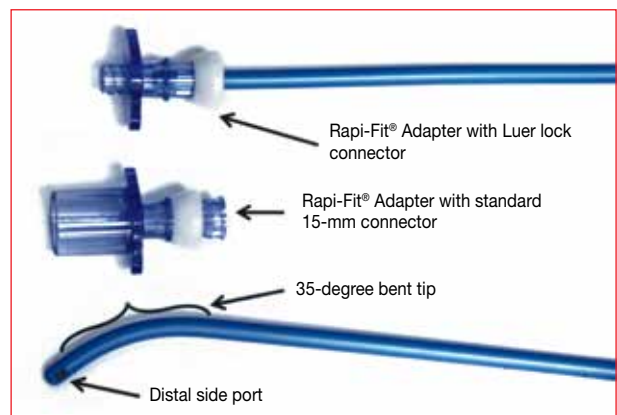


Figure 5: Frova® Intubating Introducer

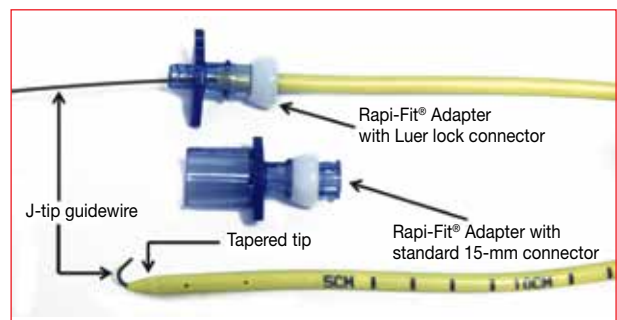
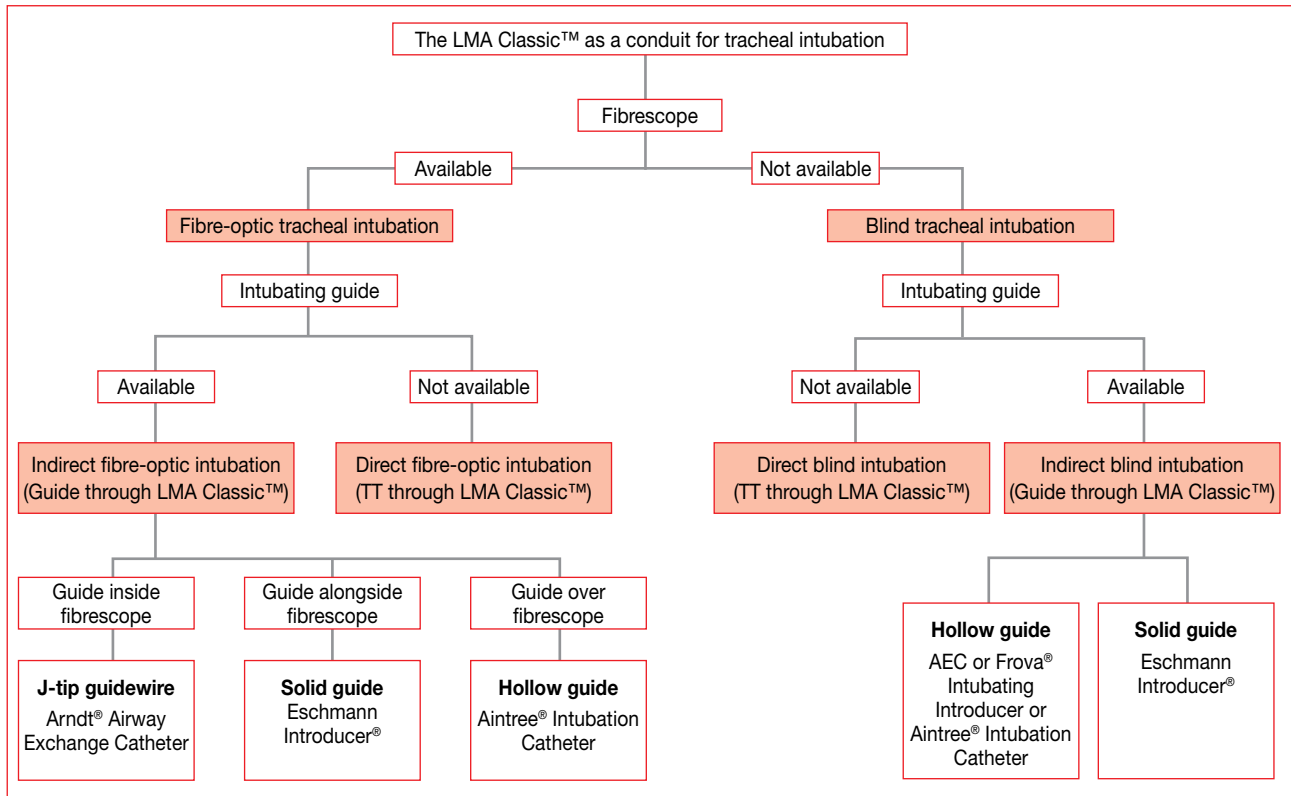


Figure 6: Arndt® Airway Exchange Catheter with J-tip guidewire

been expressed with regard to reference to an Eschmann Introducer® as a “gum-elastic bougie”,²⁷ pointing to the fact that it is not made of gum, is not elastic, and is not used as a dilating device.²⁸

- The 70-cm Fr 14 Frova® Intubating Introducer (Figure 5) is a hollow introducer that was specifically designed to facilitate tracheal intubation when glottic visualisation is inadequate. It is a similar device to the Eschmann



AEC: airway exchange catheter, TT: tracheal tube, LMA: laryngeal mask airway

Figure 7: The LMA Classic™ as a conduit for tracheal intubation

Introducer® with its 35-degree bent tip. Distal side ports prevent whipping during high-pressure jet ventilation. The 4.6-mm outer diameter facilitates placement of a size 5 or larger tracheal tube.

- The 70-cm Fr 14 Arndt Airway Exchange Catheter® (Figure 6) has a tapered tip that snugly fits over a guidewire, which reduces the risk of the catheter impinging when it is passed through the aperture bars or glottic inlet. Use of a removable Rapi-Fit® Adapter (either with a standard 15-mm connector or Luer lock connector) permits oxygenation and ventilation. Tracheal tube size 5 or larger can be railroaded over the Arndt Airway Exchange Catheter®.

Techniques of tracheal intubation with the LMA Classic™ as a conduit

Fibre-optic as well as blind (fibrescope not used) techniques have been described in combination with both direct and indirect approaches to tracheal intubation (Figure 7). “Direct” simply refers to techniques where the tracheal tube is advanced directly through the LMA Classic™ into the trachea, i.e. the LMA Classic™ serves as a conduit for a tracheal tube. “Indirect” refers to techniques where an intubating guide is advanced through the LMA Classic™ and the latter removed, i.e. the LMA Classic™ serves as a conduit for a guide. The intubating guide then serves as a pilot over which to railroad the tracheal tube into the trachea. From a

practical perspective, the selected technique in a specific clinical case depends entirely on operator experience and the availability of a fibrescope and other intubating guides.

The LMA Classic™ as a conduit for direct blind tracheal intubation

This technique (Figure 7) involves direct advancement of a tracheal tube sequentially through the connector, the tube, the bars, and finally the laryngeal inlet. Liberal lubrication and tracheal tube rotation during passage is advised. Following confirmation of successful tracheal tube placement, the cuff is deflated and the LMA Classic™ either removed or left in situ. Tube and connector dimensions, as already discussed, limit the range of tracheal tube that may be employed.

The first recorded use of a (prototype) LMA Classic™ as a conduit for direct blind tracheal intubation dates back three decades to May 1983.²⁹ Differences in technique, patient positioning and type of tracheal tube employed have resulted in significantly differing reported success rates. Single-attempt (74%, 37/50) and overall (90%, 45/50) success rates were reported in an adult population of paralysed elective surgical patients with a technique that included good lubrication and a 90 degree to the left rotation to bring the bevel anteriorly during passage of a 6-mm internal-diameter tracheal tube (either nasal Portex® or oral Mallinckrodt®) through a size 3 and 4 LMA Classic™ for female and male patients, respectively.³⁰ Comparing

three types of tracheal tube (Argyle®, Portex® and Kendall Curity®), Lim et al³¹ achieved a single-attempt blind intubation success rate of 3.3%, 70% and 30%. After a maximum of three attempts, success rates increased to 30%, 93.3% and 76.7%, respectively. Successful placement of the tracheal tube was achieved most often with the patient's head and neck in the "sniffing" position. The authors were unable to obtain detailed information from the manufacturers about the composition and other characteristics of the three types of tracheal tube, which may well have contributed to the findings.

Despite the glottis being visible fibreoptically just below the bars and the oesophageal orifice not being visualised, the incidence of oesophageal intubation associated with single-attempt direct blind tracheal intubation (Portex® 6-mm internal-diameter tracheal tube) may still be as high as 60%.³² Single-attempt failure rates reported with direct blind tracheal intubation in a large series of patients thought to have normal anatomy varied from 26-97%, and overall failure rates from 10-70%.^{30,33,34}

Caution during direct blind endotracheal intubation via the LMA Classic™ is advised since adequate ventilation does not assure optimal positioning. The exact position of the tube distal aperture in relation to the laryngeal inlet cannot be assumed until fibre-optic verification has taken place.^{24,25} Owing to the risk of pharyngolaryngeal injury and the low success rate, this approach is recommended only if no other options exist.

The LMA Classic™ as a conduit for indirect blind tracheal intubation

This technique (Figure 7) consists of blindly passing an intubating guide into the trachea through the LMA Classic™, removing the LMA Classic™, and then railroading the tracheal tube. The range of tracheal tube that may be employed is not restricted by tube or connector dimensions. Success rates are lower if the distal tip of a gum-elastic bougie is straight (a high risk of oesophageal intubation), rather than angled. In a case series, it was suggested that the blind passage of a gum-elastic bougie was made easier when the angulated tip was pointing anteriorly, followed by rotation through 180 degrees as it cleared the bars (to bring the angulated end in line with the long axis of the trachea), resulting in an 84% (21/25) success rate.³⁵ Failures in this prospective series were associated with poor LMA Classic™ positioning, as confirmed under fibre-optic vision. Practical advice from this group was to mark the bougie, indicating both the direction of the angulated end, as well as the point at which it cleared the bars. Success rates from other groups were less impressive. Blind placement of a gum-elastic bougie was successful in only 28% (11/40) of a group of elective surgical patients and decreased to 22.5% (9/40) with the addition of manual in-line stabilisation and cricoid pressure.³⁶

Blind placement of a gum-elastic bougie was successful in 0% (0/20) of patients in the neutral position, and in 20% (4/20) of patients when specifically positioned in the "classical intubating position", in a controlled trial that was designed specifically to determine the effect of head position on the rate of successful tracheal intubation in Mallampati class I or II patients.³⁷ When a lubricated Cook® Airway Exchange Catheter was passed blindly down an LMA Classic™ in a group of paralysed patients, the first attempt success rate using a 30-second time limit was only 30% (6/20).³⁸ The Cook® Airway Exchange Catheter slipped down the oesophagus in the remainder, and it was shown that when inserted in vitro, the catheter emerged from the posterior aspect of the bars, which would favour oesophageal intubation. In addition, it was noted that on several occasions, the catheter appeared to impact on the bars. The main reasons for failure were believed to relate to the catheter being too rigid, inadequately curved and blunt ended. Case reports of successful indirect blind tracheal intubation in three difficult airway patients, including failed direct laryngoscopy in one patient, have nevertheless been published.^{39,40} A cadaveric trial of 114 attempts by 19 participants on the placement of an Eschmann Introducer® through a size 4 LMA Classic™ yielded an overall success rate of 52%.⁴¹

When indirect blind tracheal intubation is opted for, the overall failure rate is 18-70%.^{35,38} Therefore, as with the direct blind technique, caution is required in view of the inability to guarantee where a blindly advanced intubating guide will go, and the associated risk of pharyngolaryngeal or even tracheal⁴² injury. The risk to benefit ratio begs careful consideration before an attempt at indirect blind tracheal intubation is made. Its use should be questioned if other techniques are available.

The LMA Classic™ as a conduit for direct fibre-optic tracheal intubation

This technique (Figure 7) consists of passing a tracheal tube-mounted fibrescope through the tube and bars into the trachea. The tracheal tube is then railroaded into the trachea under direct vision, and finally the fibrescope removed. Following confirmation of tracheal tube positioning, the cuff is deflated and the LMA Classic™ extracted. The passage of a fibrescope through the LMA Classic™ is nearly 100% successful in most series.⁴³ As with the direct blind technique, the size of the tracheal tube allowed is limited by the tube or connector. The tracheal tube cuff likewise may be damaged, depending on the LMA Classic™ to tracheal tube match, and removal of the LMA Classic™ may be at risk of inadvertent extubation.

Several solutions to minimise the risk of accidental extubation during removal of the LMA Classic™ (in the absence of an airway exchange catheter) have been offered.

If allowed by the clinical scenario, the cuff is deflated and the LMA Classic™ left in situ. Alternatively, a second tracheal tube may be used as a buttress to hold the tracheal tube steady as the LMA Classic™ is withdrawn over it.⁴⁴

Since situations of a failed airway often arise during rapid sequence induction of anaesthesia, time to successful tracheal intubation is important. When comparing three different techniques, time to successful tracheal intubation was significantly shorter with the LMA Fastrach™ (blind) than with either the LMA Classic™ or LMA Fastrach™ direct fibre-optic techniques in 60 healthy patients with normal airways.⁴⁵ Although the first-attempt success rate in this study was lower with the LMA Fastrach™ (blind) technique, differences were not significant. Both direct and indirect fibre-optic tracheal intubation were significantly faster with the i-gel® than with the LMA Classic™ in a manikin study.⁴⁶

The LMA Classic™ as a conduit for indirect fibre-optic tracheal intubation

A number of approaches (Figure 7) to this technique have been described, and as with the indirect blind technique, the range of tracheal tubes that may be employed is not restricted by tube or connector dimensions.

First approach

Practically, the first approach includes the following steps:

- Place the LMA Classic™.
- Pass a fibrescope through the Aintree® Intubation Catheter, confirm that the tip of the fibrescope extends beyond the Aintree® Intubation Catheter, and that the tip can be controlled (Figure 8). Advance the Aintree® Intubation Catheter-loaded fibrescope through the LMA Classic™ and into the trachea, under direct vision.
- Railroad the Aintree® Intubation Catheter into the trachea, and remove the fibrescope, followed by the LMA Classic™.
- While securely holding the Aintree® Intubation Catheter, railroad the tracheal tube into the trachea. (The fibrescope may be re-introduced into the Aintree®

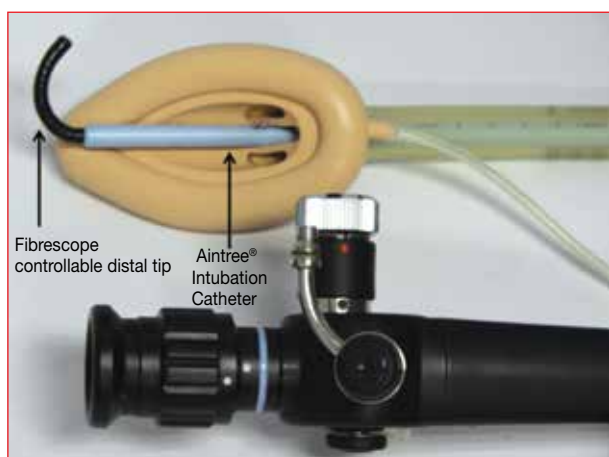


Figure 8: LMA Classic™, Aintree® Intubation Catheter and fibrescope

Intubation Catheter at this stage, and the tracheal tube advanced into the trachea under direct fibre-optic vision. This may be of particular value should capnography not be available).

- Remove the Aintree® Intubation Catheter and confirm the tracheal tube position with capnography.

In this regard, the use of a “rectal tube” as an intubating guide has been recorded.⁴⁷ The first published description of the process of using a catheter similar to an Aintree® Intubation Catheter was in 1996, by Atherton et al.²⁵ The specific so-called “ventilation-exchange bougie” used was a direct result of the ad hoc use of a wide-bore jejunostomy tube. The fibrescope may, in addition to using the catheter proximal aperture, also be thread through a catheter side hole. The part of the catheter proximal to the side hole is used as a handle to fix the catheter to the fibrescope, preventing the catheter from sliding down prematurely during tracheal intubation.⁴⁸

Two manikin studies considered the LMA Classic™ as a conduit for indirect fibre-optic tracheal intubation. The LMA Classic™/Aintree® Intubation Catheter/fibre-optic technique had a higher success rate (26/26 vs. 5/26) and took a shorter time (18 vs. 110 seconds) to successful tracheal intubation, than an LMA Fastrach™/Fastrach endotracheal tube/fibre-optic technique in a randomised crossover simulated difficult airway study.⁴⁹ No significant difference was found when comparing the LMA Classic™ and the LMA ProSeal™ with regard to ease of advancement or view of the vocal cords with an Aintree® Intubation Catheter-mounted fibrescope in the second manikin study.⁵⁰ Twenty-five anaesthetists of all grades performed the intubations. The overall success rate was 95%.

Use of a catheter for tracheal intubation via the LMA Classic™ has been reported, both in the absence and presence of a predicted airway difficulty. The success rate was 98% in 54 patients in the absence of predicted airway difficulty.^{25,48} The LMA Classic™/Aintree® Intubation Catheter/fibre-optic technique was attempted in 128 patients in a retrospective review of 500 patients entered into a difficult airway database.⁵¹ From this group of patients, 93% (119/128) were successfully intubated. None of the patients experienced airway-related mortality or required an emergency surgical airway procedure. The authors concluded that the LMA Classic™/Aintree® Intubation Catheter/fibre-optic technique was safe and effective for patients who are difficult to intubate after induction of anaesthesia.

Similarly, in a series of nine case reports of failed direct laryngoscopy, patients were successfully intubated with the LMA Classic™/Aintree® Intubation Catheter/fibre-optic technique.⁵² Cook et al⁵³ described successful LMA Classic™/Aintree® Intubation Catheter/fibre-optic tracheal intubation in a patient who had had radiation to the floor of

his mouth, a Mallampati class 4 airway, a Cormack-Lehane grade 2b view on direct laryngoscopy, and failed use of an LMA ProSeal™. The Aintree® Intubation Catheter/fibre-optic pairing, combined with an LMA Unique™ (LMA Unique™/Aintree® Intubation Catheter/fibre-optic technique), was successfully used in a failed intubation scenario, which included failed direct laryngoscopy attempts with a GlideScope®.⁵⁴ Failure of the LMA/Aintree® Intubation Catheter/fibre-optic technique was reported in a case where manual in-line stabilisation of the cervical spine was applied.¹⁴ The Aintree® Intubation Catheter could not be advanced off the fibrescope into the laryngeal inlet in this case report. This failure may have been owing to the gap created by mounting the Aintree® Intubation Catheter (internal diameter of 4.7 mm) onto a relatively small (outer diameter of 3.1 mm) Olympus FT-DP® fibrescope. Additionally, it may have been because of the step at the base of the bowl, owing to the thickness of the LMA Classic™ bowl, and the amount of adhesive used during manufacturing to bond the bowl to the tube distal aperture. By way of practical advice, it was recommended that the largest available fibrescope (minimising the size of the gap) should be used, and that consideration should be given to selecting the LMA ProSeal™ (no step at the base of the bowl) rather than the LMA Classic™.

Second approach

The second approach entails passing a flex-tip guidewire via the suction port of a fibrescope through the LMA Classic™ into the trachea under direct vision. Both the LMA Classic™ and fibrescope are removed, and the guidewire left, serving as an intubating guide. Throughout most of this procedure, oxygenation is possible via the LMA Classic™ using a self-sealing fibre-optic adapter. The large discrepancy (gap) between the small-diameter guidewire and large tracheal tube (guidewire-only technique) may result in impingement of the tracheal tube at the level of the glottic inlet. An Arndt® Airway Exchange Catheter (the tapered tip matches the guidewire, leaving no gap) should rather first be railroaded over the guidewire (guidewire-catheter technique), and only then the tracheal tube over the Arndt® Airway Exchange Catheter (Figure 6). Attachment of the removable Rapi-Fit® Adapter to the Arndt® Airway Exchange Catheter allows for oxygenation. Since the guidewire technique involves an increased number of steps, the entire sequence should be well rehearsed prior to attempting it under conditions of a failed airway. Nevertheless, Joffe et al⁵⁵ published a retrospective case series that described successful guidewire-catheter tracheal intubation following failed direct laryngoscopy in five critically ill adults. Successful tracheal intubation with the guidewire-only technique in eight patients has likewise been described.⁵⁶⁻⁵⁸

Third approach

The third approach involves the use of a bougie or introducer. The bougie and fibrescope are inserted in parallel through the LMA Classic™ and advanced in tandem. Although coordinated efforts of two operators may prolong the procedure, O₂ insufflation, delivered via the fibrescope suction port to the glottic inlet, allows more time before desaturation. Single-attempt LMA Classic™ placement was judged to be “good” fibreoptically in 22/25 paralysed patients, and gum-elastic bougie insertion under fibre-optic guidance successful in all of these 22 patients in a prospective series.³⁵

Following two failed attempts at direct laryngoscopy, and two failed attempts at direct fibre-optic tracheal intubation, a gum-elastic bougie was passed through the vocal cords under direct fibre-optic vision and indirect fibre-optic tracheal intubation successfully accomplished in a patient scheduled for subtotal thyroidectomy.⁵⁹ This may indicate that fibre-optic, gum-elastic bougie insertion has a higher success rate than that of blind insertion, resulting in an increased rate of successful tracheal intubation.

Although currently there is insufficient evidence to recommend one technique over the other, recently opinion has been expressed that the first approach (LMA Classic™/Aintree® Intubation Catheter/fibre-scope technique) is preferable⁶⁰ (Figure 8).

The LMA Classic™ as a conduit for retrograde tracheal intubation

Following antegrade passage of a guidewire, gum-elastic bougie or airway exchange catheter, the potential exists for the unsecured distal portion of these devices to become dislodged, either during removal of the LMA Classic™ or the attempted passage of the tracheal tube. This risk is reduced during retrograde intubation, with the LMA Classic™ sequentially serving as a retrograde conduit for the guidewire, and then as an antegrade conduit for the exchange catheter and tracheal tube. A retrograde technique, consisting of passing a guidewire from the cricothyroid membrane through the LMA, and then railroading a guiding catheter over the guidewire, was successfully employed in a 100-kg male in whom both direct laryngoscopy and indirect blind tracheal intubation (using a Cook® Airway Exchange Catheter) failed.⁶¹ Entering the trachea at the level of the second or third rings, rather than the cricothyroid membrane, leaves the airway exchange catheter/tracheal tube to pass a greater distance beyond the glottic inlet, which reduces the risk of accidental dislodgment at the time of removal of the guidewire. Having successfully retrieved a guidewire placed from the trachea, a fibrescope may be railroaded over the guidewire (fibre-optic suction port), and the pre-mounted tracheal tube then advanced into the trachea under direct

fibre-optic vision, the LMA Classic™ still serving as the intubating conduit.

The LMA Classic™ as a conduit for tracheal intubation in the patient at risk of pulmonary aspiration

Since the LMA Classic™ does not provide an airtight seal around the larynx, its elective use in patients at risk of active vomiting or passive regurgitation is contraindicated. Awake insertion three hours after a “healthy breakfast” has nevertheless been described.⁶² Only one in 10 healthy awake volunteers reported discomfort during placement of a LMA Classic™ under remifentanyl sedation.⁶³ Active swallowing may aid the insertion.⁶⁴⁻⁶⁶ Two case reports described the use of the LMA Classic™ as an aid to tracheal intubation in patients specifically at risk of aspiration.⁶⁷ These two cases are recalled in some detail since the first outlines the use of the LMA Classic™ as a conduit for awake tracheal intubation, and the second as a conduit for rapid sequence induction.

In the first case, a LMA Classic™ was placed under intravenous sedation and airway topicalisation in an unpremedicated patient scheduled for emergency Caesarean section for antepartum haemorrhage and foetal death. The tracheal tube was loaded onto the fibroscope, and passed down the tube and through the bars. With a clear view of the glottic inlet, the fibroscope was advanced into the trachea, followed by the tracheal tube. This caused coughing and straining, as well as an increase in blood pressure and heart rate. The tracheal tube cuff was inflated and the fibroscope removed prior to intravenous induction of anaesthesia. During emergence, the patient vomited a large volume of gastric content, but with the tracheal tube in situ, no pulmonary soiling was evident. Lidocaine 4% was sprayed through the LMA Classic™ onto the cords prior to direct blind insertion of the tracheal tube in a similar obstetric clinical scenario that required urgent Caesarean section [complicated by morbid obesity, predicted difficult intubation and HELLP (haemolysis, elevated liver enzyme levels and a low platelet count) syndrome].⁶⁸

In the second case, the patient was scheduled for repair of an intestinal obstruction and received intramuscular atropine and hydroxyzine as premedication. She was rendered “sedated, but responsive to command” upon arrival in the operating room by divided doses of diazepam and fentanyl. Following topical upper airway anaesthesia, a LMA Classic™ was placed with minimal apparent discomfort to the patient. A fibroscope was passed through a tracheal tube, and the combination inserted down the tube and passed beyond the bars to provide a clear view of the glottic inlet. Under continuous direct fibre-optic observation of the glottis, thiomyxal and succinylcholine were administered intravenously in rapid sequence, and cricoid pressure

applied as soon as the patient lost consciousness. After the patient was paralysed, the fibroscope was advanced into the trachea, the tracheal tube passed over it, the tracheal tube cuff inflated, and the fibroscope removed following visual confirmation of proper tracheal tube positioning. The patient’s heart rate increased slightly during placement of the tracheal tube, but her blood pressure remained unchanged.

The advantages of these two techniques are threefold. Firstly, they are technically relatively easy. Secondly, and with specific regard to the rapid sequence induction technique, the time between induction of anaesthesia and tracheal tube cuff inflation (airway secured) may be shorter than when using conventional techniques. Thirdly, compared to some of the more conventional techniques (awake tracheal intubation with direct laryngoscopy, awake blind nasotracheal intubation and awake fibre-optic tracheal intubation), the two described approaches seemed to be less uncomfortable and stressful to the patient. However, the decision in the second case to induce and paralyse the patient, and then to add cricoid pressure prior to passing the fibroscope/tracheal tube combination through the glottic inlet, was criticised.⁴³ There was no guarantee that movement of the upper airway (gagging, vomiting, swallowing and coughing) would not displace the fibroscope away from the laryngeal aperture, and neither was there certainty that the tracheal tube would follow the fibroscope into the trachea without impacting on the arytenoid or vocal cord.

The disadvantages of both techniques are the need for a fibroscope and limitation to the tracheal tube size that may be employed. Additionally, although airway reflexes are thought to be intact after small doses of sedatives, appreciation of the fact that aspiration may still occur in sedated patients is required. Despite these disadvantages, general support remains for use of the LMA Classic™ as a rescue device in unanticipated difficult and failed tracheal intubation, regardless of the risk of regurgitation or aspiration.⁶⁹ An algorithm that outlines the role of the LMA Classic™ in unanticipated failed tracheal intubation in the patient with a full stomach has been proposed.⁷⁰

The LMA Classic™ as a conduit for tracheal intubation during cricoid pressure

The hypopharynx (laryngopharynx) extends posterior to the arytenoid and cricoid cartilages and becomes the oesophagus distal to the level of the cricoid cartilage. The upper oesophageal sphincter is at the lower border of the cricoid cartilage. The distal segment of the cuff fully occupies the ~ 3.5 cm length of the hypopharynx, the cuff tip rests against the oesophageal sphincter, and the convex aspect of the bowl lies immediately anterior to the second to seventh cervical vertebrae when the LMA Classic™ is seated in its ideal final anatomical position. However, with

cricoid pressure correctly applied, the distal segment of the cuff occupies only the ~ 1.5 cm behind the arytenoid cartilages, and is therefore positioned ~ 2 cm more proximal than is ideal. Although the distal cuff may be wedged into the hypopharynx during the application of cricoid pressure, the plane of the laryngeal aperture, as a result of the cricoid pressure, is then tilted anteriorly ~ 40 degrees around the fulcrum (swivel or pivot) of the inflated cuff.⁷¹ A blindly inserted intubating device would be more likely to enter an aperture perpendicular to the insertion pathway than one at a plane ~ 40 degrees to the insertion pathway.

From this, it is clear that cricoid pressure may interfere with the success of the LMA Classic™ as a conduit for tracheal intubation, firstly because of suboptimal positioning or seating of the LMA Classic™, and secondly owing to the altered plane or angle of the laryngeal aperture. Successful LMA Classic™ placement during cricoid pressure varies from a low of 15%^{72,73} to a more encouraging 90%.⁷⁴ Overall, placement is more likely to be successful without cricoid pressure (92% vs. 66%).⁷³⁻⁷⁹ The application and maintenance of cricoid pressure did not significantly reduce the ease of insertion of the LMA Classic™ or its final position in relation to the oesophagus or epiglottis in 80 ASA I and II patients.⁷⁷ However, cricoid pressure caused an anterior tilt of the laryngeal outlet of ~ 10-40 degrees in every patient, thus worsening the angle of approach for a blindly passed tracheal tube. In this study, neither the amount of pressure applied, nor patient positioning during placement, was specified. Differences in technique of applying cricoid pressure (single handed, double handed or cricoid yoke), technique of insertion, quantity of pressure applied, head and neck position, cuff deflation prior to placement, as well as possible intermittent relaxation of cricoid pressure, may contribute to the widely varying published success rates of use of the LMA Classic™ associated with cricoid pressure.

The success rate of direct blind tracheal intubation with a 6-mm tracheal tube in an elective surgical population decreased to 56% (28/50) from 90% (45/50) when cricoid pressure was maintained throughout the manoeuvre.³⁰ The success rate of direct fibre-optic tracheal intubation in an elective surgical group was studied with cricoid pressure applied prior to placement of the LMA Classic™. Tracheal intubation was accomplished in 95% (19/20) of patients in the control group, and in only 15% (3/20) in the cricoid pressure group, in this double-blind random design study.⁷⁸ With 30-N cricoid pressure applied after placement of a LMA Classic™ in 70 patients randomly allocated to one of two groups, both the time for insertion of a fibrescope, and the time for direct fibre-optic tracheal intubation, was significantly longer in the cricoid pressure group.⁷⁹

As a general rule, both direct and indirect blind tracheal intubation with the LMA Classic™ as a conduit should be attempted with extreme care, and only if no other option

exists. The application of cricoid pressure evidently serves as an aggravating addition to this rule.

The LMA Classic™ as a conduit for tracheal intubation in the patient with an unstable cervical spine

The standard insertion technique involves pressing the LMA Classic™ firmly into the posterior palatopharyngeal curve using the index finger. The pressure exerted against the cervical vertebrae may have implications for the unstable cervical spine. In this regard, it was suggested that an alternative insertion technique, such as the Guedel⁸⁰ technique, be used.⁸¹ Successful direct fibre-optic tracheal intubation of a patient with an unstable cervical spine has been described.⁸² Following intravenous fentanyl and diazepam, the oropharynx was topically anaesthetised and superior laryngeal nerves bilaterally blocked prior to awake placement of the LMA Classic™. A previous attempt at awake direct laryngoscopy and tracheal intubation had failed, and fibre-optic intubation had proved difficult in this patient.

The LMA Classic™ during difficult extubation

The ASA practice guidelines on the management of the difficult airway recommend that the anaesthesiologist should have a preformulated strategy for extubation of such airways. Ellard et al⁸³ described the use of a LMA Classic™ in a patient after complex thyroid surgery involving tracheal resection, and a “guardian suture” placed between the chin and chest. After completion of surgery, and with the patient deeply anaesthetised, the tracheal tube was removed and replaced by a LMA Classic™ as a bridging device. This allowed fibre-optic visualisation of the tracheal repair, tracheal movement and vocal cord function. The patient emerged from anaesthesia and was extubated uneventfully.

Conclusion

The arrival of the LMA during the mid 1980s represents one of the most significant advances in the history of airway management. Benefits derived spill over beyond routine airway management into the fields of airway rescue and intubation of the difficult airway. With regard to the latter, and despite the availability of a range of intubating supraglottic devices, the LMA Classic™ has its rightful place as an intubation conduit. Although blind tracheal intubation with the LMA Classic™ should be restricted to cases where no other options exist, the fibre-optic approach may safely be attempted in expectation of success rates close to 100%.

Opgedra aan Dr Lourens Botha; eggenoot, vader, student, sportman, jagter en vriend (15 Maart 1961 tot 17 Januarie 2014).

References

- Henderson J, Popat M, Latto I, Pearce A. Difficult Airway Society guidelines for management of the unanticipated difficult intubation. *Anaesthesia*. 2004;59(7):675-694.
- Apfelbaum J, Hagberg C. Practice guidelines for management of the difficult airway. An updated report by the American Society of Anesthesiologists' task force on management of the difficult airway. *Anesthesiology*. 2013;118(2):251-270.
- Parmet J, Colonna-Romano P, Horrow J, et al. The laryngeal mask airway reliably provides rescue ventilation in cases of unanticipated difficult tracheal intubation along with difficult mask ventilation. *Anesth Analg*. 1998;87:661-665.
- Jenkins K, Wong DT, Correa R. Management choices for the difficult airway by anesthesiologists in Canada. *Can J Anaesth*. 2002;49(8):850-856.
- Brimacombe J, Brain A, Berry A. The laryngeal mask airway. A review and practical guide. London: WB Saunders; 1997.
- Brain A. The development of the laryngeal mask: a brief history of the invention, early clinical studies and experimental work from which the laryngeal mask evolved. *Eur J Anaesthesiol*. 1991;4:5-17.
- Brimacombe JR. Laryngeal mask anesthesia principles and practice. 2nd ed. London: WB Saunders; 2005.
- Verghese C. LMA-Classic™, LMA-Flexible™, LMA-Unique™. Instruction manual. Henley-on-Thames: The Laryngeal Mask Co Ltd; 1999.
- Berry A, Brimacombe J, McManus K, Goldblatt M. An evaluation of the factors influencing selection of the optimal size of laryngeal mask airway in normal adults. *Anaesthesia*. 1998;53(6):565-570.
- Wat L, Templin P, Lynch M, Hammamura R, White P. Use of the laryngeal mask airway for ambulatory anesthesia; utilization, longevity and cost. *Anesthesiology*. 1996;85:A25.
- Doneley S, Brimacombe J, Keller C, von Goedecke A. The ProSeal™ has a shorter life span than the Classic™ laryngeal mask airway. *Anesth Analg*. 2005;100(2):590-593.
- Miller D. A Proposed classification and scoring system for supraglottic sealing airways: a brief review. *Anesth Analg*. 2004;99(5):1553-1559.
- Billing J, Puspha L, Cyprian M. Tracheal intubation through a single use laryngeal mask airway using a guidewire technique. *Can J Anaesth*. 2007;54(9):775-776.
- Greenland K, Pang G, Donaldson A, Frouws M. Failure of the classic LMA and Aintree catheter with bronchoscope for tracheal intubation while performing manual inline stabilisation. *Anaesth Intensive Care*. 2008;35(2):278-280.
- Manufacturing technical file drawings. Venner Medical (Singapore) Pty Ltd; 2008.
- Benumof J. Laryngeal mask airway and the ASA difficult airway algorithm. *Anesthesiology*. 1996;84(3):686-699.
- Charters P, O'Sullivan E. The "dedicated airway": a review of the concept and an update of current practice. *Anaesthesia*. 1999;54(8):778-786.
- Asai T, Latto P, Vaughan RS. The distance between the grille of the laryngeal mask airway and the vocal cords. Is conventional intubation through the laryngeal mask safe? *Anaesthesia*. 1993;48(8):667-669.
- Alexander R. Do not remove the laryngeal mask airway. *Anesth Analg*. 1999;89(2):536-537.
- Osborn I, Soper R. It's a disposable LMA, just cut it shorter for fiberoptic intubation. *Anesth Analg*. 2003;97(1):299-300.
- Rowbottom S, Simpson D, Grubb D. The laryngeal mask airway in children. A fiberoptic assessment of positioning. *Anaesthesia*. 1991;46(6):489-491.
- Füllekrug B, Pothmann W, Werner C, Schulte J. The laryngeal mask airway: anesthetic gas leakage and fiberoptic control of positioning. *J Clin Anesth*. 1993;5:357-362.
- Nandi P, Nunn J, Charlesworth C, Taylor S. Radiological study of the laryngeal mask. *Eur J Anaesthesiol Suppl*. 1991;4:33-39.
- Pothmann W, Füllekrug B, Schulte J. Fiberoptic determination of the position of the laryngeal mask. *Der Anaesthesist*. 1992;41(12):779-784.
- Atherton DP, O'Sullivan E, Lowe D, Charters P. A ventilation-exchange bougie for fiberoptic intubations with the laryngeal mask airway. *Anaesthesia*. 1996;51(12):1123-1126.
- Henderson J. Development of the "gum-elastic bougie". *Anaesthesia*. 2003;58(1):103-104.
- El-Orbany M, Salem M, Joseph N. The Eschmann tracheal tube introducer is not gum, elastic or a bougie. *Anesthesiology*. 2004;101(5):1240.
- Viswanathan S, Campbell C, Wood D, et al. The Eschmann tracheal tube introducer (gum elastic bougie). *Anesthesiol Review*. 1992;19(6):29-34.
- Brain AJJ. Three cases of difficult intubation overcome by the laryngeal mask airway. *Anaesthesia*. 1985;40(4):353-355.
- Heath M, Allagain J. Intubation through the laryngeal mask. A technique for unexpected difficult intubation. *Anaesthesia*. 1991;46(7):545-548.
- Lim S, Tay D, Thomas E. A comparison of three types of tracheal tube for use in laryngeal mask assisted blind orotracheal intubation. *Anaesthesia*. 1994;49(3):255-257.
- Asai T. Blind tracheal intubation through the laryngeal mask. *Can J Anaesth*. 1996;43(12):1275.
- Heath M. Endotracheal intubation through the laryngeal mask: helpful when laryngoscopy is difficult or dangerous. *Eur J Anaesthesiol Suppl*. 1991;4:41-45.
- Heath M, Allagain J. The brain laryngeal mask airway as an aid to intubation. *Br J Anaesth*. 1990;64:382-383.
- Allison A, McCrory J. Tracheal placement of a gum elastic bougie using the laryngeal mask airway. *Anaesthesia*. 1990;45(5):419-420.
- Gabbot DA, Sasada MP. Tracheal intubation through the laryngeal mask using a gum elastic bougie in the presence of cricoid pressure and manual in line stabilisation of the neck. *Anaesthesia*. 1996;51(4):389-390.
- Ahmed AB, Nathanson MH, Gajraj NM. Tracheal intubation through the laryngeal mask airways using a bougie: the effect of head position. *J Clin Anesth*. 2001;13(6):427-429.
- Brimacombe J, Berry A. Placement of a Cook airway exchange catheter via the laryngeal mask airway. *Anaesthesia*. 1993;48(4):351-352.
- Chadd G, Ackers J, Bailey P. Difficult intubation aided by the laryngeal mask airway. *Anaesthesia*. 1989;44(12):1015.
- Murdoch JA. Emergency tracheal intubation using a gum elastic bougie through a laryngeal mask airway. *Anaesthesia*. 2005;60(6):626-627.
- Miller J, Levsky M, Givens L, Miller M. Eschmann introducer through laryngeal mask airway: a cadaveric trial of an alternate means of rescue intubation. *West J Emerg Med*. 2010;11(1):16-19.
- Arndt G, Cambay A, Tomasson J. Intubation bougie dissection of tracheal mucosa and intratracheal airway obstruction. *Anesth Analg*. 2008;107(2):603-604.
- Benumof J. Laryngeal mask airway. Indications and contraindications. *Anesthesiology*. 1992;77(5):843-846.
- Breen P. Simple technique to remove laryngeal mask airway "guide" after endotracheal intubation. *Anesth Analg*. 1996;82(6):1302.
- Pandit J, MacLachlan K, Dravid R, Popat M. Comparison of times to achieve tracheal intubation with three techniques using the laryngeal or intubating laryngeal mask airway. *Anaesthesia*. 2002;57(2):128-132.
- De Lloyd L, Hodzovic I, Voisey S, et al. Comparison of fibroscope guided intubation via the classic laryngeal mask airway and i-gel in a manikin. *Anaesthesia*. 2010;65(1):36-43.
- Hasham F, Kumar C, Lawler P. The use of the laryngeal mask airway to assist fiberoptic orotracheal intubation. *Anaesthesia*. 1991;46(10):891.
- Hammarskjöld F, Lindskog G, Blomqvist P. An alternative method to intubate with laryngeal mask and see-through-bougie. *Acta Anaesthesiol Scand*. 1999;43(6):634-636.

49. Heard A, Lacquiere D, Riley R. Manikin study of fibreoptic guided intubation through the classic laryngeal mask airway with the Aintree intubating catheter vs the intubating laryngeal mask airway in the simulated difficult airway. *Anaesthesia*. 2010;65(8):841-847.
50. Blair E, Mihai R, Cook T. Tracheal intubation via the Classic™ and ProSeal™ laryngeal mask airways: a manikin study using the Aintree Intubating Catheter. *Anaesthesia*. 2007;62(4):385-387.
51. Berkow L, Schwarts J, Kan K, et al. Use of the laryngeal mask airway-Aintree Intubating Catheter-fibreoptic bronchoscope technique for difficult intubation. *J Clin Anesth*. 2011;23(7):534-539.
52. Higgs A, Clark E, Premraj K. Low-skill fibreoptic intubation: use of the Aintree catheter with the classic LMA. *Anaesthesia*. 2005;60(9):915-920.
53. Cook T, Sellar C, Gupta K, et al. Non-conventional uses of the Aintree Intubating Catheter in management of the difficult airway. *Anaesthesia*. 2007;62(2):169-174.
54. Zura A, Doyle DJ, Orlandi M. Use of the Aintree Intubation Catheter in a patient with an unexpected difficult airway. *Can J Anaesth*. 2005;52(6):646-649.
55. Joffe AM, Arndt G, Willmann K. Wire-guided catheter exchange after failed direct laryngoscopy in critically ill adults. *J Clin Anesth*. 2010;22(2):93-6.
56. Walburn M, Cornes J, Ryder I. Fibreoptic intubation through a laryngeal mask airway facilitated by a guide wire. *Anaesthesia*. 2000;55(10):1027-1028.
57. Sartore DM, Kojima RK. Laryngeal mask airway-assisted, wire-guided fiberoptic tracheal intubation. *Anesthesiology*. 1994;81(6):1550-1551.
58. Arndt G, Topp J, Hannah J, et al. Intubation via the LMA using a Cook retrograde intubation kit. *Can J Anaesth*. 1998;45(3):257-260.
59. Sarma J. Intubation using an LMA and gum elastic bougie. *Anesth Analg*. 2006;102(3):975.
60. Wong D, Yang J, Mak H, Jagannathan M. Use of intubation introducers through a supraglottic airway to facilitate tracheal intubation: a brief review. *Can J Anaesth*. 2012;59(7):704-715.
61. Harvey S, Fishman R, Edwards S. Retrograde intubation through a laryngeal mask airway. *Anesthesiology*. 1996;85(6):1503-1504.
62. Sellers W, Edwards R. Awake intubation with Brain laryngeal airway. *Anaesth Intensive Care*. 1991;19(3):473.
63. Lee M, Absalom A, Menon D, Smith H. Awake insertion of the laryngeal mask airway using topical lidocaine and intravenous remifentanyl. *Anaesthesia*. 2006;61(1):32-35.
64. Brimacombe J. Active swallowing to aid LMA insertion in awake patients. *Anesth Analg*. 1994;78(5):1029.
65. Brimacombe J, Tucker P, Simons S. The laryngeal mask airway for awake diagnostic bronchoscopy. A retrospective study of 200 consecutive patients. *Eur J Anaesthesiol*. 1995;12(4):357-361.
66. Brimacombe J, Newell S, Swainston R, Thompson J. A potential new technique for awake fibreoptic bronchoscopy: use of the laryngeal mask airway. *Med J Aust*. 1992;156(15):876-877.
67. Asai T. Use of the laryngeal mask for tracheal intubation in patients at increased risk of aspiration of gastric contents. *Anesthesiology*. 1992;77(5):1029-1030.
68. Godley M, Reddy R. Use of LMA for awake intubation for caesarean section. *Can J Anaesth*. 1996;43(3):299-302.
69. Tunstall ME. Failed intubation of the parturient. *Can J Anaesth*. 1989;36(6):611-613.
70. Brimacombe J, Berry A, White A. An algorithm for use of the laryngeal mask airway during failed intubation in the patient with a full stomach. *Anesth Analg*. 1993;77(2):398-399.
71. Brimacombe J, Berry A. Cricoid pressure and the LMA: efficacy and interpretation. *Br J Anaesth*. 1994;73(6):862-863.
72. Ansermino J, Blogg C. Cricoid pressure may prevent insertion of the laryngeal mask airway. *Br J Anaesth*. 1992;69(5):465-467.
73. Asai T, Barclay K, Power I, Vaughan RS. Cricoid pressure impedes placement of the laryngeal mask airway. *Br J Anaesth*. 1995;74(5):521-525.
74. Brimacombe J, White A, Berry A. Effect of cricoid pressure on ease of insertion of the laryngeal mask airway. *Br J Anaesth*. 1993;71(6):800-802.
75. Heath M, Allagain J. Intubation through the laryngeal mask: a technique for unexpected difficult intubation. *Anaesthesia*. 1991;46(7):545-548.
76. Gabbot D, Sasada M. Laryngeal mask airway insertion using cricoid pressure and manual in-line neck stabilisation. *Anaesthesia*. 1995;50(8):674-676.
77. Brimacombe J. Cricoid pressure and the laryngeal mask airway. *Anaesthesia*. 1991;46(11):986-987.
78. Asai T, Barclay K, Power I, Vaughn R. Cricoid pressure impedes placement of the laryngeal mask airway and subsequent tracheal intubation through the mask. *Br J Anaesth*. 1994;72(1):47-51.
79. Asai T, Murao K, Shingu K. Cricoid pressure applied after placement of laryngeal mask impedes subsequent fibreoptic tracheal intubation through mask. *Br J Anaesth*. 2000;85(2):256-61.
80. Brimacombe J, Berry A. Insertion of the laryngeal mask airway: a prospective study of four techniques. *Anaesth Intensive Care*. 1993;21(1):89-92.
81. Brimacombe J, Keller C. Laryngeal mask usage in the unstable neck. *Anesth Analg*. 1999;89(2):536.
82. Asai T. Fiberoptic tracheal intubation through the laryngeal mask in an awake patient with cervical spine injury. *Anesth Analg*. 1993;77(2):404.
83. Ellard L, Brown D, Wong D. Extubation of a difficult airway after thyroidectomy: use of a flexible bronchoscope via the LMA-Classic™. *Can J Anesth*. 2012;59:53-57.