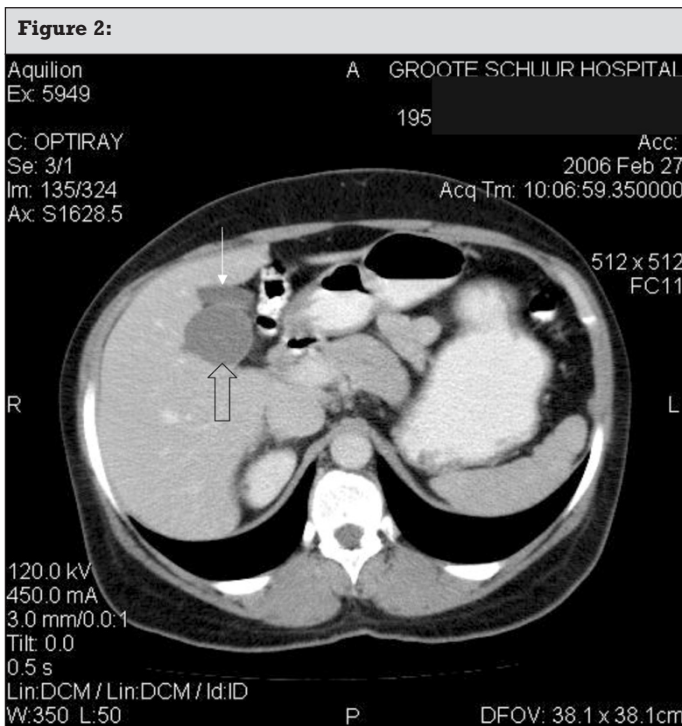


Ciliated hepatic foregut cyst: a rare cystic liver lesion

JM Shaw, JEJ Krige, SJ Beninfield

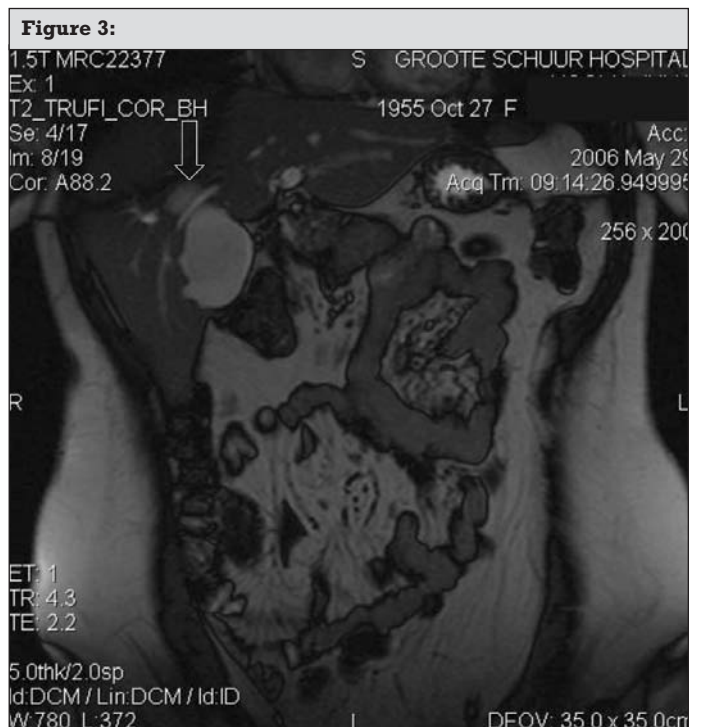
Departments of Surgery and Radiology, University of Cape Town Health Sciences Faculty and Surgical Gastroenterology Unit, Groote Schuur Hospital, Cape Town, South Africa.

Ciliated hepatic foregut cysts (CHFC) are rare congenital cystic lesions of the liver. CHFC are usually asymptomatic but may present with vague abdominal symptoms. CHFC are clinically important because of the possibility of malignant transformation¹ and the diagnostic difficulties CHFC pose. We report the details of a patient with a large, symptomatic CHFC.



Case Report

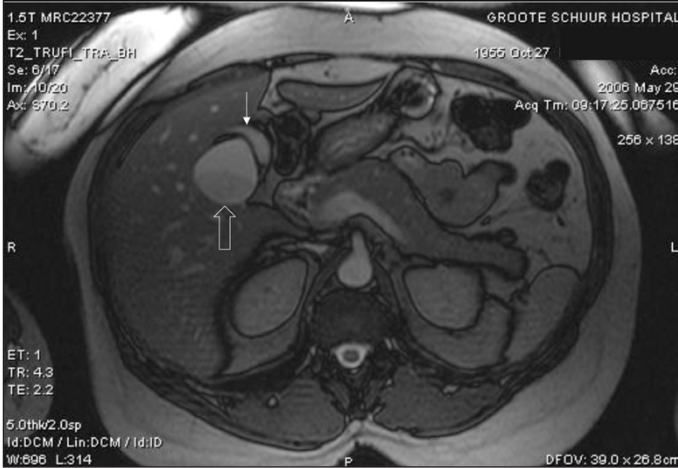A 50-year-old woman presented with a 4-month history of right upper quadrant pain. The pain fluctuated in severity and was controlled with oral analgesic medication. There was no associated jaundice, rigors or weight loss. Apart from minimal right upper quadrant tenderness, examination was unremarkable. Full blood count, liver and renal function tests and clotting profile were normal. The CA 19-9 serum level was 27 IU/l (normal 0-37 IU/l). An abdominal ultrasound scan (US) reported a 50-mm diameter proximal main bile duct with no intra-hepatic biliary dilatation or gallstones, suggesting a type I choledochal cyst. Computed tomography (Figure 2) and magnetic resonance imaging (Figure 3,4) confirmed a cystic mass in the porta hepatis. An MRCP was performed and is shown in Figure 5. Included in the differential diagnosis was a type I choledochal cyst, a Phrygian cap of the gall bladder, biliary cystadenoma, duplicate gallbladder hydatid



Correspondence:

JM Shaw
Department of Surgery
University of Cape Town Health Sciences Faculty
Observatory 7925
Cape Town, South Africa
Tel: -27-21-404 3072
Fax: -27-21-448 0981
E-mail: jshaw@curie.uct.ac.za

Figure 4:



cyst and duplication cyst.

At laparotomy an 8 cm isolated cyst in segment five of the liver was found, displacing the normal gallbladder from its bed. The common bile duct was normal macroscopically and intra-operative cholangiography demonstrated a normal intra- and extra-hepatic biliary system. The cyst had no communication with the biliary system. A retrograde cholecystectomy was performed and the cyst was excised after aspirating its contents. The cyst contained thick green fluid yielding histiocytes on cytology, and the following chemistry: bilirubin 22 µmol/l (normal 5-19), cholesterol 2.4 mmol/l and amylase 422 IU/l. The patient made an uneventful post-operative recovery and was discharged on day 4.

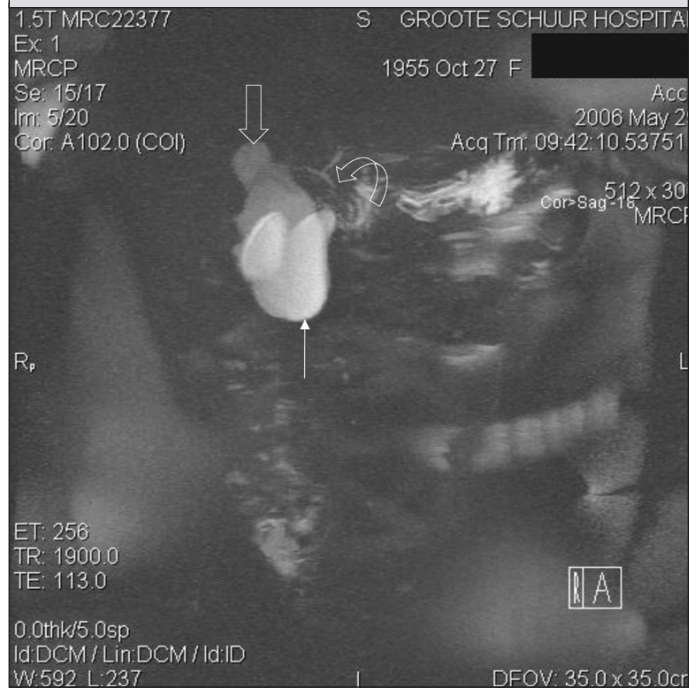Pathology of the specimen showed a fibrous cyst wall lined by pseudostratified ciliated columnar epithelium and a focus of thickened basement membrane reminiscent of respiratory epithelium. No evidence of malignancy was present.

Discussion

Intrahepatic ciliated foregut cysts are rare, with only 67 cases reported since first described as a congenital malformation by Friederich in 1857.² The majority (55) of these cases have been reported in the last 25 years as imaging techniques have improved. CHFC are thought to arise from the embryologic foregut, as do bronchial and oesophageal cysts, but do not contain cartilage.³ Most cases have been reported in adults, and rarely exceed 4cm in diameter. The average age of presentation is 52 years, but ranges from neonates to the ninth decade. Forty percent of the reported cases have been found incidentally on imaging studies, 26% incidentally at autopsy, 6% incidentally at surgery and 22% presented with abdominal symptoms. CHFC are most frequently located superficially in the median segments of the liver (segments 4, 5, 8), are rarely multi-loculated or septated and are mostly asymptomatic.⁴ Although sludge-like bile and viscid mucoid content⁵ of the cyst have been described, as in our patient, no communication with the biliary tree could be demonstrated in any reported cases.

The imaging appearances of CHFC's are variable and appear as anechoic or hypoechoic cysts on ultrasound. CT findings are of a non-enhancing, rounded lesion of varying

Figure 5:



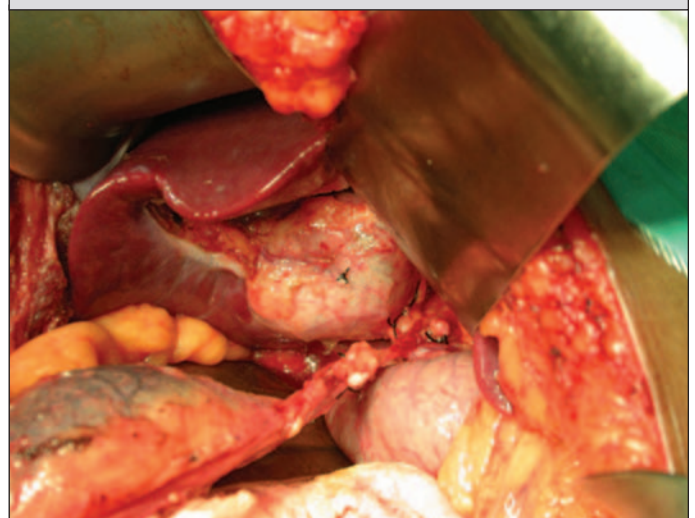
density depending on the contents of the cyst which can include calcium crystals and cholesterol.⁶ Typical MRI features are a hyperintense cyst on T2-weighted images and a variable appearance on T1-weighted images.⁷

Pathologically, the cysts are typically single/solitary and unilocular, and have four layers: an outer fibrous rim, a layer of smooth muscle (often incomplete), subepithelial connective tissue and a lining of ciliated, pseudo-stratified, mucin-secreting columnar epithelium.⁸

The differential diagnosis includes any cystic lesion of the liver, but also noncystic lesions if the cysts contain dense fluid or harbour malignant change.

The management of CHFC is not well established due to the rarity of this finding. Diagnostic uncertainty or misdiagnosis frequently results in surgical exploration, as in our case. Of concern are reports of CHFC harbouring

Figure 1: Intra-operative photograph demonstrating (1) Ciliated hepatic foregut cyst, (2) gallbladder dissected off bed and attached by cystic duct, (3) duodenum



squamous cell carcinoma (4.4% in reported cases)^{1,9,10}, as CHFC was previously thought to be a benign condition. This fact may mandate exploration of all CHFC's diagnosed pre-operatively. There is also a single report of portal vein compression secondary to the mass-effect of the CHFC.¹¹

In conclusion, we report a rare case of a large 8 cm CHFC. The location in segment 5 of the liver and the absence of biliary communication are features consistent with other case reports. Due to the risk of malignant transformation and potential confusion with other benign and non-benign conditions, surgical resection is warranted.

References:

1. Vick DJ, Goodman ZD, Ishak KG. Squamous cell carcinoma arising in a ciliated hepatic foregut cyst. *Arch Pathol Lab Med* 1999; 123:1115-1117.
2. Friederich N. Cyst emit Flimmerepithel in der Leber. *Arch Pathol Anat* 1857; 11:466-469
3. Chatelain D, Chailley-Heu B, Terris B, Molas G, Le Cae A, Vilgrain V, Belghiti J, Degott C, Flejou JF. The ciliated hepatic foregut cyst, an unusual bronchiolar foregut malformation: a histological, histochemical and immunohistochemical study of seven cases. *Human Pathol* 2000;31:241-246
4. Wheeler DA, Edmondson HA. Ciliated hepatic foregut cyst. *Am J Surg Path* 1984; 8:467-470
5. Vick DJ, Goodman ZD, Deavers MT, Cain J, Ishak KG. Ciliated hepatic foregut cyst. A study of six cases and review of the literature. *Am J Surg Path* 1999; 23:671-677
6. Kimura A, Makuuchi M, Takayasu K, Sakamoto M, Hirohashi S. Ciliated hepatic foregut cyst with solid tumour appearance on CT. *J Comput Assist Tomogr* 1990; 14:1016-1018
7. Fang SH, Dong DJ, Zhang SZ. Imaging features of ciliated hepatic foregut cysts. *World J Gastroenterol* 2005; 27:4287-4289
8. Stringer MD, Jones MO, Woodley H, Wyatt J. Ciliated hepatic foregut cyst. *J Pediatr Surg* 2006; 41:1180-1183
9. Furlanetto A, Dei Tos AP. Squamous cell carcinoma arising in a ciliated hepatic foregut cyst. *Virchows Arch* 2002; 441:296-298
10. De lajarte-Thirourard AS, Rioux-leclercq N, Boudjema K, gandon Y, Ramee MP, Turlin B. Squamous cell carcinoma arising in a hepatic foregut cyst. *Pathol Res Pract* 2002;198:697-700
11. Harty MP, Hebra A, Ruchelli ED, Schnauffer L. Ciliated hepatic foregut cyst causing portal hypertension in an adolescent. *Am J Roentgenol* 1998; 170:688-690