

# Does the knowledge of the human immunodeficiency virus serostatus influence the clinical diagnostic proficiency of Kaposi's sarcoma?

Van Bogaert LJ, MD, PhD, DPhil, Consultant Pathologist

National Health Laboratory Service, Polokwane Mankweng Hospital Complex and University of Limpopo

Correspondence to: Louis-Jacques van Bogaert, e-mail: louis.vanBogaert@nhls.ac.za

Keywords: Kaposi's sarcoma, mimics, clinical diagnosis, HIV

## Abstract

**Objectives:** Kaposi's sarcoma is an acquired immunodeficiency syndrome (AIDS)-defining illness. A spectrum of non-Kaposi's sarcoma clinical and histopathological mimickers contributes to the potential over- or underdiagnosis of Kaposi's sarcoma. The aim of this audit was to investigate the clinical diagnostic accuracy of Kaposi's sarcoma and to find out whether or not knowledge of the human immunodeficiency virus (HIV) serostatus influenced the clinical diagnostic accuracy.

**Design:** Cross-sectional study of 511 mucocutaneous biopsies.

**Settings and subjects:** All the biopsies were from African patients from the Limpopo province. The HIV seropositive status was known in 327 cases (64.2%). The clinical diagnosis, provided in 369 cases (72.2%) was compared with the biopsy. A Kaposi's sarcoma herpesvirus-positive immunophenotype on biopsy served as the diagnostic gold standard.

**Outcome measure:** Concordance or discordance between the clinical provisional diagnosis and the histopathological gold standard.

**Results:** The rate of provisional clinical diagnosis of non-Kaposi's sarcoma in biopsy-proven Kaposi's sarcoma was 18.1% in HIV-positive, and 39.5% in HIV unknown, serostatus (chi-square 11.8, p-value = 0.0006). The concordance between the clinical diagnosis and biopsy was 76.5% in the HIV-positive, and 49.9% in the HIV-unknown, cases (chi-square 16.9, p-value < 0.0001).

**Conclusion:** Knowledge of the patient's serostatus significantly improved the clinical diagnostic accuracy of Kaposi's sarcoma. Biopsy remains the diagnostic gold standard.

Peer reviewed. (Submitted: 2012-10-23. Accepted: 2013-01-09.) © SAAFP

S Afr Fam Pract 2013;55(5)473-476

## Introduction

Kaposi's sarcoma is a life-threatening vasoproliferative disorder of endothelial (most likely lymphatic) origin.<sup>1</sup> In all its manifestations, i.e. classic or sporadic, iatrogenic or post-transplant, endemic or African, and acquired immune deficiency syndrome (AIDS)-related/human immunodeficiency virus (HIV)-associated, the causal agent is the human herpesvirus 8 (HHV 8) or Kaposi's sarcoma-associated herpes virus identified in 1994.<sup>2</sup> The latent nuclear antigen 1 (LANA-1) of HHV 8 is expressed in the nucleus of infected cells and is identifiable immunohistochemically in Kaposi's sarcoma biopsies. It is currently recommended as the gold diagnostic standard.<sup>1,3</sup>

The classical clinical expression of Kaposi's sarcoma is a violaceous, dark mucocutaneous macule or plaque.

However, this is not specific, especially in dark-skinned individuals. For instance, seborrheic keratosis is a very common dark-brown, single or multiple skin lesion that may be found on any part of the body.<sup>4</sup> Granuloma pyogenicum and angiomas are also very common, dark, violaceous vasoproliferative lesions that may be multiple and occur anywhere on the skin.<sup>5</sup>

Kaposi's sarcoma is an AIDS-defining condition that has been on the increase since the inception of the AIDS epidemic.<sup>6-8</sup> Furthermore, it has become difficult to distinguish between the endemic or African and HIV-associated forms of Kaposi's sarcoma.<sup>9</sup> They differ in their prognosis and management.<sup>10</sup> Because of the prognostic and therapeutic implications, it is of utmost importance to make the correct diagnosis of Kaposi's sarcoma. It might

be beneficial to patients suffering from Kaposi's sarcoma to be tested for HIV since the unavailability of, or lack of information about, HIV serology results, do not rule out the possibility of HIV infection.

The aim of this study was to find out whether or not knowledge of HIV status would affect proficiency in the clinical diagnosis of Kaposi's sarcoma and differential diagnosis with its non-Kaposi's sarcoma mimickers.

### Method

The study was a prospective observational one. The material consisted of 511 consecutive biopsies collected prospectively between May 2010 and August 2012. The specimens originated from public health facilities in the Limpopo province. The biopsies were processed at the histopathology laboratory of the Polokwane Mankweng Hospital Complex. All the cases were routinely streptavidin-biotin-peroxidase immunostained with diaminobenzidine, and a murine monoclonal antibody directed against the C terminal of the LANA-1 molecule of HHV 8 (Novocastra Laboratories, Newcastle-upon-Tyne, UK).

The following information was recorded from the biopsy request form and the laboratory database: age, gender, HIV status and CD4 T-cell count (where available), treatment, site of biopsy and clinical provisional diagnosis (where available). The clinical concordance and discordance rates were calculated only for cases with an available provisional diagnosis. Concordance meant that the clinical provisional diagnosis tallied with the LANA-1 positive biopsy diagnosis of Kaposi's sarcoma. Discordance meant that the clinical provisional diagnosis of non-Kaposi's sarcoma was disproved by a biopsy diagnosis of Kaposi's sarcoma. Since all the cases were treated anonymously, ethical approval was not deemed to be necessary.

The limitation of the study was reliance on the information provided on the request form by the clinicians. It cannot be ruled out that the clinicians had a provisional diagnosis. However, mentioning a violaceous skin lesion was not deemed to be a provisional diagnosis.

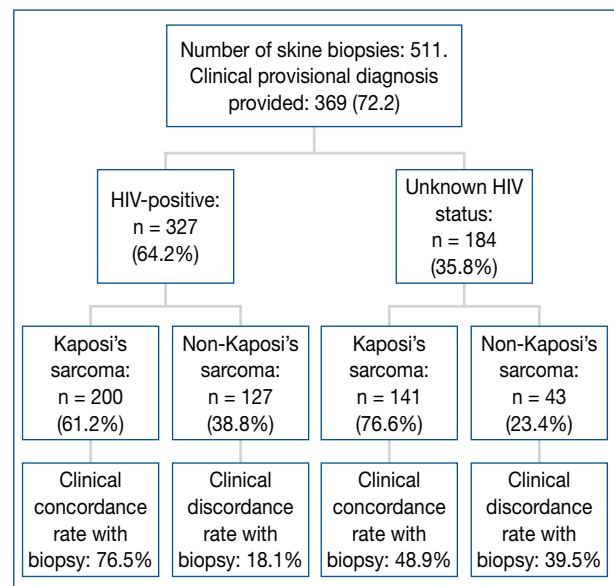
Statistical analysis was carried out using column statistics, contingency table analysis, and 95% confidence intervals (CI) for proportions. Overlapping CIs were not considered to be significant. The level of statistical significance was set at p-value <0.05.

### Results

Figure 1 illustrates the distribution of the cases. A provisional clinical diagnosis was provided in 72.2% instances. There were 341 (66.7%) biopsy-confirmed cases of Kaposi's sarcoma, 200 (58.7%) in HIV-positive

patients, and 141 (41.3%) in patients with unknown HIV status. There were 170 cases of non-Kaposi's sarcoma or Kaposi's sarcoma mimickers: 127 (74.7%) in HIV-positive patients, and 43 (25.3%) in patients with unknown HIV status. Two documented HIV-negative biopsy-proven cases of Kaposi's sarcoma were excluded.

The HIV-positive cases of Kaposi's sarcoma included 185 (56.6%) males and 142 (43.4%) females of similar mean age (Table I). The male-to-female ratio was 1.30:1. One hundred and thirty-three (40.7%) were documented to be on highly active antiretroviral treatment (HAART) and 28 (8.6%) were not. The HAART status of the other 166



HIV: human immunodeficiency virus

Figure 1: Flow chart of cases entering the audit

Table I: Age distribution according to gender and human immunodeficiency virus serostatus

Gender	HIV-positive	HIV status unknown	t	p-value
Males	40.3 ± 11.4 [40] (4-68)*	44.3 ± 14 [43.5] (11-78)***	2.4	0.02
Females	38.8 ± 11.4 [36] (8-71)**	44.9 ± 19.7 [41] (7-100)****	2.1	0.03

HIV: human immunodeficiency virus

\* vs. \*\*: t = 1.2, p-value = 0.24, \*\*\* vs. \*\*\*\*: t = 0.2, p-value = 0.83

Table II: Anatomic distribution of Kaposi's sarcoma

Anatomical site	HIV-positive n = 139	HIV status unknown n = 96	Statistical significance
Head and neck	13 (9.4)*	17 (17.7)	NS**
Trunk	6 (4.3)	4 (4.2)	NS
Upper limb	4 (2.9)	7 (7.3)	NS
Lower limb	74 (53.2)	50 (52.1)	NS
Anogenital	4 (2.9)	6 (6.3)	NS
Disseminated	61 (43.9)	12 (12.5)	SS***

HIV: human immunodeficiency virus

\*: Values are numbers (%); \*\*: not significant; \*\*\*: statistically significant by 95% confidence interval

(50.7%) was unknown. The CD4+ T-cell counts/microlitre was documented in 64 cases:  $260.9 \pm 196.8$  (median of 219, range of 6-877). Thirty (46.9%) were  $< 200$  and seven (11%)  $> 500$ .

The cases of Kaposi's sarcoma with unknown HIV status included 75 males (53.2%) and 66 females (46.8%) of similar mean age (Table I). The male-to-female ratio was 1.14:1.

The anatomical distribution was known in 139 (69.5%) HIV-positive patients and 96 (68.9%) patients with unknown HIV status (Table II). There was a statistically significant higher proportion of disseminated Kaposi's sarcoma in the HIV-positive group.

The concordance rate in HIV-positive cases was significantly higher than that in the HIV-unknown cases [chi-square 16.8,  $p$ -value  $< 0.0001$ , relative risk (RR) 1.97 (1.34-2.84)]. It is likely that the presence of disseminated Kaposi's sarcoma lesions (54 out of 153 HIV-positive cases with provisional diagnosis) contributed to the improved concordance rate. The discordance rate was significantly lower in the HIV-positive, than in the unknown, HIV serostatus group [chi-square 11.8,  $p$ -value 0.0006, RR of 0.54 (0.36-0.81)]. Seborrhic keratosis and granuloma pyogenicum accounted for 38.2% of the discordances.

## Discussion

The treatment of life-threatening conditions requires a well-established diagnosis. This obviously applies equally to HIV/AIDS and its manifestations, such as Kaposi's sarcoma. It is in the patient's interest to be aware of his or her HIV serostatus in order to access appropriate treatment. On the other hand, it is also important not to treat patients unnecessarily on the basis of an incorrect or unsubstantiated diagnosis. A discordance rate between the clinical provisional diagnosis, when available, and the gold standard between 20% and 40%, illustrates the need for better clinical proficiency and biopsy confirmation.

The treatment of classic and endemic Kaposi's sarcoma depends on the extension of the disease. Excisional biopsy often provides adequate treatment for single lesions. An intralesional injection of interferon alpha-2b is an attractive alternative devoid of systemic toxicity. Radiation therapy, preferably with megavoltage electrons, is an option for a few lesions in a limited area. Patients with extensive or recurrent Kaposi's sarcoma can be treated with a combination of surgery and chemoradiation.<sup>11</sup>

The incidence of Kaposi's sarcoma has dropped since the introduction of HAART.<sup>12</sup> It is estimated that Kaposi's sarcoma responds to HAART in approximately half of all cases.<sup>12-13</sup> HAART helps to halt the progression and decline of viral loads of epidemic or HIV-associated Kaposi's sarcoma, but this is unpredictable. The response to radiation

therapy is less durable and chemotherapy provides lower and shorter response rates.<sup>6,11</sup> However, no treatment prevents new lesions from developing.<sup>13</sup> That sounds rather ominous, especially in the sub-Saharan African context of poor access to HAART.<sup>14-16</sup>

In a vast majority of cases, Kaposi's sarcoma is the first AIDS-defining illness. Having Kaposi's sarcoma as an AIDS-defining illness and an increasing CD4 count improves the prognosis. An age of  $\geq 50$  years and having another AIDS-defining illness at the same time conveys a poorer prognosis.<sup>17</sup> These factors predict evolution and the need for chemotherapy.<sup>18</sup>

Although African or endemic Kaposi's sarcoma has been known for more than 50 years, one can but speculate on the accuracy of the diagnosis, clinical and/or histopathological, made before the era of HHV 8 immunophenotyping. According to a Ugandan study of 117 cases of HIV-seronegative Kaposi's sarcoma, 78% were male, and 57% were above the age of 35.<sup>19</sup> In a small series of 13 cases of Nigerian Kaposi's sarcoma, multiple lesions were more common in HIV-positive cases, and limbs and trunk were more frequently involved in HIV-negative cases.<sup>20</sup> In a Tanzanian report of 67 cases of HIV-positive and 11 of HIV-negative Kaposi's sarcoma, all endemic forms were in males. Only the lower limbs were involved.<sup>21</sup> The male-to-female ratio was 5.7:1 in a small Nigerian series of 20 cases of HIV-positive Kaposi's sarcoma. The lower limbs were involved in 44%.<sup>22</sup> A South African report on 152 cases of HIV-associated Kaposi's sarcoma found an equal gender distribution. Females were significantly younger, had a poorer prognosis and more extensive skin involvement than males.<sup>23</sup> In our series, there was no gender-related age difference. Disseminated Kaposi's sarcoma was significantly more common in HIV-positive patients. It seems that no firm conclusion can be drawn about gender and the anatomical distribution of endemic, versus AIDS-associated, Kaposi's sarcoma.

What is important is that the correct diagnosis of Kaposi's sarcoma is made. Of concern is the fact that no provisional diagnosis was carried out in close to 30% of the cases, and that Kaposi's sarcoma was over- or underdiagnosed in a high percentage of instances (18.1 and 39.5%, respectively). Knowledge of the HIV serostatus is not only beneficial for the patient, but improves the clinical diagnostic proficiency that is likely to motivate taking a biopsy. A medical audit is part of the process of improving the quality of healthcare provision.<sup>24</sup> The present audit demonstrates the need to improve clinical diagnostic skills. Knowledge of the patient's serostatus significantly improves the clinical diagnostic accuracy of Kaposi's sarcoma. However, biopsy confirmation is recommended in view of the high rates of clinical over- and underdiagnosis of Kaposi's sarcoma.

## References

1. Pyakurel P, Pak F, Mwakigonja AR, et al. Lymphatic and vascular origin of Kaposi's sarcoma spindle cells during tumor development. *Int J Cancer*. 2006;119(6):1262-1267.
2. Chang Y, Cesarman E, Pessin MS, et al. Identification of herpesvirus-like DNA sequences in AIDS-associated Kaposi's sarcoma. *Science*. 1994;266(5192):1865-1869.
3. Dupin N, Fisher C, Kellam P, et al. Distribution of human herpesvirus-8 latently infected cells in Kaposi's sarcoma, multicentric Castleman's disease, and primary effusion lymphoma. *Proc Natl Acad Sci USA*. 1999;96(8):4546-4551.
4. Kirkham N. Tumors and cysts of the epidermis. *Lever's histopathology of the skin*. 10<sup>th</sup> ed. In: Elder DE, editor. Philadelphia: Lippincott Williams & Wilkins, 2009; p. 795.
5. Calonje E. Vascular tumors: tumors and tumor-like conditions of blood vessels and lymphatics. *Lever's histopathology of the skin*. 10<sup>th</sup> ed. In: Elder DE, editor. Philadelphia: Lippincott Williams & Wilkins, 2009; p. 1015.
6. Aldenhoven M, Barlo NP, Sanders CJG. Therapeutic strategies for epidemic Kaposi's sarcoma. *Int J STD AIDS*. 2006;17(9):571-578.
7. Mbulaiteye SM, Katabira ET, Wabinga H, et al. Spectrum of cancers among HIV-infected persons in Africa: the Uganda AIDS-Cancer Registry Match Study. *Int J Cancer*. 2006;118(4):985-990.
8. Parkin DM. The global health burden of infection-associated cancers in the year 2002. *Int J Cancer*. 2006;118(12):3030-3044.
9. Mwanda OW, Fu P, Collea R, Whalen C, Remick SC. Kaposi's sarcoma in patients with and without human immunodeficiency virus infection in a tertiary referral centre in Kenya. *J Trop Med Parasit*. 2005;99(1):81-91.
10. Chu KM, Mahlangeni G, Swannet S, et al. Aids-associated Kaposi's sarcoma is linked to advanced disease and high mortality in a primary care HIV programme in South Africa. *J Int AIDS Soc*. 2010;13(1):23-27.
11. Antman K, Chang Y. Kaposi's sarcoma. *N Engl J Med*. 2000;342(1):1027-1038.
12. Nasti G, Talamini R, Antinori A, et al. AIDS-related Kaposi's sarcoma: evaluation of potential new prognostic factors and assessment of the AIDS Clinical Trial Group staging system in the HAART era: the Italian Cooperative Group on AIDS and tumors and the Italian cohort of patients naïve from antiretrovirals. *J Clin Oncol*. 2003;21(15):2876-2882.
13. Cai Q, Verma SC, Liu J, Robertson ES. Molecular biology of Kaposi's sarcoma herpesvirus and related oncogenesis. *Adv Virus Res*. 2010;78:87-142.
14. Dedicoat M, Vaithilingum M, Newton R. Treatment of Kaposi's sarcoma in HIV-1 infected individuals with emphasis on resource poor settings. [Cochrane Review]. In: The Cochrane Library, Issue 3, 2003. Oxford: Update Software.
15. Sissolok G, Mayaud P. AIDS-related Kaposi's sarcoma: epidemiological diagnostic, treatment and control aspects in sub-Saharan Africa. *Trop Med Int Health*. 2005;10(10):981-992.
16. Mosam A, Aboobaker J, Shaik F. Kaposi's sarcoma in sub-Saharan Africa: a current perspective. *Curr Opin Infect Dis*. 2010;23(2):119-123.
17. Stebbing J, Sanitt A, Nelson M, et al. A prognostic index for AIDS-associated Kaposi's sarcoma in the era of highly active antiretroviral therapy. *Lancet*. 2006;367(9521):1495-1502.
18. El Amari EB, Toutous-Trellu L, Gayet-Ageron A, et al. Predicting the evolution of Kaposi's sarcoma in the highly active antiretroviral era. *AIDS*. 2008;22(9):1019-1028.
19. Ziegler J, Newton R, Bourboullia D, et al. Risk factors for Kaposi's sarcoma: a case-control study of HIV-seronegative people in Uganda. *Int J Cancer*. 2003;103(2):223-240.
20. Mohammed AZ, Nwana EJ, Manasseh AN. Changing patterns of Kaposi's sarcoma in Nigerians. *Trop Doc*. 2005;35(3):168-169.
21. Wamburu G, Masenga EJ, Moshi EZ, et al. HIV-associated and non-HIV associated types of Kaposi's sarcoma in an African population in Tanzania. Status of immune suppression and HHV-8 prevalence. *Eur J Dermatol*. 2006;16(6):677-682.
22. Kagu MB, Nggada HA, Garandawa HI, et al. AIDS-associated Kaposi's sarcoma in Northeastern Nigeria. *Singapore Med J*. 2006;47(12):1069-1074.
23. Mosam A, Hurkchand HP, Cassol E, et al. Characteristics of HIV-1 associated Kaposi's sarcoma among women and men in South Africa. *Int J STD AIDS*. 2008;19(6):400-405.
24. Von Pressentin KB, Conradie HH, Mash R. A medical audit of the management of cryptococcal meningitis in HIV-positive patients in the Cape Winelands (East) district, Western Cape. *S Afr Fam Pract*. 2012;54(3):339-346.