

When to be concerned about a conjunctival growth

Labuschagne MJ, MBChB, MMed(Ophth), PhD(HPE)

Clinical Simulation Unit, School of Medicine, Faculty of Health Sciences, University of the Free State, Bloemfontein

Correspondence to: Mathys Labuschagne, e-mail: labuschagnemj@ufs.ac.za

Key words: eye, conjunctiva, growth, lesion, benign, malignant

Abstract

Because of various contributing factors such as exposure to ultraviolet (UV) light, especially UV type B radiation, and the high prevalence of human immunodeficiency virus (HIV) infection in South Africa, medical practitioners are often consulted by patients with conjunctival growths. However, the diagnosis of conjunctival lesions is challenging, and it may be difficult to clinically distinguish between benign and malignant lesions. The aim of this article is to present a synopsis of conjunctival growths, and propose a practical approach to making the correct diagnosis and implementing appropriate management.

© Peer reviewed. (Submitted: 2013-01-16, Accepted: 2013-02-17). © SAAFP

S Afr Fam Pract 2013;55(5):421-425

Introduction

Medical practitioners are often consulted by patients with conjunctival growths. Patients usually complain about the associated appearance, discomfort or irritation. The medical practitioner may be challenged to make a correct diagnosis and to manage a condition appropriately when faced with a problematic clinical situation. Furthermore, it may be difficult to clinically distinguish between benign and malignant lesions.

Exposure to sunlight, especially ultraviolet (UV) type B (UVB) radiation, may play an important role in the development of p53 mutations (tumour-suppressor genes) within the limbal epithelial cells, which contribute to the growth of pingueculae, pterygia and limbal tumours.¹⁻³ The two main risk factors for the development of ocular surface squamous neoplasia (OSSN) include UVB exposure and HPV.^{2,4,5} Other risk factors include exposure to petroleum products, cigarette smoking, ocular surface injury, vitamin A deficiency, being of Caucasian ethnicity, and chemicals, such as trifluridine and arsenicals.^{2,4,5} Human immunodeficiency virus (HIV) infection is currently regarded as a major risk factor for the development of OSSN.^{2,4} In the South African context, with the widespread exposure to ultraviolet light and the high incidence of HPV and HIV, these conditions are becoming increasingly important. Therefore, primary healthcare workers and general practitioners should be able to recognise such lesions, make the correct diagnosis and manage the condition properly.

The most important conjunctival growths are summarised in Figure 1. Congenital conjunctival lesions have been excluded from this discussion. The aim of this article is to present a synopsis of conjunctival growths and propose a practical approach on how to make the correct diagnosis and implement appropriate management.

Pingueculum

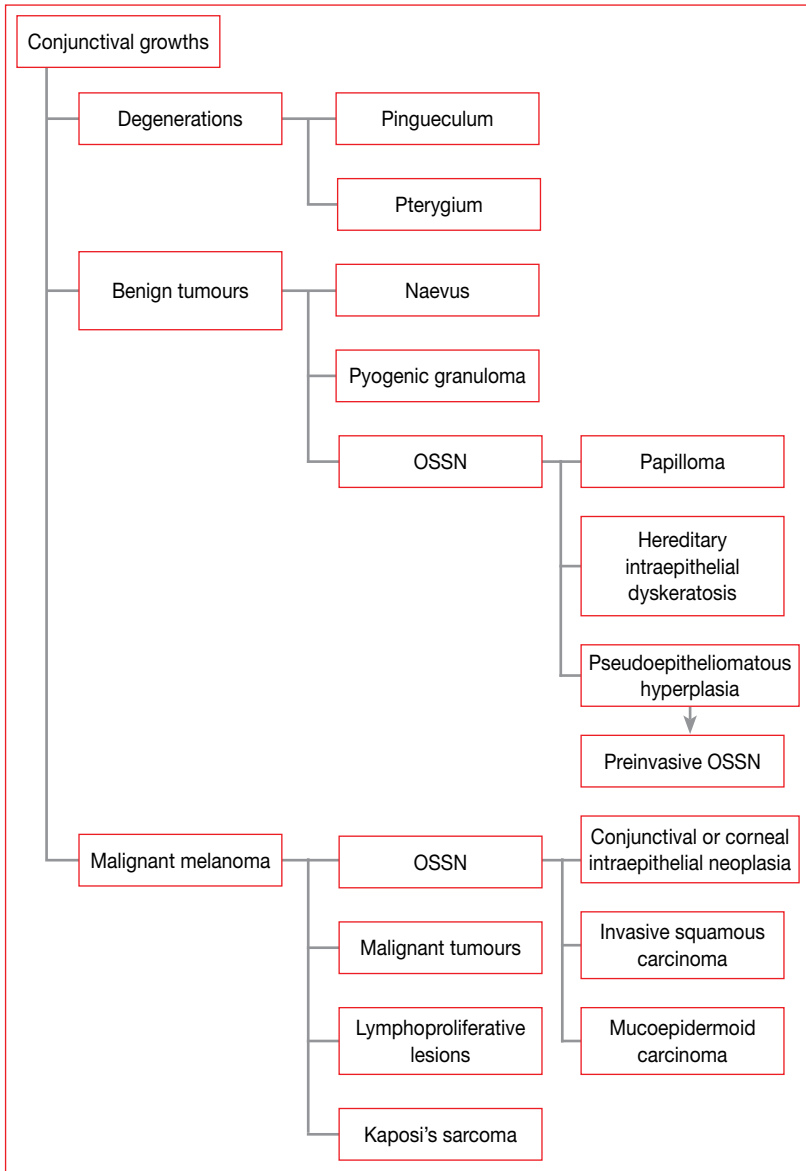
Pingueculae are extremely common in middle age or later in life,^{1,6} and are often bilateral and asymptomatic. A pingueculum presents with a localised elevated, yellowish area on the bulbar conjunctiva in the exposed area, usually nasally or temporally, near the limbus. Histologically, the appearance is identical.¹

Management is not necessarily required, but should inflammation (pingueculitis) occur, it could be treated with nonsteroidal anti-inflammatory eyedrops or a short course of a weak steroid, such as fluorometholone.

Pterygium

Pterygium is a common disorder in many parts of the world. Exposure to UVB light in solar radiation has been found to be the major environmental factor in the development of pterygia.³ Recent studies have suggested that p53 and HPV may be implicated in pterygium pathogenesis. Therefore, pterygia are not merely degenerative, but could be the result of uncontrolled cell proliferation or localised limbal stem cell deficiency.³

A pterygium usually presents as a triangular fibrovascular subepithelial ingrowth of bulbar conjunctival tissue over the limbus onto the cornea. Pterygia can be divided into three types. Type 1 extends less than 2 mm onto the cornea and is usually asymptomatic, although contact lens users may have symptoms at an earlier stage. Type 2 involves 2-4 mm of the cornea and may interfere with the tear film and induce astigmatism. Type 3 invades more than 4 mm of the cornea and involves the visual axis. Figure 2 a-c represents examples of type 1, 2 and 3 pterygia.



OSSN: ocular surface squamous neoplasia

Figure 1: Summary of conjunctival growths, with the exclusion of congenital conjunctival lesions

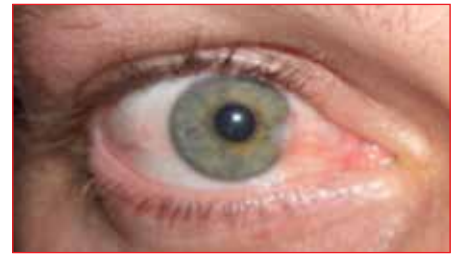


Figure 2 a: Type 1 pterygium

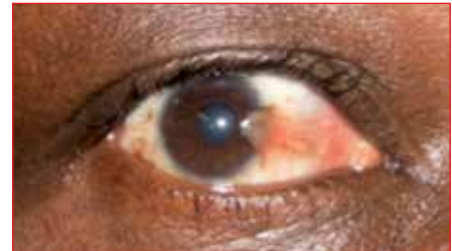

Figure 2 b: Type 2 pterygium

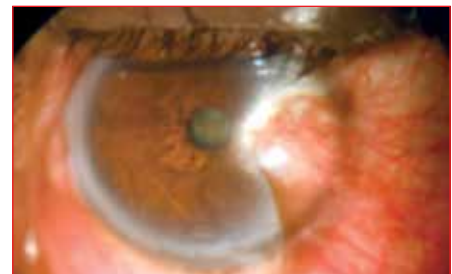

Figure 2 c: Type 3 pterygium

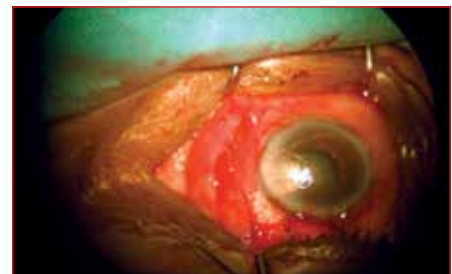

Figure 3: Conjunctival autograft rotational flap after pterygium excision

Management of a pterygium involves excising the pterygium and preventing recurrence, as the recurrence rate is estimated to be 30% with the bare sclera technique, down to 5.3% with other methods. Because the bare sclera technique has a very high recurrence rate, the excision is often combined with conjunctival autograft, mitomycin C, beta radiation or other adjunctive therapies to reduce recurrence rates. Currently, there is no consensus on ideal treatment of the condition.^{3,6} A conjunctival autograft rotational flap is illustrated in Figure 3. The area excised from the corneal surface can be seen clearly on the photograph.

Conjunctival naevus

Conjunctival naevus is relatively uncommon, usually unilateral and benign. The naevus most commonly presents during the first two decades of life as a pigmented lesion

or irritation of the eye. It may present on any part of the conjunctiva, but generally occurs on the bulbar conjunctiva. The naevus is mostly solitary and well demarcated, and pigmentation may vary from non-pigmented to dark pigmented. Signs of potential malignancy include extension onto the cornea, palpebral or forniceal position, sudden signs of growth and colour changes, or the development of vascularity (feeder vessels).^{1,6} In most cases, no treatment is required. Simple excision can be performed for cosmetic reasons or when malignancy is suspected.

Pyogenic granuloma

Pyogenic granulomas are commonly seen after conjunctival injury or surgery. A pyogenic granuloma presents as a vascularised nodule of the bulbar or palpebral conjunctiva, and usually bleeds when touched. The lesions are mostly

treated with topical antibiotics. Surgical removal may often be required.

Ocular surface squamous neoplasia (OSSN)

OSSN includes a wide spectrum of dysplastic changes of the squamous epithelium of the ocular surface (conjunctiva and cornea). A wide range of changes may occur, from benign to invasive squamous cell carcinoma. The classification of OSSN is based on the degree of epithelial or stromal infiltration.^{1,4,5}

Benign OSSN lesions include papilloma, pseudoepitheliomatous hyperplasia and benign hereditary intraepithelial dyskeratosis.

Papilloma of the conjunctiva

Squamous papillomas are usually pedunculated, benign tumours of the conjunctiva.^{1,7} These papillomas are caused by HPV and typically occur in children and young adults. The papillomas usually present with finger-like projections in the palpebral conjunctiva, fornix or caruncle, and can be multifocal or bilateral. The lesions often resolve spontaneously, but can be excised with the application of cryotherapy at the base of the lesion, which may reduce the risk of recurrence.

Conjunctival intraepithelial neoplasia

The preinvasive OSSN lesions are confined to the epithelium, and the intraepithelial neoplasia can affect the conjunctiva or cornea. This is a premalignant condition and the lesions are usually located at the limbus. The adjacent cornea may be involved. Treatment comprises complete surgical excision and supplemental cryotherapy.

Squamous cell carcinoma of the conjunctiva

When the tumour cells invade the basement membrane into the conjunctival or corneal stroma, the lesions are called invasive squamous cell carcinoma (SCC) and mucoepidermoid carcinoma respectively.⁴ Lesions can present as an elevated conjunctival mass usually seen in the limbal area, are grey-white in colour and with a tuft of blood vessels running to the lesion. They are commonly situated in the interpalpebral fissure area, and may become fleshy with feeder vessels. Currently, SCC is the most common ocular tumour in adults in Africa.² Furthermore, OSSN in Africa seems to be more aggressive and more likely to affect young adults, especially females and HIV-infected persons.^{2,8,9}

Mucoepidermoid carcinoma

Mucoepidermoid carcinoma is similar to SCC, but is more aggressive and may arise anywhere on the conjunctiva.⁸

The clinical appearance of the range of OSSN lesions is demonstrated in Figures 4 a-d.

The therapeutic options to manage OSSN include surgical excision with wide surgical margins. Recurrence of the lesions are reported to be as high as 33% with clear histological margins, and 55% with margins that are not histologically clear.^{2,4} Adjunctive cryotherapy of the conjunctival margins reduces the recurrence rate. Topical chemotherapies, which have been proven to be the effective treatment for OSSN, include mitomycin C, 5-fluorouracil and immunotherapy with interferon alpha 2b. There is the advantage of treating the entire ocular surface, and avoiding wide excision and the risk of stem cell deficiency when using local medical therapy.² In cases where invasive SCC of the ocular surface spreads through the sclera, or into the extraocular muscles or the orbital tissue, the surgical approach may require mutilating surgery, such as orbital exenteration.

Conjunctival malignant melanoma

Malignant melanoma of the conjunctiva is an uncommon malignant tumour and may develop *de novo*, from primary acquired melanosis or from a naevus. Clinically, it presents as an elevated nodule and well vascularised mass with large conjunctival feeder vessels, and is fixed to the underlying sclera. The tumour may be pigmented or non-pigmented (amelanotic). Advanced melanomas may invade the orbit or the eyelids. These tumours are treated using local excision with cryotherapy, local radiation and exenteration if the tumour has spread into the orbit. Chemotherapy may be used if metastases are present.⁸

Lymphoproliferative lesions of the conjunctiva

Lymphoproliferative lesions are a rare condition of the conjunctiva. The clinical appearance is a smooth, fleshy, subconjunctival mass that can implicate a large surface area in the bulbar or forniceal conjunctiva. The lesions may be solitary or multiple. The condition may involve both eyes in 20% of cases.⁸ Affected areas are called "salmon patches". Incisional or excision biopsy should be performed. Systemic evaluation of the patient by a physician and oncologist is recommended.

Kaposi's sarcoma of the conjunctiva

Kaposi's sarcoma, often seen in patients with acquired immune deficiency syndrome (AIDS),^{1,8} commonly occurs on the eyelid skin, but may also affect the conjunctiva. The tumour can present as a reddish conjunctival lesion and may be diffuse or vascular. The diffuse variant may resemble a subconjunctival haemorrhage. A spontaneous subconjunctival haemorrhage that does not clear up within two weeks should raise a high level of suspicion that it might be Kaposi's sarcoma. The treatment usually comprises antiretroviral drugs and chemotherapy, and on rare occasions, excision, radiotherapy or cryotherapy.^{6,7}

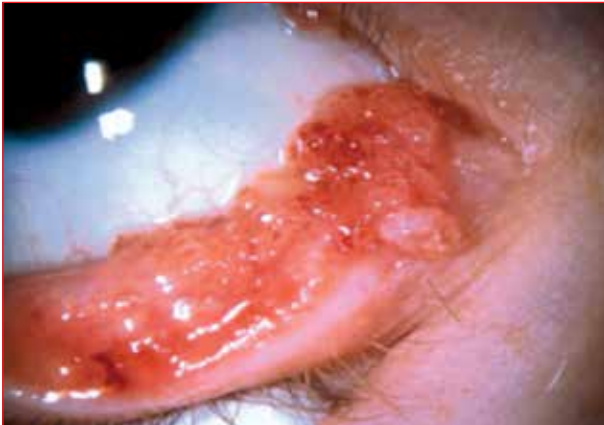

Figure 4 a: Papilloma

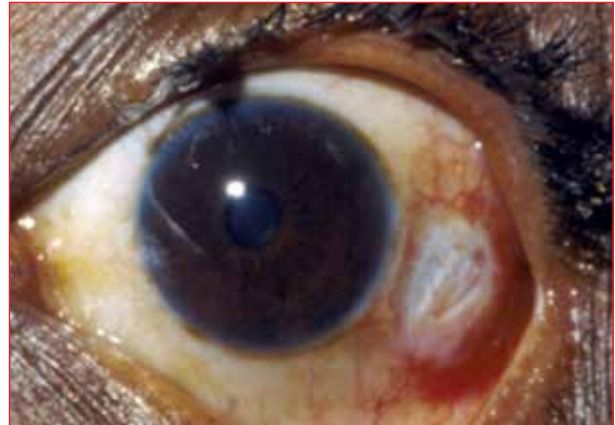


Figure 4 b: Squamous cell carcinoma of the conjunctiva

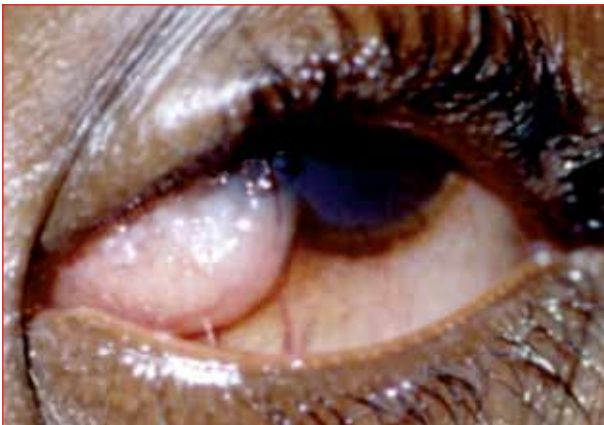


Figure 4 c: Squamous cell carcinoma, affecting the conjunctiva and cornea

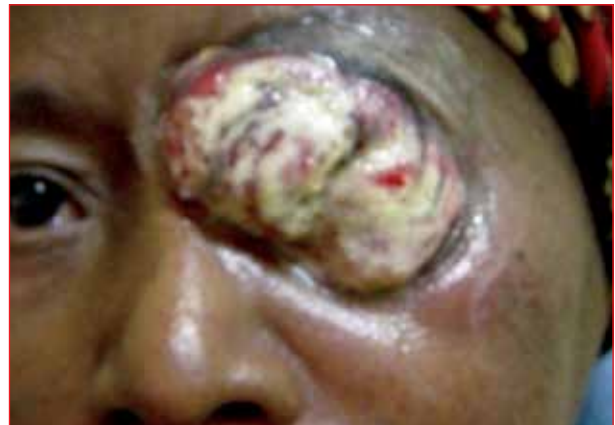

Figure 4 d: Invasive squamous cell carcinoma, with destruction of the globe and infiltration of the orbit

Approach to a patient with a conjunctival growth

When a healthcare worker is consulted by a patient with a conjunctival growth, it can be challenging to make the correct diagnosis.

The following guidelines may contribute to making the correct diagnosis:

- *Listen to the patient:* The patient's history often helps a proper diagnosis to be made, and in turn, direct proper management. Given that significant overlap exists between the reported symptoms for various ocular surface conditions, it is sometimes helpful to ask the patient to identify the most severe symptom that he or she would prefer to be addressed. It may help to identify the most likely primary problem.
- *Conduct a thorough examination of both eyes:* Start with a visual acuity and pinhole test to determine the degree of astigmatism caused by the conjunctival lesion. With inspection, determine the position, colour, level of discomfort and inflammation caused by the lesion, which can help to guide the diagnosis. Investigate corneal sensation to determine whether or not a neurotrophic component is present. Use fluorescein to look for staining on the cornea, but also evaluate the conjunctiva. Fluorescein staining that is more prominent in the superior

cornea, which is typically covered by the upper eyelid, is almost never just due to dry eyes. Staining from dry eyes typically affects the interpalpebral zone much more significantly. Additional investigations should include evert the upper eyelid to check for floppiness and/or changes on the palpebral conjunctiva. Checking for staining of conjunctival growths can provide meaningful clues to the nature and position of the growths.

Useful diagnostic clues and clinical characteristics that pertain to the various conjunctival growths are summarised in Table I.

Conclusion

In a country such as South Africa, with its sunny climate and often extreme summer temperatures, excessive exposure to UVB radiation may have serious health consequences, including problems that affect the eyes. Furthermore, with one of the highest HIV infection rates in the world, and the association of more aggressive SCC of the conjunctiva in HIV-infected persons in Africa,⁹ it is of critical importance for primary level healthcare practitioners to be informed about conjunctival growths, and their differential diagnosis and management. However, it should be strongly emphasised that severe or suspected malignant lesions of the conjunctiva should promptly be referred to an ophthalmologist for

Table I: Differential diagnosis and management of conjunctival growths

Type of lesion	Clinical characteristics	Differentiating properties	Management
Pingueculum	<ul style="list-style-type: none"> Localised, elevated, yellow area on exposed bulbar conjunctiva 	<ul style="list-style-type: none"> Asymptomatic and bilateral Middle-aged patients 	<ul style="list-style-type: none"> Tear supplements Sunglasses to protect against ultraviolet exposure
Pterygium	<ul style="list-style-type: none"> Triangular fibrovascular subepithelial ingrowth of conjunctiva onto the cornea, (more common on the nasal side) 	<ul style="list-style-type: none"> Sun exposure (ultraviolet type B) May cause astigmatism 	<ul style="list-style-type: none"> Tear supplements Sunglasses Surgery, if visual disturbance or symptomatic
Naevus	<ul style="list-style-type: none"> Pigmented lesion, well demarcated and flat Cystic spaces within the naevus Variable degree of pigmentation 	<ul style="list-style-type: none"> Uncommon Presents in first two decades of life Solitary Pigmentation may increase at puberty 	<ul style="list-style-type: none"> Observation Periodic photographic documentation
Pyogenic granuloma	<ul style="list-style-type: none"> Vascularised nodules on conjunctiva Develops within days Bleeds easily on touch 	<ul style="list-style-type: none"> Occurs after conjunctival injury or surgery 	<ul style="list-style-type: none"> Surgical removal Topical antibiotics if infected
Papilloma	<ul style="list-style-type: none"> Pedunculated Finger-like projections Multifocal and/or bilateral 	<ul style="list-style-type: none"> Caused by human papillomavirus Occurs in children and young adults Resolves spontaneously 	<ul style="list-style-type: none"> Excision and cryotherapy at base
Conjunctival intraepithelial neoplasia	<ul style="list-style-type: none"> Unilateral Fleshy gelatinous or white plaque or papillary lesions Located at limbus, may involve adjacent cornea 	<ul style="list-style-type: none"> Older, fair-skinned patients 	<ul style="list-style-type: none"> Complete surgical excision and cryotherapy
Squamous cell carcinoma	<ul style="list-style-type: none"> Local invasive tumour at limbus encroaching onto cornea Papillary or gelatinous Feeder blood vessels 	<ul style="list-style-type: none"> HIV association More aggressive in HIV-positive patients Three months history or more 	<ul style="list-style-type: none"> Surgical excision with supplemental cryotherapy Topical chemotherapy or immunotherapy as adjuvant Aggressive surgery for infiltrating or advanced carcinomas
Malignant melanoma	<ul style="list-style-type: none"> Uncommon tumour Pigmented or amelanotic Elevated nodule on any part of the conjunctiva May invade eyelids or orbit 	<ul style="list-style-type: none"> Feeder vessels <i>De novo</i>, from a naevus or primary acquired melanosis 	<ul style="list-style-type: none"> Excision with cryotherapy and local radiation therapy Exenteration, if orbital involvement Chemotherapy
Lymphoproliferative lesions	<ul style="list-style-type: none"> Smooth, fleshy subconjunctival mass Large area Single or multiple 20% bilateral 	<ul style="list-style-type: none"> Salmon patches 	<ul style="list-style-type: none"> Biopsy Multidisciplinary approach
Kaposi's sarcoma	<ul style="list-style-type: none"> Vascular conjunctival lesion (diffuse or nodular) Resemble subconjunctival haemorrhage 	<ul style="list-style-type: none"> AIDS patients 	<ul style="list-style-type: none"> AIDS treatment Chemotherapy

AIDS: acquired immune deficiency syndrome, HIV: human immunodeficiency virus

evaluation.

Acknowledgements

Dr Daleen Struwig, medical writer, Faculty of Health Sciences, University of the Free State, is acknowledged for the technical and editorial preparation of this manuscript for publication.

References

1. Yanoff M, Fine B. Ocular pathology. 5th ed. Philadelphia: Mosby; 2002.
2. Bechrakis N. Ocular surface squamous neoplasia (OSSN): a review. Cornea [homepage on the Internet]. c2012. Available from: http://journals.lww.com/corneajrnl/Abstract/2003/10000/Ocular_Surface_Squamous_Neoplasia__A_Review.15.aspx
3. Ang LP, Chua JL, Tan TH. Current concepts and techniques in pterygium treatment. *Curr Opin Ophthalmol*. 2007;18(4):308-313.
4. Radhakrishnan A. Ocular surface squamous neoplasia: a brief review. *Kerala Journal of Ophthalmology*. 2011;23:347-351 [homepage on the Internet]. c2012. Available from: http://www.ksos.in/ksosjournal/journalsub/Journal_Article_26_468.pdf
5. Basti S, Macsai MS. Ocular surface squamous neoplasia: a review. *Cornea*. 2003;22(7):687-704.
6. Kanski JJ. *Clinical Ophthalmology. A systematic approach*. 6th ed. Edinburgh: Elsevier; 2008.
7. Rapuano CJ, Heng W. *Cornea. Colour atlas and synopsis of clinical ophthalmology*. Singapore: McGraw-Hill; 2003.
8. Bodunde OT, Ajibode HA, Awodein OG. Destructive eye surgeries in Sagamu. *Nig Med Pract*. 2005;48:47-49.
9. Waddell KM, Lewallen S, Lucas SB, et al. Carcinoma of the conjunctiva and HIV infection in Uganda and Malawi. *Br J Ophthalmol*. 1996;80(6):503-508.