

A wandering spleen: A common presentation of an uncommon anomaly

^aUgwu AC, MSc, PGC-CT ^bOgbonna CO, MSc ^cImo AO, MBBS, FWACS

^aDepartment of Medical Radiography and Radiological Sciences, Faculty of Health Sciences and Technology, Nnamdi Azikiwe University, Nnewi Campus, Anambra State, Nigeria ^bRadiology Department, Federal Medical Centre, PMB 102, Abakaliki, Ebonyi State, Nigeria.

^cRadiology Department, Ebonyi State University Teaching Hospital, Abakaliki, Ebonyi State, Nigeria

Correspondence to: AC Ungwu, e-mail: tonybullng@yahoo.ca

Keywords: wandering spleen; ultrasonography; Nigeria

Abstract

Background: With the advent of real time ultrasonography of the abdomen, the spleen is no longer an inaccessible organ. Wandering spleen is a rare entity with less than 500 cases reported in literature so far.

Method: This case report presents a 16-year-old Nigerian girl who had been admitted to a medical centre. She was referred for ultrasonography on account of a clinical history of lower abdominal tenderness.

Result: The ultrasonography examination revealed that the spleen was not in its normal anatomical position. However, a well-defined acoustic signature of the spleen was seen in the pelvis.

Conclusion: Ultrasonography, which is not as expensive as magnetic resonance imaging (MRI), and computed tomography (CT) is a valuable diagnostic aid in this condition.

Peer reviewed. (Submitted:2009-00-00, Accepted:2009-00-00). © SAAFP

SA Fam Pract 2010;52(1):42-43

Introduction

The spleen develops from the mesoderm in the dorsal mesogastrum. It lies in the left hypochondrium behind the stomach, and is approximately 12 cm long and 7 cm wide.¹ The spleen is fixed in position by the lieno-renal and gastro-splenic ligaments; the phrenico-colic ligament provides additional support. The ligaments are embryological condensations that take place in the peritoneum, and congenital peritoneal anomalies may result in splenic displacement.

Wandering spleen is a rare clinical occurrence with fewer than 500 cases reported in literature. The incidence, based on several large series of splenectomies, is less than 0.5%.² The spleen can be found anywhere in the abdomen or pelvis owing to its long, vascular pedicle. The usual treatment is fixation of the spleen (splenopexy), except in cases of infarction where there is no evidence of blood flow to the spleen after detorsion. In such cases a splenectomy should be considered.³

We present a rare case of wandering (pelvic) spleen showing a normal acoustic signature.

Case report

A 16-year-old Nigerian girl of Ibo origin presented to the gynaecological clinic, with a one-week history of anorexia and lower abdominal tenderness. After a clinical examination, provisional diagnoses of appendicitis and pelvic inflammatory disease (PID) were made.

Haematological and biochemical investigations were normal. An ultrasonography was performed with a 3.5 MHz linear transducer. The spleen was not visualised in its normal position (see Figure 1). However, a well-defined, homogenous mass with vascular channels (see Figure 2) was seen in the pelvic region, anterior to the uterus and a little bias to the left adnexa. A diagnosis of a normal-sized wandering (pelvic) spleen was made.

Discussion

Wandering or ectopic spleen has two possible aetiologies: congenital and acquired. The congenital form occurs due to failure of the dorsal mesogastrum to develop when the lesser sac is formed. The acquired form occurs mostly in multiparous females as the ligaments which are holding the spleen in position become lax.³ Synonyms for wandering

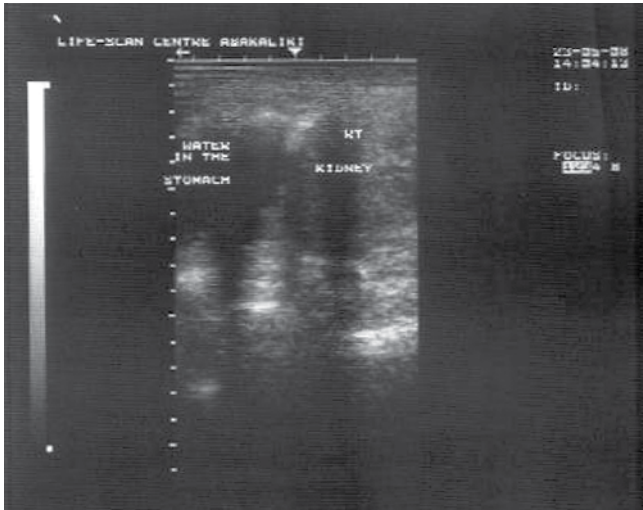


Figure 1: Ultrasound scan of the left upper quadrant of the abdomen showing the right kidney and water in the stomach. The spleen is absent in the splenic bed

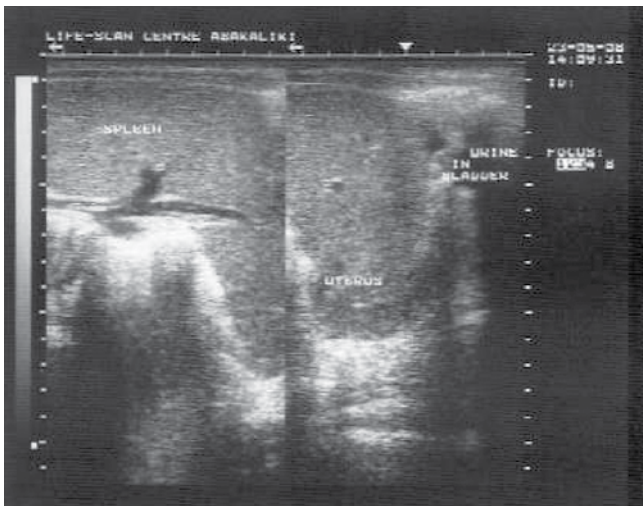


Figure 2: A dual B-mode (ultrasound) display of the abdomen and pelvis showing the spleen, uterus and urine in the urinary bladder

spleen include: displaced spleen, drifting spleen, floating spleen, splenic ptosis, splenoptosis, systopic spleen and pelvic spleen. A review of the English literature from 1960 to 1992 by Dawson and Roberts documented 148 cases, which included both paediatric and adult cases.⁴

Wandering spleen is commonly seen in females in the second decade of life (the patient under review is a female in her second decade of life, that is a 16-year-old female). The clinical presentation of a wandering spleen is variable; patients may be asymptomatic or they may have acute abdominal crises or chronic vague lower abdominal pain.³ The most common presentation in children is an acute surgical abdomen occurring due to infarction from torsion of the splenic pedicle.^{5,6}

The clinical diagnosis of wandering spleen may be quite difficult and the haematological and biochemical investigations may

be nonspecific. Noninvasive imaging procedures such as ultrasonography, scintigraphy, computed tomography (CT) and magnetic resonance imaging (MRI) are usually diagnostic. However, ultrasonography is still considered to be the most reliable for the diagnosis of wandering spleen.⁷ The noninvasiveness of ultrasonography makes it an acceptable modality, especially in children. Doppler sonography helps in the evaluation of organ blood flow.⁸ In the absence of infarction, thrombosis and hypersplenism, in patients presenting with an acute abdomen, detorsion and splenopexy is a recognised surgical option.⁹

Conclusion

In summary, we present a rare occurrence of pelvic spleen on ultrasonography. Awareness of this rare anomaly and the diagnostic utility of ultrasonography may be helpful for guiding both doctors and imaging scientists in the assessment of patients with similar clinical and sonographic presentations.

References

1. Singh I. Essentials of anatomy. New Delhi: Jaypee Brothers Medical Publishers Ltd; 2002, p283.
2. Kinori I, Rifkin MD. A truly wandering spleen. J ultrasound Med. 1988;7:101-5.
3. Alawi MH, Khalifa A, Bana H. Wandering spleen: a challenging diagnosis. Pak J Med Sci 2005;21(4):482-4.
4. Dawson JH, Roberts NG. Management of the wandering spleen. Aust NZJ Surg 1994; 64:441-4.
5. Buchner M, Baker MS. The wandering spleen. Surg Gynecol obstet 1992;175:373-87.
6. Abell I. Wandering spleen with torsion of the pedicle. Ann Surg 1933;98:722-5.
7. Tait NP, Young IR. The wandering spleen: an ultrasonic diagnosis. J Clin ultrasound 1985;13:145-6.
8. Nakamura T, Moriyasu F, Ban N, et al. Quantitative Measurement of abdominal arterial flow using image directed Doppler ultrasonography: superior mesenteric, splenic and common hepatic arterial blood flow in normal adults. J Clin ultrasound 1989;17:261-8.
9. Hirose R, Kitano S, Bando T, et al. Laparoscopic splenopexy for paediatric wandering spleen. J paediatric Surg 1998;33:1571-3

