

What can you learn from rashes? An approach for children.

Mark F Cotton M. Med (Paed), FCPaed (SA), DTM&H, DCH (SA)

Helena Rabie FCPaed (SA), M. Med (Paed)

H Simon Schaaf M. Med (Paed), DCM, MD (Paed)

HJ Jordaan* M. Med (Derm)

Paediatric Infectious Diseases Unit, Dept. Paediatrics & Child Health, Tygerberg Children's Hospital,
*Department of Dermatology

Correspondence to: Stellenbosch University Faculty of Health Sciences, Tygerberg, 7505.

Dr Mark Cotton: , Fax - 021 938 9138, Tel - 021 938 9127

Introduction

Rashes cause a great deal of concern to parents and are often dismissed as either inconsequential or confusing by health care practitioners. While the majority of rashes have trivial consequences, others are manifestations of serious and potentially fatal disease. A careful evaluation of a rash can be extremely rewarding. Serious diseases can be diagnosed with a reasonable degree of certainty and appropriate therapy rapidly instituted. For example, Kawasaki disease often presents with fever and a rash and failure to recognize it in time and give intravenous gammaglobulin will result in coronary artery aneurysms in 20% of patients. In contrast, parents can often be reassured of the benign nature of many rashes. (*SA Fam Pract 2003;45(10): 28-34*)

Specific features of rashes

A good clinical history and physical examination are important for accurate diagnosis. Important points in the history are presented in **table I**. An important and often neglected feature is the tempo of development. For example, the petechiae seen in meningococcaemia develop over minutes to hours, while in papulonecrotic tuberculid (PNT), a form of cutaneous tuberculosis, the lesions develop over weeks.

Important points in physical examination are shown in **table II**. Kawasaki disease is diagnosed by a constellation of physical signs such as maculopapular rash, bulbar conjunctivitis, swollen digits and unilateral cervical adenopathy. Occasionally severe disease such as ecthyma gangrenosum might be missed if the nappy is not removed.

Type of rash (Table III)

There are many types of rashes, including maculopapular, erythrodermal, vesicular or bullous, petechial or purpuric

and erythema nodosum. The majority of rashes are maculopapular. Some rashes may begin as either macular or maculopapular and evolve over time. For example, both meningococcal disease and Henoch-Schönlein purpura may begin as macules/papules that become purpuric over one or two days.

Probably the most serious viral cause of a maculopapular rash is measles. The rash is accompanied by coryza, coughing and conjunctivitis. Koplik's spots are pathognomonic of measles and should always be sought. They are seen on the buccal mucosa a day preceding and two days into the rash. Measles spreads very rapidly and immunocompromised patients are extremely vulnerable. Failure to recognize measles, especially in the hospital environment, and institute post-exposure prophylaxis to unimmunized contacts (vaccine in immunocompetent contact and immunoglobulins in severely immunocompromised) will have serious consequences. Due to successful mass vaccination programs, measles is now rare and may

not be recognized by many clinicians. Also, the maculopapular rash may be harder to identify in patients with dark skin. (**Figure 1A and B**)

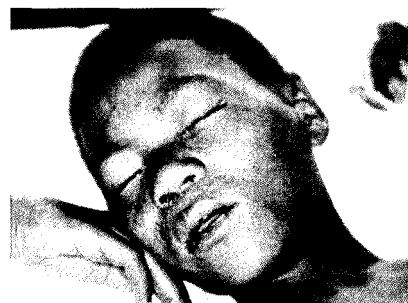

Figure 1. A) 18 year old girl with measles. Note the discharge from eyes and nose.




Figure 1. B) Maculopapular rash on dark skin

Table 1. Questions to consider in a child with a rash

Question	Examples	Possible diagnosis	Characteristic features
How old is the patient?	Neonates First year of life	Congenital cytomegalovirus, rubella or toxoplasmosis (Blueberry muffin syndrome) Erythema toxicum Congenital syphilis Roseola infantum	Discrete, palpable purpuric lesions Maculopapular with yellow centre. Appears within days of birth Vesicular or maculopapular. Involve palms and soles, often desquamating Maculopapular rash occurs at defervescence after 3 to 4 days of high fever
Where did the rash appear first?	Behind the ears, spreading downwards Face first, spreading down	Measles Rubella	Prodrome of 3-4 days: fever, conjunctivitis, coryza, cough and Koplik spots. Rash spreads over 2-3 days. Fever for one day. Occipital lymph nodes palpable. Distinct maculopapular rash
What is the tempo of development?	Minutes to hours Hours to days Days Days to weeks	Meningococcaemia Drug and viral Infective endocarditis Infective endocarditis, collagen-vascular, malignancy, tuberculosis	Maculopapular or petechial rash which may evolve to purpura and/or ecchymosis Usually maculopapular
Any unusual exposure or travel	Water	Schistosomiasis	"Swimmer's itch" – pruritic papular rash within 24 hours of exposure
Contact with animals?	Rodents Livestock	Leptospirosis Brucella	Rare - Maculopapular rash Rare - Maculopapular, erythema nodosum, petechiae, vasculitic lesions
Foodstuffs	Unpasteurised milk or cheese	Listeriosis	Exposure to the mother – maculopapular rash part of neonatal listeriosis
Recent contact with an ill person? (incubation period)	7 days 7 – 10 days	South African tick bite fever Measles Chicken pox, rubella	

Table II. Special features of the rash on examination

Feature	Example	Diagnosis	Comments
Distribution	Hands and feet involved Most prominent on legs Inguinal area	Rickettsial infection Enterovirus Syphilis Henoch-Schönlein purpura Ecthyma gangrenosum due to Pseudomonas aeruginosa	Eschar (often above hairline) Vesicles in posterior oropharynx Palpable purpuric lesions (begin as erythematous papules) Initiate antipseudomonal treatment. The diagnosis may be missed if the doctor does not remove the nappy
Type of rash	Maculopapular Vesicular "Sunburn" like rash	Measles Kawasaki syndrome Rubella Scarlet fever Parvovirus Chickenpox Coxsackie (Hand-foot-&-mouth disease) Toxic epidermal necrolysis Toxic shock syndrome	Cough, coryza, conjunctivitis. Koplik's spots Red eyes, stomatitis, strawberry tongue, swollen hands and feet (digits are warm), cervical lymphadenopathy Usually associated with leukocytosis, raised C-reactive protein and erythrocyte sedimentation rate Occipital lymphadenopathy Intensely erythematous "Slapped cheek" appearance. Rash has "lattice-lime" reticular pattern with central clearing All stages seen at once: papules, vesicles and crusts Mucosal and eye involvement. May be drug-related Patient shocked, multi-organ dysfunction
Red eyes	Discharge present Discharge absent	Adenovirus, measles Kawasaki disease Stevens-Johnson syndrome	Cough prominent in both. Look for Koplik spots on buccal mucosa for measles Look for swollen digits (warm on palpation [as opposed to conditions associated with generalized oedema and where peripheries are cooler]). Mucositis and urethritis may be present. Swollen hands and feet not seen
Strawberry tongue		<i>Streptococcus pyogenes</i> (includes scarlet fever) Kawasaki syndrome Toxic shock syndrome	
Hard & soft palate, buccal mucosa	Palatal petechiae	Epstein-Barr virus, Scarlet fever, Rubella	
Desquamation	Hands - onset at junction of fingertips & nail bed Hands Perineal	Kawasaki disease <i>Streptococcus pyogenes</i> (includes scarlet fever) Toxic shock syndrome Kawasaki disease	
Are the lesions discrete or coalescent?	Discrete	Endocarditis, South African tick-bite fever, Meningococcaemia, Papulonecrotic tuberculid, Histiocytosis, T cell lymphoma Ecthyma gangrenosum	Hepatosplenomegaly may accompany Lesions black – most often due to <i>Pseudomonas aeruginosa</i>

Table III. Differential diagnosis of rash with a fever (adapted from Nelson Textbook of Pediatrics, 14th edition)

Type of rash	Differential diagnosis
Macular or maculopapular	Viral: measles, rubella, roseola infantum, enteroviruses, parvovirus B19 (slapped cheek disease), Epstein-Barr virus (infectious mononucleosis), exanthem subitum (HSV 6), hepatitis B virus, HIV (papular pruritic eruption) Bacterial: Group A beta-haemolytic streptococcus (scarlet fever, rheumatic fever), <i>Neisseria meningitidis</i> (meningococcaemia), <i>Salmonella typhi</i> , <i>Treponema pallidum</i> (secondary syphilis), <i>Mycobacterium tuberculosis</i> (papulonecrotic tuberculosis), Lyme disease, <i>Listeria monocytogenes</i> Rickettsial: <i>Rickettsia conorii</i> (South African tick-bite fever) Other: Kawasaki disease, juvenile chronic arthritis
Diffuse erythroderma (red skin)	Bacterial: Group A streptococcus (scarlet fever), <i>Staphylococcus aureus</i> (scalded skin syndrome), toxic shock syndrome Fungal: <i>Candida albicans</i> (satellite nodules) Other: Drug reactions
Vesicular, bullous, pustular	Viral: Herpes simplex virus type 1 and 2, varicella zoster, coxsackievirus A Bacterial: <i>Staphylococcus aureus</i> (bullous impetigo, scalded skin syndrome), group A streptococcus impetigo, <i>Pseudomonas aeruginosa</i> (folliculitis) Other: Toxic epidermal necrolysis, erythema multiforme (Stevens-Johnson syndrome), Behcet syndrome
Petechial and/or purpuric	Viral: Enterovirus, atypical measles, congenital rubella or cytomegalovirus (CMV), viral haemorrhagic fevers e.g. Congo-Crimean, Ebola, Lassa viruses Bacterial: Meningococcaemia, also sepsis due to other bacteria i.e. Streptococcus, Staphylococcus and other, infective endocarditis Rickettsial: <i>Rickettsia conorii</i> (South African tick-bite fever) Other: thrombocytopenia, vasculitis, Henoch-Schönlein purpura
Urticarial	Viral: Epstein-Barr virus, hepatitis B Bacterial: <i>Mycoplasma pneumoniae</i> , streptococcal infection
Erythema nodosum	Viral: Epstein-Barr virus, hepatitis B Bacterial: <i>M. tuberculosis</i> , group A streptococcus, <i>Yersinia infections</i> , cat-scratch disease Fungal: Histoplasmosis, coccidioidomycosis, blastomycosis Other: Systemic lupus erythematosus, inflammatory bowel disease, sarcoidosis

The other common appearance is vesicular. The most well known vesicular rash is due to varicella (chicken pox). Others include hand-foot-and-mouth disease due to coxsackie A virus and also herpes simplex virus (HSV).

Distribution of rash

This may also give a clue. For example, vesicles in the mouth and on the hands and feet are characteristic of hand-foot-and-mouth disease. The maculopapular rash of enterovirus and rickettsial diseases characteristically involve the palms of the hands and sole of the feet. The purpuric lesions of Henoch Schönlein purpura are classically most prominent on the distal aspects of the lower limbs and lesions above the buttocks are rare.

Varicella zoster occurs more commonly in immunocompromised than immunocompetent children and an underlying cause for immunosuppression should be excluded. It may also disseminate in immunocompromised children. Herpetic lesions caused by HSV also cause disseminated vesicles in immunocompromised children.

Progression

Many rashes have characteristic features and diagnoses can be made with relative certainty. Specific aspects of rashes in children are shown in **table I**. An important and yet often neglected feature of a rash is its natural history. For example, a petechial rash or even isolated petechial spots (macules that do not blanch on pressure), papules or more rarely a maculopapular rash, progressing rapidly with new spots appearing over minutes and hours in a toxic child is almost certainly meningococcaemia (**figure 2**).

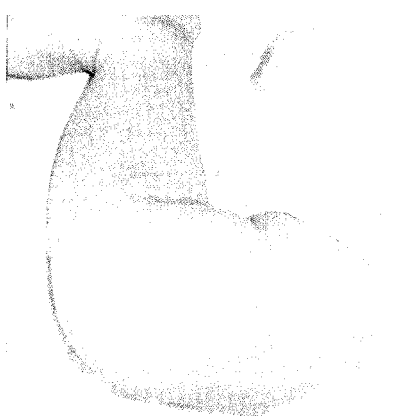


Figure 2 : Meningococcaemia showing small well circumscribed purpuric lesions in 9 month-old infant on legs

Of note is that the characteristic black appearance is not immediately apparent and appears with time. The lesions vary in size and may be only millimetres in diameter. Failure to recognize these features might cause a delay in treatment and might have fatal consequences.

Rashes from most viral illnesses progress over hours to days. For example, in measles, the rash starts behind the ears after a prodrome of three to four days (fever, coryza, conjunctivitis, cough and Koplik spots), gradually progresses to the trunk and limbs over the next two to three days, resolving over the next two to three days in reverse sequence with fading of the rash and desquamation.

In infective endocarditis, development of new lesions may be episodic over days (**figure 3**). Lesions are well circumscribed (**figure 3**). Failure to auscultate the heart in a febrile child may contribute to progressive valve damage, again with fatal consequences. Cutaneous tuberculosis, (papulonecrotic tuberculosis), persist for weeks and may be prominent on the ears (**figure 4**). In juvenile chronic arthritis with systemic onset, a pathognomonic feature is the

presence of a generalized papular eruption *only* during fever.

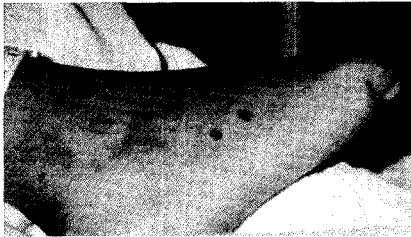

Figure 3: Endocarditis showing focal skin infarcts

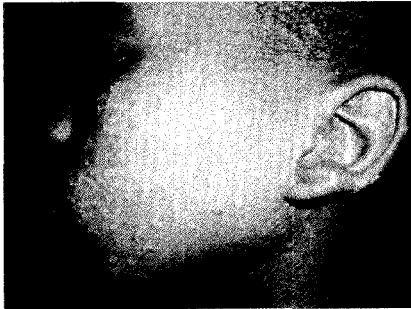

Figure 4: Papulonecrotic tuberculosis

Well circumscribed versus coalescent lesions

One useful distinguishing feature between viral and bacterial (or rickettsial) skin lesions is that that viral rashes often coalesce whereas in bacterial infections, the papules are often very distinct. Exceptions are toxin-mediated skin lesions from toxic shock syndrome (TSS), staphylococcal scalded skin syndrome and scarlet fever, where the skin manifestations are extensive and coalescent (and intensely erythematous in nonpigmented skin). Occasionally, the rash may also be coalescent in severe rickettsial or bacterial infections. On the other hand, the maculopapular rash associated with rubella is not coalescent.

HIV

With the advent of HIV disease, children are presenting with new expressions of dermatological disease. Most conditions are seen in children without HIV infection as well, but are more intense and more extensive in HIV-infected children. Conditions include papular pruritic eruption and severe scabies, often alone or in combination and easy to confuse. Herpetic infections are also more common and more extensive.

Physical signs that assist in establishing the cause of a rash

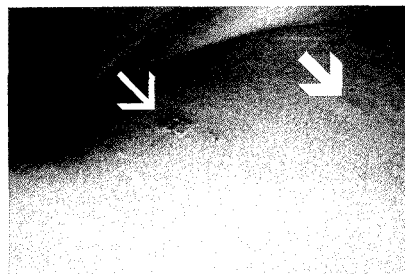
A number of exanthematous diseases in children have distinctive features where failure to make a diagnosis has serious consequences for the child or the community. Examples include Kawasaki disease (KD) and measles. With KD, there is a 20 percent chance of developing coronary aneurysms if correct treatment is not given early in the disease and for measles, failure to identify and prevent spread of the disease will promote the spread in vulnerable infants especially if immunocompromised or under 9 months of age. South African tick-bite fever presents with a maculopapular rash often involving the hands and feet.

Eschar

Tick-bite fever presents with headache, fever and a papular rash a week after the tick bite. Often, the child may have been camping or hiking on the previous weekend. Once the eschar has been located, the diagnosis is obvious and specific therapy can be instituted. The eschar is commonly found above the hairline.

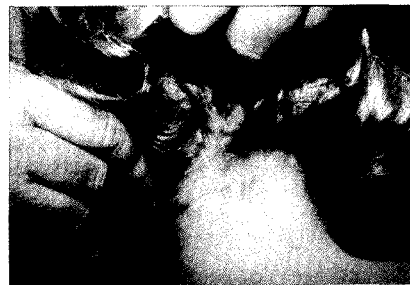

Figure 5: Eschar associated with South African tick bite fever A). above the hairline and B). on the shoulder (also note characteristic well-circumscribed papules – thick arrow)



specification of other sites such as the external auditory canal, axillae and perineum. The eschar may be easily overlooked, especially if the skin is pigmented and a thorough search is not made (**figure 5**). Occasionally, there is no eschar, but this should not prevent the institution of appropriate therapy.

Mouth and lips

A strawberry tongue is seen with infection by group A beta-haemolytic *Streptococcus*, KD and toxic shock syndrome. Initially, if the tongue is coated, with inflamed papillae peeping through, the condition is termed a “white strawberry tongue” and once the coating has disappeared, a “red strawberry tongue” (**figure 6**).

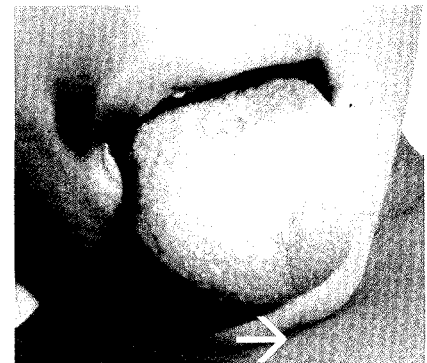

Figure 6: Red strawberry tongue in a patient with scarlet fever– white coating seen centrally. Note also the erythematous rash, less prominent because of the pigmented skin

Other conditions associated with mucositis include KD, often reflected by extremely inflamed lips that then become chapped and Stevens Johnson syndrome (**figure 7**).

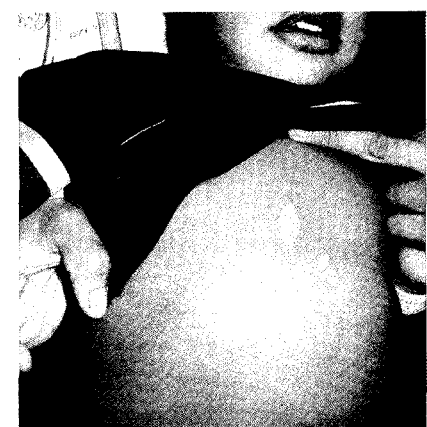

Figure 7: Cheilosis associated with Kawasaki syndrome

If tick bite fever is suspected, and the eschar is not found above the hairline, the clinician should make a careful in-

Koplik's spots in the early phase of measles has already been mentioned. The dermatosis associated with protein energy malnutrition (hyper and hypopigmented areas and "crazy paving" dermatosis) may be associated with angular stomatitis.

Desquamation of skin

Desquamation, especially of the hands is characteristic of a number of conditions, especially where bacterial toxins have been implicated. Conditions include TSS, KS and scarlet fever. The most prominent site for desquamation is on the hands. In KD, especially, the desquamation can be extremely subtle, occurring at the junction of the nail bed and fingertip (figure 8). Occasionally, it may occur in other areas, for example, in the groin (KD) or even on atypical areas such as the knees.

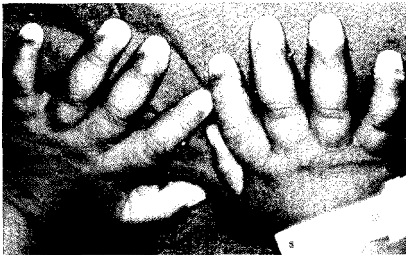

Figure 8: A. Desquamation of skin on fingertips (Kawasaki syndrome). Note the swollen digits also. **B.** Toxic shock syndrome associated with desquamation on hands (typical site) and **C.** knees

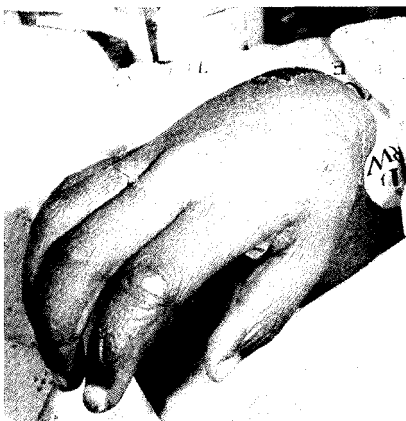

Figure 8: B

"Slapped cheek" appearance

Parvovirus B19 causes a red appearance of the cheeks and is often associated with a reticular "lattice-like" maculopapular rash (figure 9). While trivial in most patients, it can be associated with erythroblastosis foetalis if a pregnant susceptible woman is exposed and is also associated with aplastic crises in children with haemolytic anaemia.



Figure 8: C

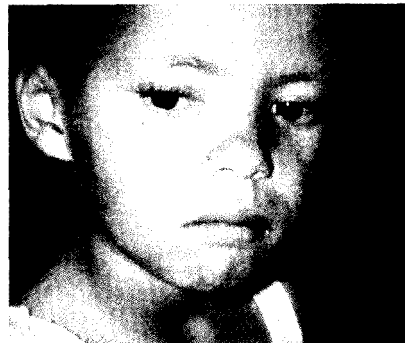

Figure 9: Parvovirus infection is associated with A (above) a "slapped cheek" appearance and B (below) reticular "lace-like" rash



The nappy area

Nappy rashes occur commonly and are usually well managed. The satellite lesions associated with candida infection are well known and easily managed. Rarely, in immune compromised infants ecthyma gangrenosum, an aggressive

vasculitic disease caused by *Pseudomonas aeruginosa*, occurs in the inguinal area. This condition requires early recognition and specific antipseudomonal treatment. Failure to examine the nappy area in a critically ill patient will result in serious consequences (figure 10).

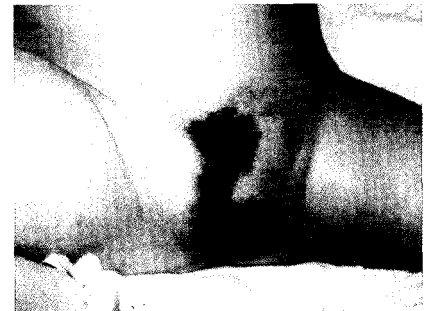

Figure 10: Erythema gangrenosum due to *Pseudomonas aeruginosa* in an infant with acute lymphoblastic leukaemia

Lymphadenopathy, hepatomegaly and splenomegaly

Infectious mononucleosis (Ebstein Barr virus) presents with a combination of lymphadenopathy, hepatosplenomegaly, palatal petechiae and a maculopapular rash. The rash is usually elicited or accentuated by ampicillin.

HIV causes multisystem disease and is commonly associated with lymphadenopathy and hepatosplenomegaly. Because of progressive immune dysregulation, intercurrent pathological infectious and non-infectious processes may be more severe. For example, varicella is more severe. Scabies is also more severe and is also commonly confused with papular pruritic eruption of HIV. Healing is associated with pigmentation, leading to extensive hyperpigmented macules with widespread distribution. Papular urticaria may be related to or confused with insect bites (figure 11). Psoriasis may be seen in children with HIV, with skin lesions being confused as non-resolving fungal infections. Clues to psoriasis may be the presence of arthropathy and pitting of the nails.

Vesicular rashes

Chickenpox usually does not present diagnostic problems. The lesions begin as macules and rapidly progress to ves-

icles and crusts. All stages of the lesions are present at any one time. Usually less than 500 lesions occur over the course of 2 to 3 days but occasionally the eruption may be worse (**figure 12**).

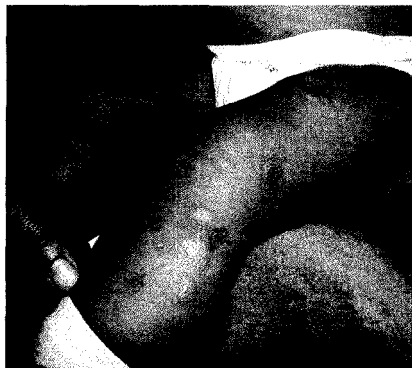

Figure 11: Papular lesions possibly associated with fleabites in a HIV-infected infant on cotrimoxazole prophylaxis for 6 months. Note the linearity of the lesions and also older lesion (thick arrow)

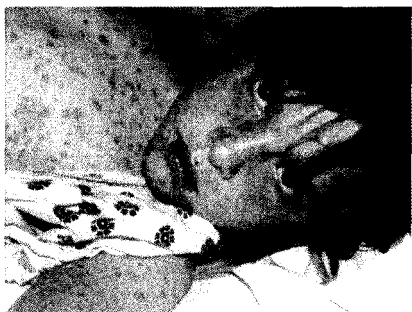

Figure 12: A. Severe chicken pox in a 10 year old girl.

Stevens-Johnson syndrome and toxic epidermal necrolysis is associated with a rash, usually described as “target lesions”. Although lesions may initially appear papular they may rapidly become bullous and after rupture or resorption of fluid, may appear vasculitic (**figure 13**).

Non-infectious causes of skin rashes

Drug reactions

Any drug, some more often than others, such as antibiotics (penicillin derivatives, sulfonamides), antitubercotics (isoniazid, fluoroquinolones) and anti-convulsants (barbiturates, carbamazepine), may be associated with a rash. A history of drug exposure is extremely important. The type of rash varies but is most commonly maculopapular and is often itchy. With some medications, skin rash is a common side

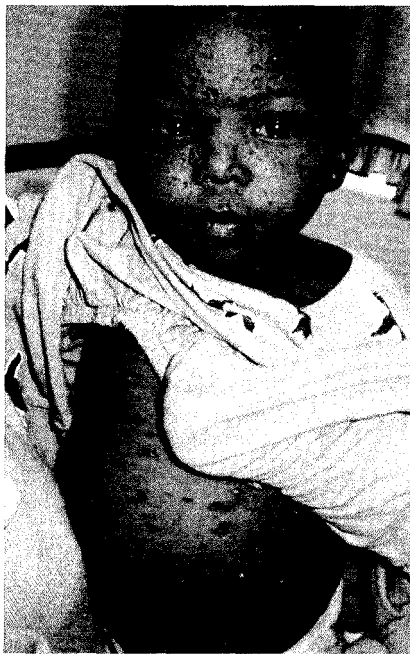

Figure 12: B. Severe chicken pox in a HIV-infected infant. Note the different stages of lesions

effect. For example, it is often seen within the first 6 weeks of using nevirapine (NVP), a non-nucleoside reverse transcriptase inhibitor for HIV infection. Although this drug is used in combination with two nucleoside reverse transcriptase inhibitors, the rash is so characteristic for NVP, that it, alone, can be substituted if the rash is severe, progressive, associated with mucosal changes or raised liver enzymes. A NVP-associated rash is shown in **figure 14**.

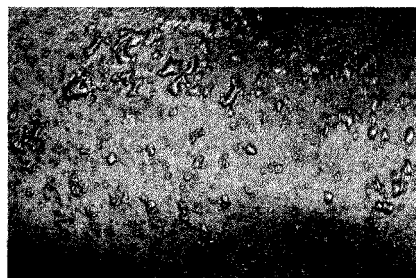


Figure 13: Toxic epidermal necrolysis. Fluid-filled blisters and lesions after reabsorption of fluid.

Collagen vascular disease

Collagen vascular diseases often have skin manifestations. Probably the best known of these is the butterfly rash or small vessel vasculitis associated with systemic lupus erythematosus (SLE) and discoid lupus. The maculopapular eruption seen in systemic onset of juve-

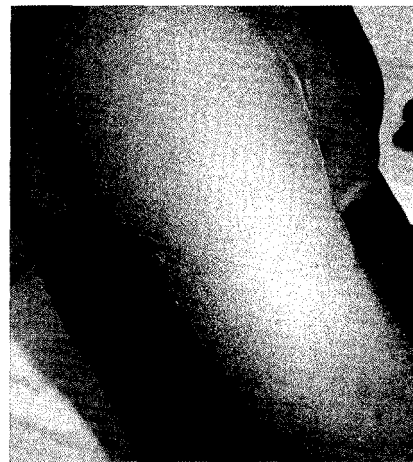

Figure 14: Nevirapine-associated rash

nile chronic arthritis has already been mentioned and should be carefully sought when the patient is febrile. Because juvenile chronic arthritis is often associated with prolonged fever, expensive investigations are undertaken to find a source. By observing the rash, much expense and anxiety can be avoided.□

Recommended Reading

1. Mandell, Douglas and Bennett's Principles and Practice of Infectious Diseases 5th ed 2000, Churchill Livingstone, Philadelphia, PE, USA
2. American Academy of Pediatrics. Pickering LK ed. 2000 Red Book: Report of the Committee of Infectious Diseases, 25th ed. Elk Grove Village, IL.: American